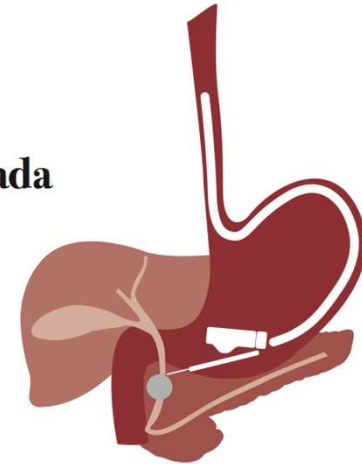


**Especialización en
Ultrasonografía
Endoscópica Avanzada**

Título Propio



FUTURO DE LA ECOENDOSCOPIA

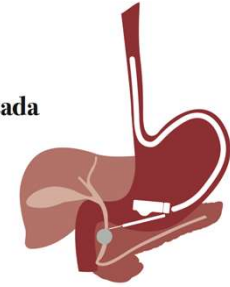
Angels Ginès
Hospital Clínic. Barcelona

Enrique Vázquez Sequeiros
Hospital Ramón y Cajal. Madrid.

FUTURO DE LA ECOENDOSCOPIA

Especialización en
Ultrasonografía
Endoscópica Avanzada

Título Propio
 Universidad
de Alcalá



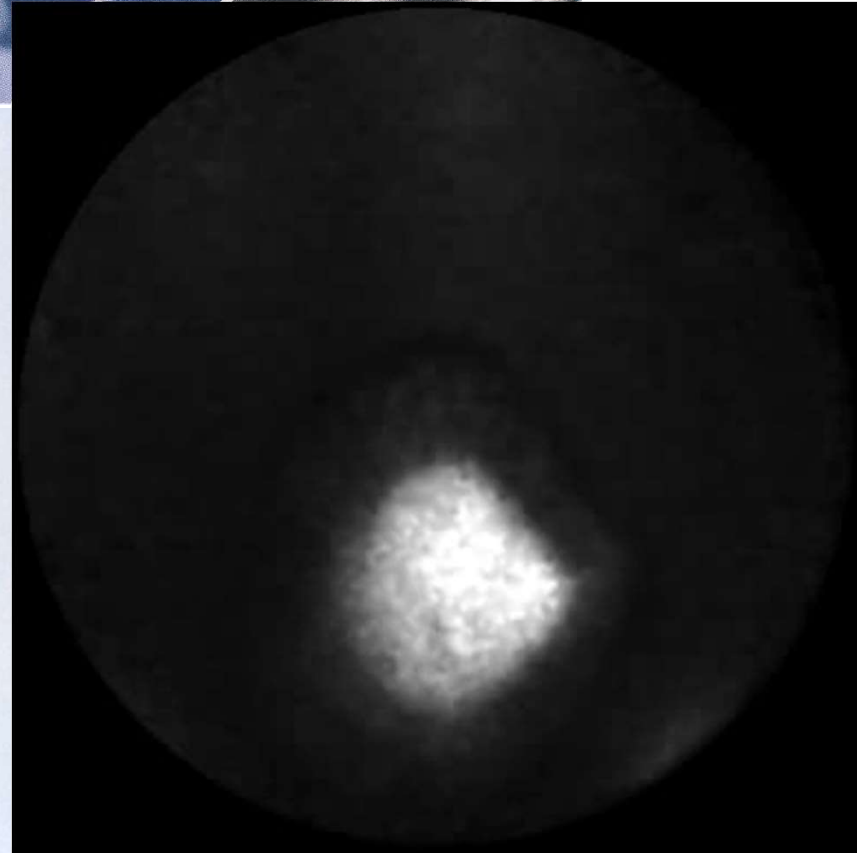
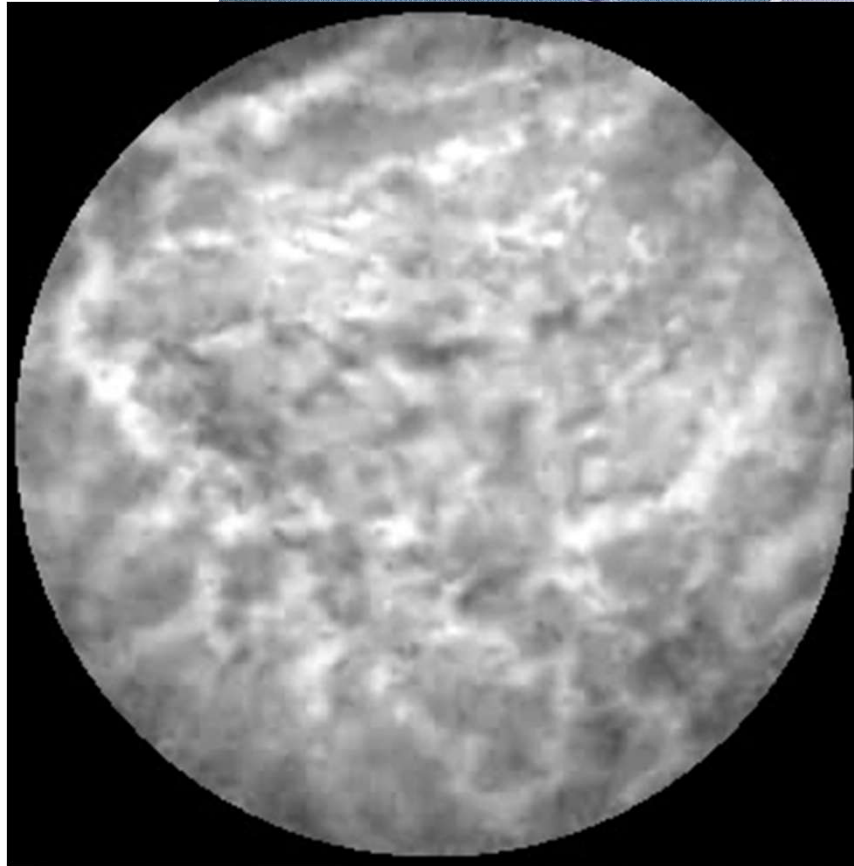
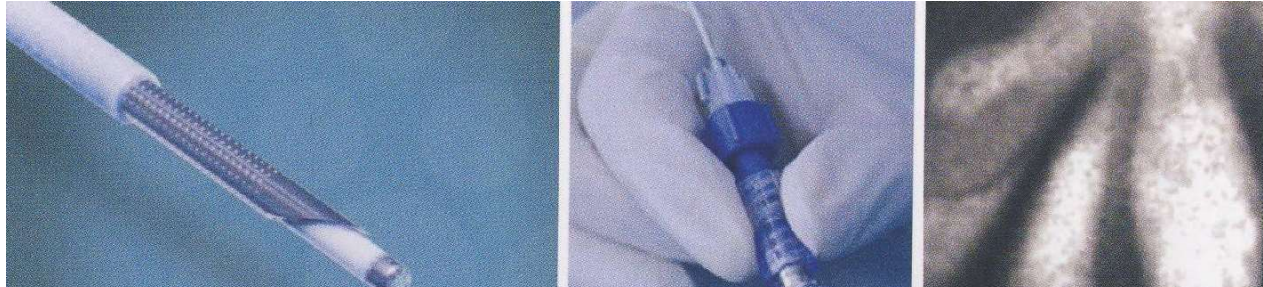DIAGNÓSTICO POR IMAGEN

¿Habrá aún un lugar para la **USE diagnóstica sin PAAF?**

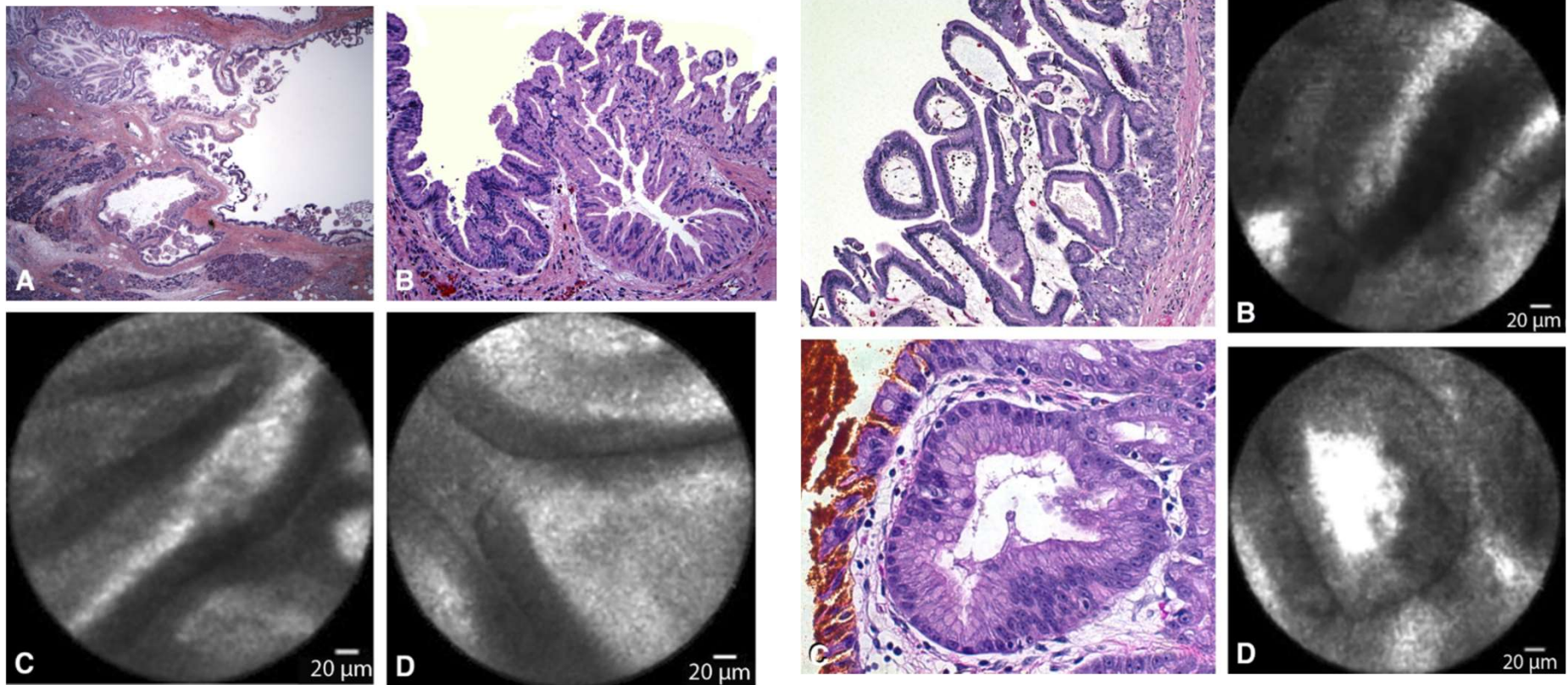
- Tumores subepitelial y compresión extrínseca
 - diagnóstico
 - previa a tto endoscópico si se plantea
- Sospecha de linitis gástrica
- Diagnóstico de patología pancreática / ampular

No grandes ventajas respecto a técnicas radiológicas

MICROSCOPIA CONFOCAL GUIADA POR USE PARA EL ESTUDIO DE LESIONES QUÍSTICAS DEL PÁNCREAS



MICROSCOPIA CONFOCAL GUIADA POR USE PARA EL ESTUDIO DE LESIONES QUÍSTICAS DEL PÁNCREAS



Inyección de 2,5 ml de fluoresceína al 10%

¿ELASTOGRAFIA?

Diagnóstico de pancreatitis crónica en fase precoz?

(Kawada N et al WJG 2016)



Difícil entender que técnica basada en la detección de dureza / elasticidad de los tejidos pueda detectar la enfermedad en fase de fibrosis incipiente.

- * Limitaciones: observador-dependiente
variabilidad (grado de presión)
- * **CITOLOGÍA IMPRESCINDIBLE en Oncología y para descartar malignidad**
- * Papel en la elección de la zona para PAAF (páncreas, ADP)

¿CONTRASTE?

- **Mejor zona para PAAF**

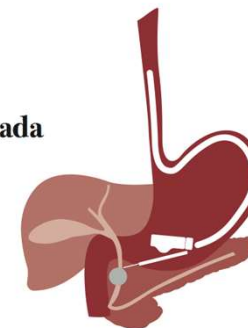- **Tratamiento *a la carta***

- Anticuerpos, péptidos etc adheridos a las microesferas para detectar zonas de inflamación, angiogénesis o cáncer o monitorizar la respuesta terapéutica.
- Sustancias biactivas (genes, fármacos, proteínas) adheridas a las microesferas para ser liberadas en la zona a tratar.

FUTURO DE LA ECOENDOSCOPIA

Especialización en
Ultrasonografía
Endoscópica Avanzada

Título Propio



DIAGNÓSTICO POR USE-PAAF

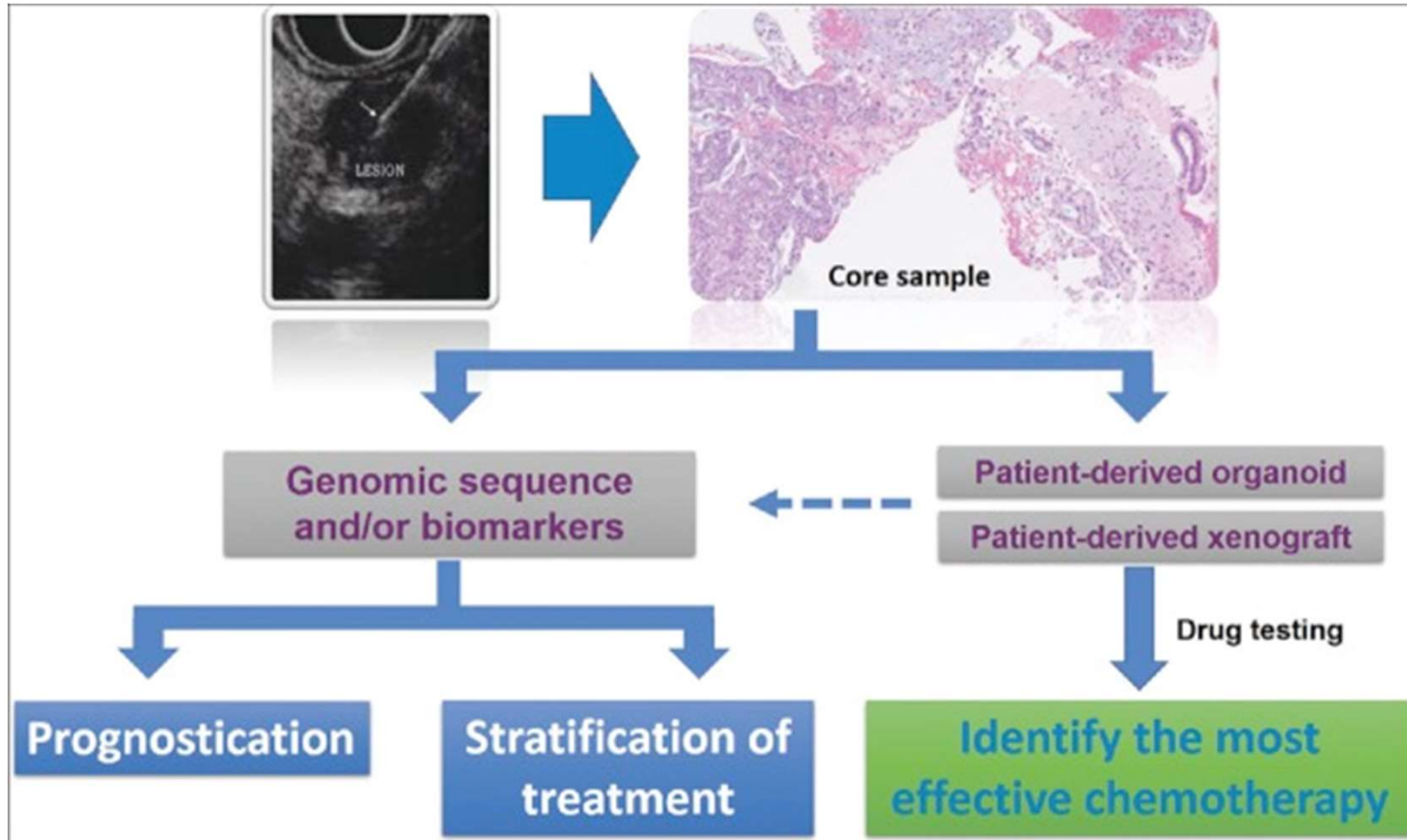
1) Diagnóstico cito-histológico

* importancia en lesiones irresecables o cuando está indicada la neoadyuvancia

2) DETERMINACIONES MOLECULARES a partir del material obtenido por USE-PAAF

- Diagnóstico diferencial (mutaciones GNAs i Kras en NMPI)
- Detección de micrometástasis por técnicas moleculares
- Determinación de biomarcadores que permiten un diagnóstico y tratamiento mucho más específicos (determinación cKit y tratamiento con Imatinib en GIST)
Medicina a la carta
- Apoyo a diagnóstico de malignidad (mutaciones K-ras)

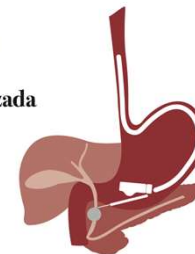
MEDICINA A LA CARTA



FUTURO DE LA ECOENDOSCOPIA

Especialización en
Ultrasonografía
Endoscópica Avanzada

Título Propio
 Universidad
de Alcalá



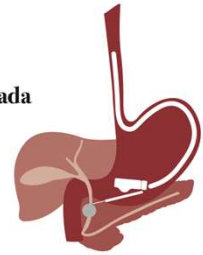USE TERAPÉUTICA

FUTURO DE LA ECOENDOSCOPIA

Especialización en
Ultrasonografía
Endoscópica Avanzada

Título Propio

 Universidad
de Alcalá



- Neurolisis o bloqueo del plexo celíaco
- Drenaje de pseudoquistes, colecciones y necrosectomía
- Técnicas de rendez-vous
- Drenaje vía biliar o Wirsung guiado por USE
- Anastomosis digestiva
- Ablación por inyección o radiofrecuencia
- Braquiterapia intratumoral
- Radioterapia estereotáctica
- Intervencionismo vascular

ABLACIÓN LESIONES CON INYECCIÓN GUIADA POR USE

Table 10 Endoscopic ultrasound-guided ethanol injection of abdominal solid and cystic tumors

Ref.	Design	Indications	Lesion size (mm)	Techniques	Clinical success	Complications
Gan <i>et al</i> ^[187]	PS	Pancreatic cystic lesions (n = 25)	6-30	Ethanol	35%	None
Oh <i>et al</i> ^[185]	PS	Pancreatic cystic lesions (n = 14)	17-52	Ethanol and paclitaxel	79%	1 acute pancreatitis 6 hyperamylasemia 1 abdominal pain
Oh <i>et al</i> ^[182]	PS	Septated pancreas cysts (n = 10)	20-68	Ethanol and paclitaxel	60%	1 acute pancreatitis
DeWitt <i>et al</i> ^[183]	RCT	Pancreatic cystic lesions (n = 42)	10-58	Ethanol vs saline	33%	1 acute pancreatitis 5 abdominal pain 1 cystic bleeding
DeWitt <i>et al</i> ^[184]	PS	Pancreatic cystic lesions (n = 12)	10-50	Ethanol	75% at follow-up	-
Oh <i>et al</i> ^[186]	PS	Pancreatic cystic lesions (n = 52)	17-68	Ethanol and paclitaxel	62%	1 acute pancreatitis 1 abdominal pain 1 fever 1 splenic vein thrombosis
DiMaio <i>et al</i> ^[189]	RS	Pancreatic cystic lesions (n = 13)	20.1 ± 7.1	Ethanol (single/ multi)	38%	1 abdominal pain
Oh <i>et al</i> ^[190]	RS	Pancreatic cystic lesions (n = 1)	5.2	Ethanol 99% 28 mL + paclitaxel	Failure, underwent surgery	Portal vein thrombosis
Jurgensen <i>et al</i> ^[192]	RS	Pancreatic NET (n = 1)	13	Ethanol 95% 8 mL	Complete remission	Pain + lipase increase
Muscatiello <i>et al</i> ^[193]	RS	Pancreatic NET (n = 1)	11 and 7	Ethanol 40% 2 mL	No recurrence at 18 mo	Small pancreatic necrosis
Deprez <i>et al</i> ^[194]	RS	Pancreatic NET (n = 1)	13	Ethanol 98% 3.5 mL	Complete remission	Hematoma and duodenal ulcer
Vleggaar <i>et al</i> ^[195]	RS	Pancreatic NET (n = 1)	10	Ethanol 96% 0.3 mL	Asymptomatic at 6 mo	None
Levy <i>et al</i> ^[191]	RS	Pancreatic NET (n = 5)	8-21	Ethanol 95-99% 0.1-3 mL	60% symptoms resolution	None
Barclay <i>et al</i> ^[196]	RS	Solid Hepatic Metastasis (n = 1)	33	Ethanol 98% 6 mL	Good condition at 5.5 yr	Liver hematoma
Gunter <i>et al</i> ^[197]	RS	GI stromal tumor (n = 1)	40	Ethanol 95% 1.5 mL	Complete remission	Abdominal pain Mucosal ulceration
Hu <i>et al</i> ^[198]	RS	Liver metastasis (n = 1)	35	Ethanol 100% 10 mL	Local control and decrease in size	Fever
Artifon <i>et al</i> ^[199]	RS	Left adrenal metastasis (n = 1)	50	Ethanol 98% 15 mL	Palliation of related pain	None
DeWitt <i>et al</i> ^[200]	RS	Metastatic lymph node (n = 1)	10-11	Ethanol 4 + 2 mL	Locally successful	None
Total (cystic lesion) 8 studies		169 patients	6-68	-	60% (33%-79%)	-

(Fabbri et al WJG 2014)

ABLACIÓN LESIONES QUÍSTICAS CON INYECCIÓN DE ALCOHOL GUIADA POR ULTRASONIDO

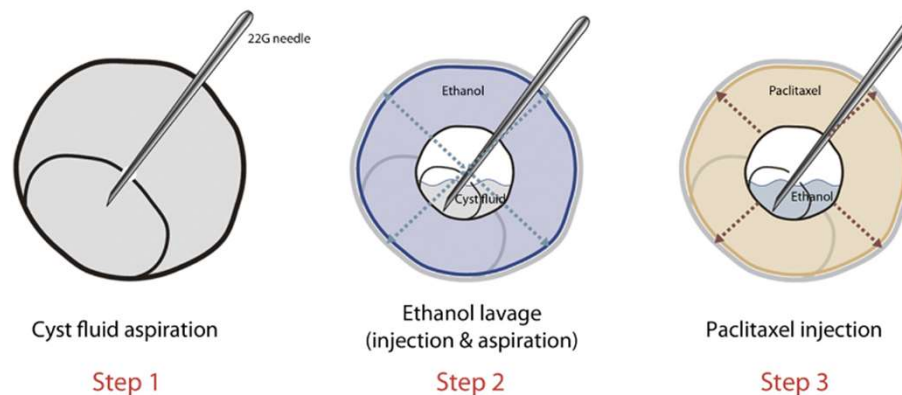


Figure 1. Stepwise EUS-guided pancreatic cyst ablation therapy. Step 1: FNA (*left*) within a septated cyst (*heavy black line*). Step 2: 5-minute ethanol (*middle*) lavage of the cyst, followed by aspiration of the ethanol. Step 3: injection of paclitaxel (*right*) into the cyst, resulting in expansion of the cyst to its original diameter.

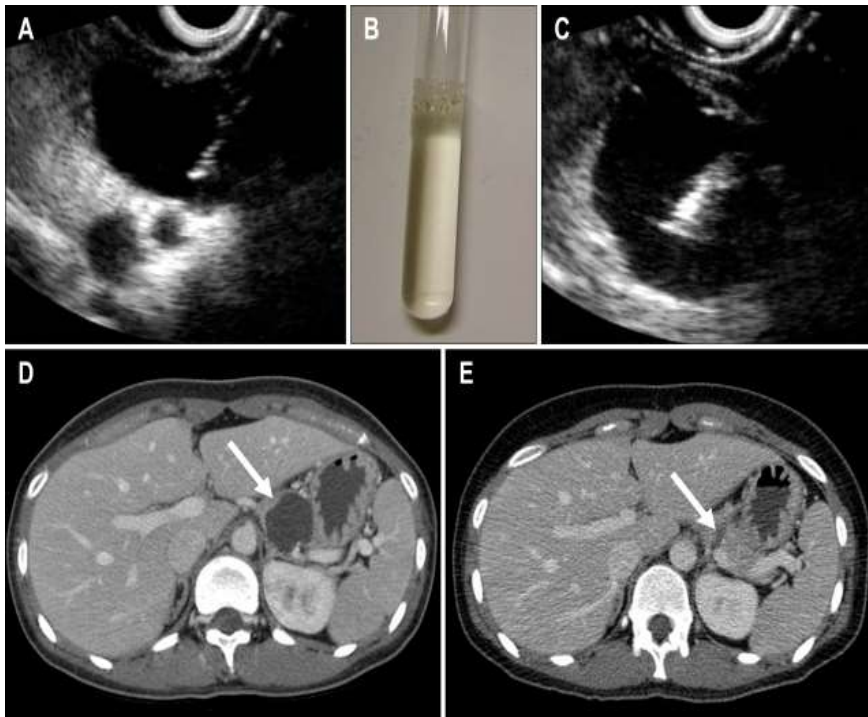
Table 1. Summary of previous reports of EUS-guided cyst ablations

Authors	No. of patients	Ablative agent	Follow-up period	Complete resolution
Gan et al ³⁴	25	5%-80% ethanol	6-12 mo	35% (8/23)
Oh et al ²⁷	14	80%/99% ethanol with paclitaxel	Median 9 mo (range 6-23 mo)	79% (11/14)
Oh et al ^{37*}	10	99% ethanol with paclitaxel	Median 8.5 mo (range 6-18 mo)	60% (6/10)
DeWitt et al ³⁶	42	80% ethanol	3-4 mo after second lavage	33% (12/36)
Oh et al ^{6†}	47	99% ethanol with paclitaxel	Median 20 mo (range 12-44)	62% (29/27)
DiMaio et al ^{35‡}	13	80% ethanol	13 mo after first lavage	38% (5/13)

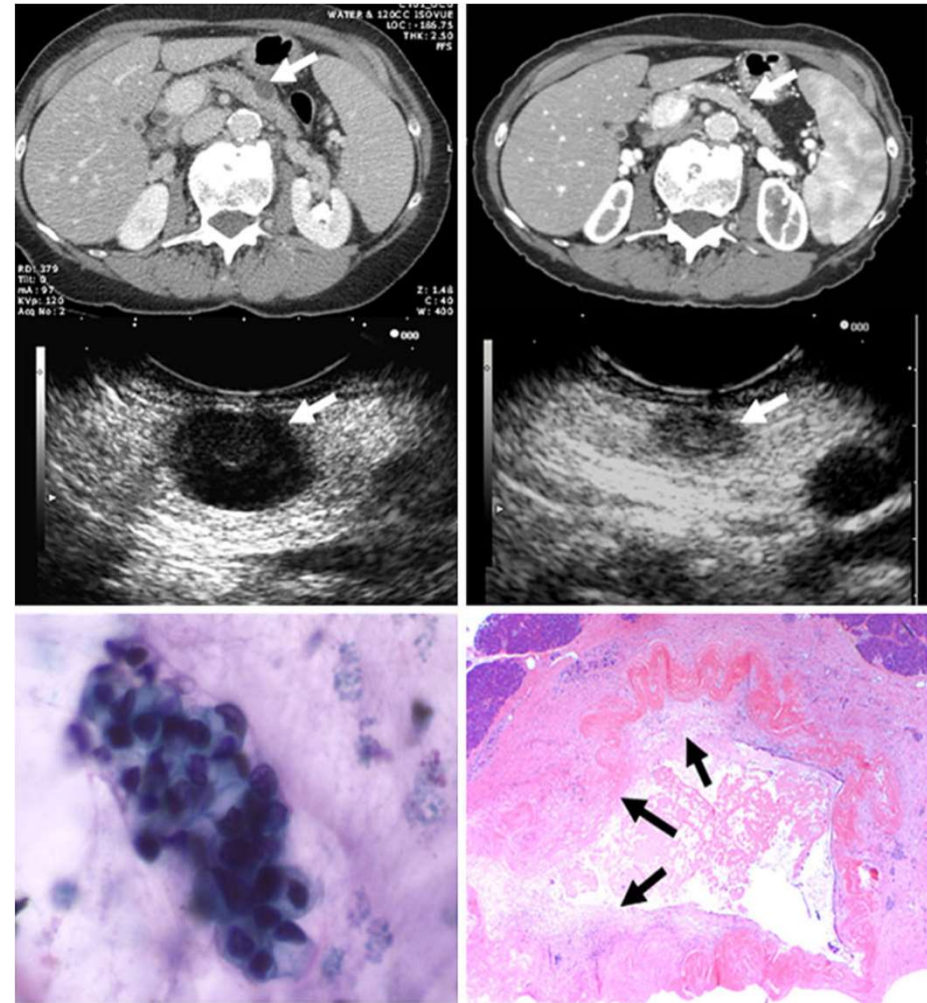
*Included only patients with a septated cyst.
 †Included study population of 2 preliminary reports.^{29,30}
 ‡Included patients with multiple ablations.

ABLACIÓN LESIONES QUÍSTICAS CON INYECCIÓN DE ALCOHOL GUIADA POR USE

Técnica



Seo DW Gut and Liver 2010)



(DeWitt et al, GIE 2009)

ABLACIÓN LESIONES QUÍSTICAS CON INYECCIÓN DE ALCOHOL GUIADA POR USE

Table 2. Cyst ablation–related adverse events

	Gan et al ³⁴ (N = 25)	DeWitt et al ³⁶ (N = 75)	Oh et al ⁶ (N = 52)	Overall (N = 152)*
Adverse events, n* (%)				
Abdominal pain	0	11	1	12 (7.9)
Acute pancreatitis	0	2	1	3 (2.0)
Fever	0	0	1	1 (0.7)
Pericystic spillage	0	0	1	1 (0.7)
Splenic vein obliteration	0	0	1	1 (0.7)

*Total number of patients who underwent 1 session of EUS-guided cyst ablation.

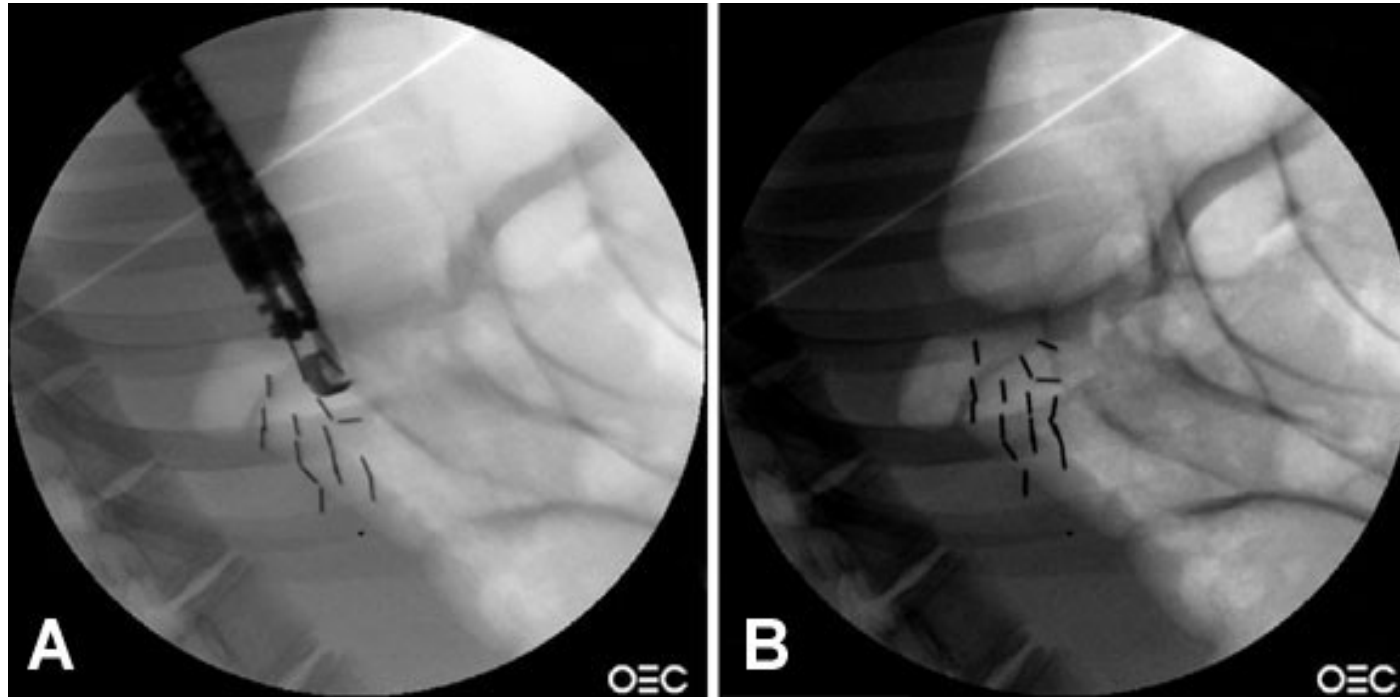
ABLACIÓN LESIONES CON INYECCIÓN GUIADA POR USE

Table 11 Endoscopic ultrasound-guided tumor ablation

Ref.	Design	Indications	Techniques	Type	Tumor response	Complications
Chang <i>et al</i> ^[202]	PS	Pancreatic cancer (n = 8)	Injection	Cytoimplant	2 partial; 1 minor	None
Hecht <i>et al</i> ^[203]	PS	Pancreatic cancer (n = 21)	Injection	ONYX-015 + <i>iv</i> gemcitabine	2 partial; 2 minor; 6 stable; 11 progression	2 sepsis 2 duodenal perforations
Chang <i>et al</i> ^[211]	RS	Pancreatic cancer (n = 1)	Injection	TNferade + chemoradiotx	Surgical resection	None
Hecht <i>et al</i> ^[205]	PS	Pancreatic cancer (n = 50)	Injection (27 EUS-guided)	TNferade + chemoradiotx	1 complete; 3 partial; 4 minor; 12 stable	6 GI bleeding 6 deep vein thrombosis 2 pulmonary embolism 2 pancreatitis 6 cholangitis
Irisawa <i>et al</i> ^[204]	PS	Pancreatic cancer (n = 7)	Injection	Immature dendritic cells	2 mixed; 2 stable; 3 progressive	None
Hanna <i>et al</i> ^[207]	PS	Pancreatic cancer (n = 9)	Injection (6 EUS-guided)	BC-819 + chemoradiotx	2 surgically resectable; 3 partial	None
Chang <i>et al</i> ^[206]	PS	Esophageal cancer (n = 24)	Injection	TNferade	6 complete; 2 stable	5 thromboembolic events (highest dose)
Arcidiacono ^[208]	PS	Pancreatic cancer (n = 22)	Cryothermal Ablation	EUS-CTP	6 partial response (only 6 patients analyzed)	3 hyperamylasemia
Maier <i>et al</i> ^[212]	PS	Head/neck cancer (n = 21)	Brachytx	Ir-192 needles	4 full; 15 partial; 3 none	None
Lah <i>et al</i> ^[213]	RS	Metastatic celiac lymph nodes (n = 1)	Brachytx	I-125 seeds	Response	None
Martinez-Monge <i>et al</i> ^[214]	RS	Metastatic mediastinal lymph node (n = 1)	Brachytx	I-125 seeds	Response	None
Sun <i>et al</i> ^[209]	PS	Pancreatic cancer (n = 15)	Brachytx	I-125 seeds	4 partial; 3 minor; 5 stable; 3 progressive	1 site infection 3 hematologic side effects
Jin <i>et al</i> ^[210]	PS	Pancreatic cancer (n = 22)	Brachytx	I-125 seeds	4 partial; 10 stable	1 seed migration

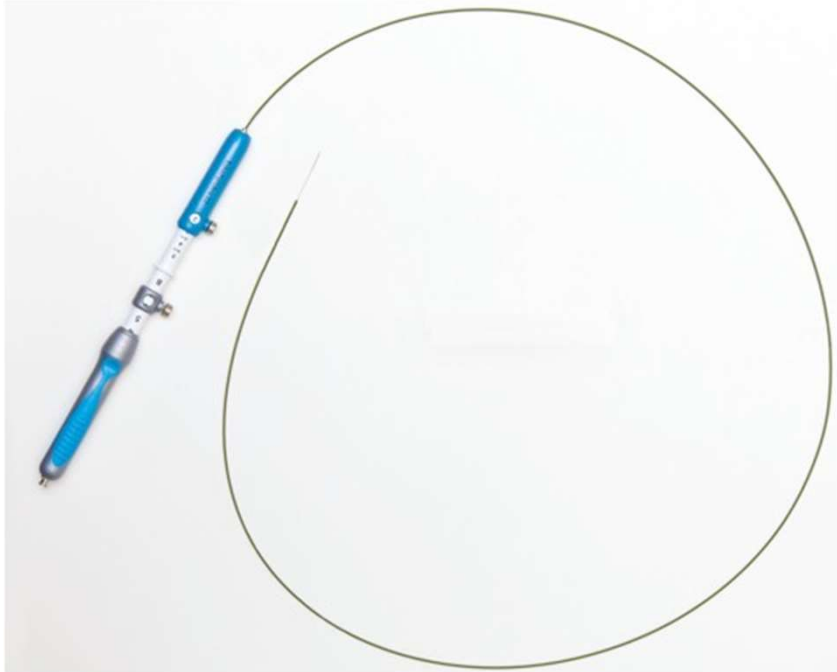
(Fabbri et al WJG 2014)

BRAQUITERAPIA INTRATUMORAL GUIADA POR USE

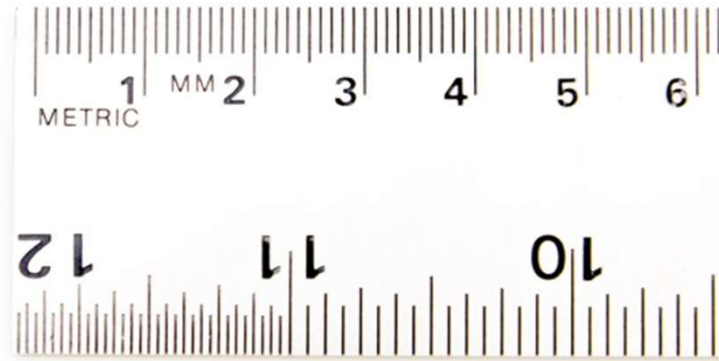


(Wallace MB. Gastrointest Endosc 2000)

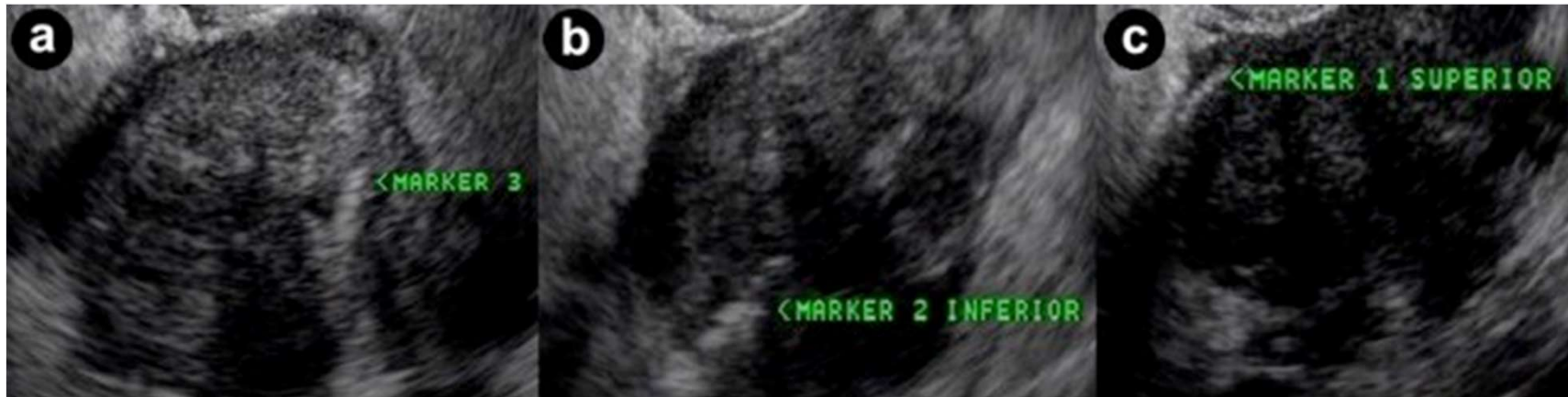Fiducials para radioterapia esterotáctica



B. 
A. 



Visicoil™ Fiducial Markers
A. 10x0.75mm Marker
B. 10x0.35mm Marker



COLOCACIÓN GUIADA POR USE DE FIDUCIALS PARA RADIOTERAPIA ESTEREOTÁCTICA

Table 12 Endoscopic ultrasound-guided fiducial placement *n* (%)

Ref.	Design	Indications	Techniques	Technical success	Needle	Complications
Pishvaian <i>et al</i> ^[215]	PS	Abdominal/mediastinal cancer (<i>n</i> = 13)	Fiducial placement	11/13 (84.6)	19 Gauge	1 infection
Varadarajulu <i>et al</i> ^[222]	RS	Pancreatic cancer (<i>n</i> = 9)	Fiducial placement	9/9 (100)	NR	None
DiMaio <i>et al</i> ^[223]	RS	Abdominal/mediastinal cancer (<i>n</i> = 30)	Fiducial placement	29/30 (97)	22 Gauge	None
Sanders <i>et al</i> ^[217]	PS	Pancreatic cancer (<i>n</i> = 51)	Fiducial placement	46/51 (90)	19 Gauge	1 mild pancreatitis
Park <i>et al</i> ^[216]	PS	Pancreatic cancer (<i>n</i> = 57)	Fiducial placement	50/57 (88)	19 Gauge	None
Ammar <i>et al</i> ^[224]	RS	Abdominal cancer/lymph nodes (<i>n</i> = 13)	Single fiducial marker	9/9 trans-gastric 4/4 trans-duodenal	22 Gauge	None
Varadarajulu <i>et al</i> ^[225]	PS	Pancreatic cancer (<i>n</i> = 2)	Fiducial placement	2/2 (100)	19 Gauge flexible	None
Khashab <i>et al</i> ^[218]	RS	Pancreatic cancer (<i>n</i> = 39)	Fiducial placement (traditional vs coiled)	39/39 (100)	19 and 22 Gauge	None
Law <i>et al</i> ^[226]	RS	Small pancreatic NET (<i>n</i> = 2)	Fiducial placement	2/2 (100)	22 Gauge	None
Majumder <i>et al</i> ^[219]	RS	Pancreatic cancer (<i>n</i> = 39)	Fiducial placement	35/39 (89.7)	19 Gauge	1 mild pancreatitis 4 abdominal pain
Yang <i>et al</i> ^[220]	RS	Prostate cancer (<i>n</i> = 16)	Fiducial placement	16/16 (100)	19 Gauge	None
Yang <i>et al</i> ^[221]	RS	Prostate cancer recurrence (<i>n</i> = 6)	Fiducial placement	6/6 (100)	19 Gauge	None
Trevino <i>et al</i> ^[227]	RS	Rectal cancer (<i>n</i> = 1)	Fiducial placement	3/3 (100)	19 Gauge (forward-view EUS)	None
Total	13 studies	278	-	100% (84.6%-100%)	-	0%

(Fabbri *et al* WJG 2014)

TERAPIA VASCULAR GUIADA POR USE

Table 13 Endoscopic ultrasound-guided vascular Interventions *n* (%)

Ref.	Design	Indications	Techniques	Technical success	Rebleeding	Complications
Fockens <i>et al</i> ^[229]	RS	Dieulafoy's lesion (<i>n</i> = 4)	Polidocanol injection	4/4 (100)	2/4 (50)	None
Levy <i>et al</i> ^[234]	RS	Dieulafoy's lesion (<i>n</i> = 1)	Alcohol 99% injection	1/1 (100)	No	None
Gonzalez <i>et al</i> ^[235]	RS	Dieulafoy's lesion (<i>n</i> = 2)	Polidocanol or CYA injection	2/2 (100)	No	None
Levy <i>et al</i> ^[234]	RS	Various (<i>n</i> = 4)	Alcohol 99% or CYA injection	4/4 (100)	No	None
Gonzalez <i>et al</i> ^[235]	RS	Pseudo-aneurysm (<i>n</i> = 3)	CYA injection	3/3 (100)	No	None
Gonzalez <i>et al</i> ^[235]	RS	Gastric varices (<i>n</i> = 2)	CYA injection	2/2 (100)	No	None
Lee <i>et al</i> ^[231]	RS	Gastric varices (<i>n</i> = 101)	EUS-assisted CYA injection	-	Early 4/54 (7.4) Late 10/54 (18)	None
Lahoti <i>et al</i> ^[236]	RS	Esophageal varices (<i>n</i> = 5)	Sclerotherapy	5/5 (100)	No	1 esophageal stricture
Romero-Castro <i>et al</i> ^[237]	RS	Gastric varices (<i>n</i> = 5)	CYA injection	5/5 (100)	No	None
De Paulo <i>et al</i> ^[230]	RCT	Esophageal varices (<i>n</i> = 50)	Endo vs EUS-guided CYA injection	24/25 (96)	2/24 recurrence of varices (8.3)	None
Levy <i>et al</i> ^[238]	RS	Choledochojejunal anastomotic varices (<i>n</i> = 1)	Coil embolization	1/1 (100)	No	None
Romero-Castro <i>et al</i> ^[239]	RS	Gastric varices (<i>n</i> = 4)	Coil embolization	3/4 (75)	No	None
Binmoeller <i>et al</i> ^[233]	RS	Gastric varices (<i>n</i> = 30)	CYA injection + coil embolization	30/30 (100)	4/24 (16.6)	None
Romero-Castro <i>et al</i> ^[232]	RS	Gastric varices (<i>n</i> = 30)	CYA injection (<i>n</i> = 19) vs coils (<i>n</i> = 11)	97.4 % vs 90.9%	NR	9 CYA embolization; 1 chest pain; 1 fever; 1 variceal bleeding
Weilert <i>et al</i> ^[240]	RS	Rectal varices (<i>n</i> = 1)	CYA injection plus coils	100%	No	None
Gonzalez <i>et al</i> ^[241]	RS	Splenic artery aneurism (<i>n</i> = 1)	CYA injection	1/1 (100)	No	None
Roberts <i>et al</i> ^[242]	RS	Visceral pseudoaneurysm (<i>n</i> = 1)	HistoAcryl injection	1/1 (100)	No	None
Roach <i>et al</i> ^[243]	RS	SMA aneurysm (<i>n</i> = 1)	Thrombin injection	1/1 (100)	No	None
Chaves <i>et al</i> ^[244]	RS	SMA aneurysm (<i>n</i> = 1)	Thrombin injection	1/1 (100)	No	None
Robinson <i>et al</i> ^[245]	RS	Splenic artery aneurysm (<i>n</i> = 1)	Thrombin injection	1/1 (100)	No	None
Lameris <i>et al</i> ^[246]	RS	Visceral pseudoaneurysm (<i>n</i> = 1)	Thrombin + collagen injection	1/1 (100)	No	None

(Fabri *et al* WJG 2014)

“Endohepatología”



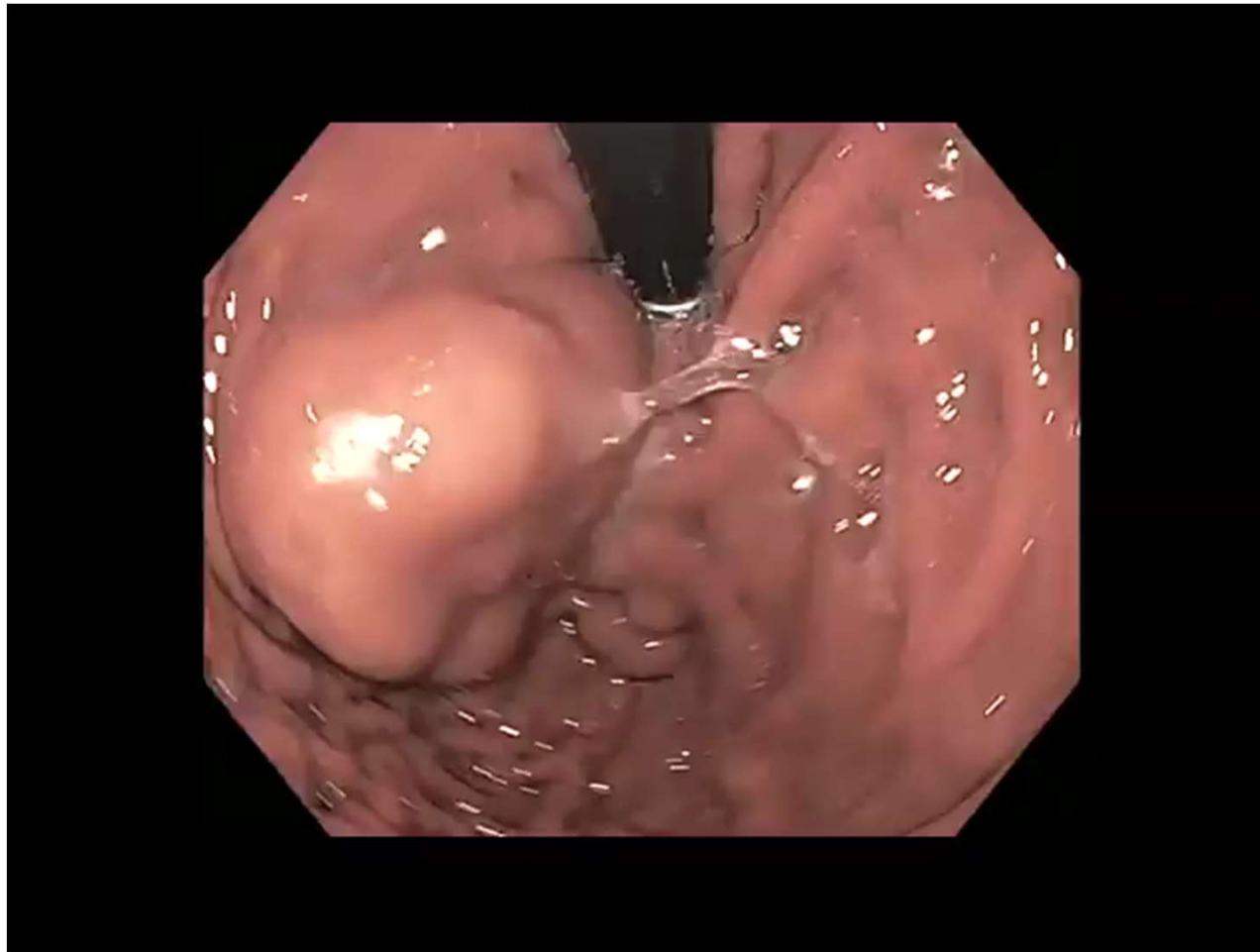
DIRECTORA DEL CURSO: **MARÍA VARELA (OVIEDO)**

ACTUALIZACIÓN EN EL DIAGNÓSTICO Y TRATAMIENTO MULTIDISCIPLINAR DE LAS ENFERMEDADES HEPÁTICAS

Manejo endoscópico y radiológico de las complicaciones de la hipertensión portal.
Enrique Vázquez Sequeiros (Hospital Ramón y Cajal. Madrid)



Inyección de pegamento +/- Implante coil x USE



EUS-guided portal pressure gradient measurement with a novel 25-gauge needle device versus standard transjugular approach: a comparison animal study

Jason Y. Huang, FRACP, Jason B. Samarasena, MD, Takeshi Tsujino, MD, Kenneth J. Chang, MD

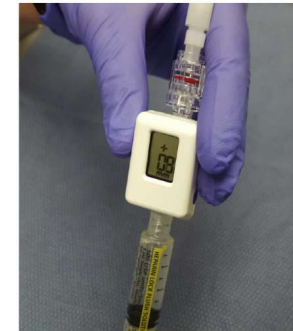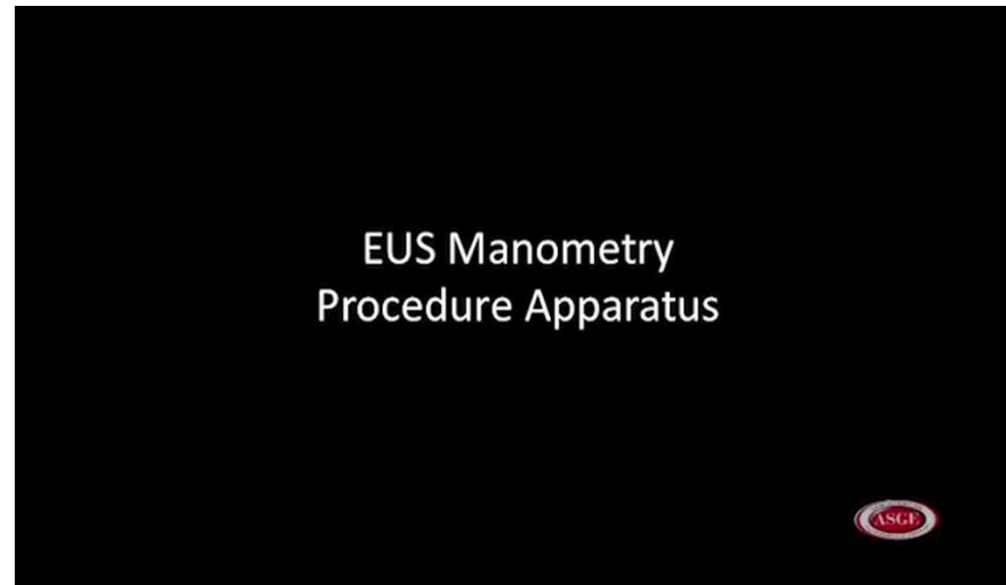
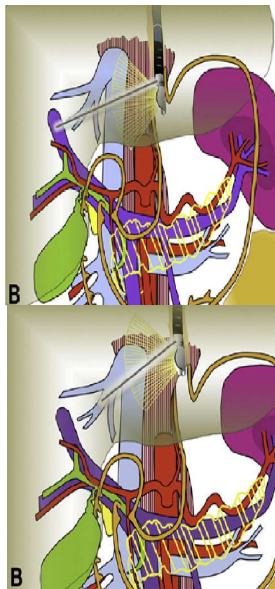


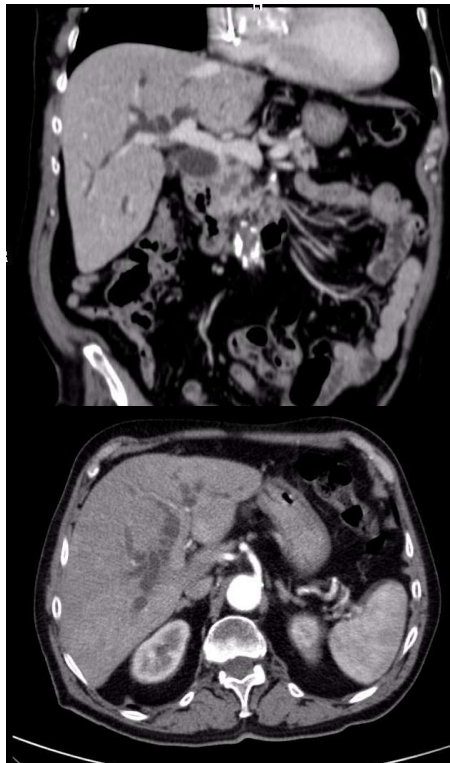Figure 1. Compact pocket-sized battery-operated manometer.

Drenaje por ecoendoscopia de la vía biliar

Enrique Vázquez Sequeiros

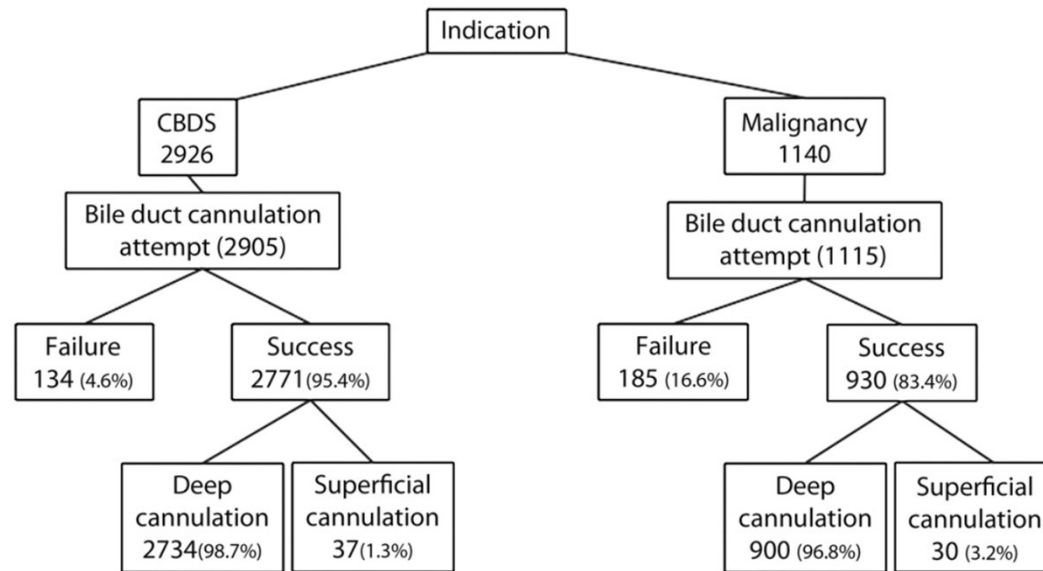


INTRODUCCIÓN

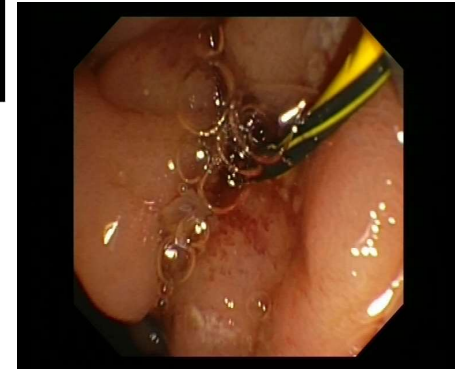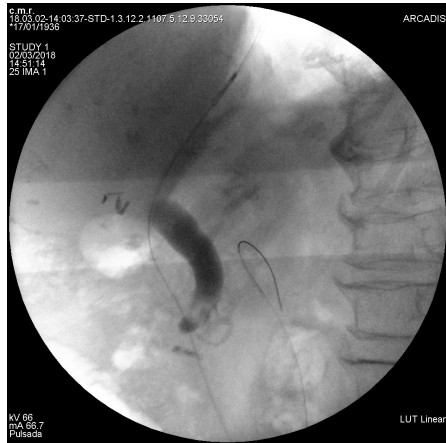
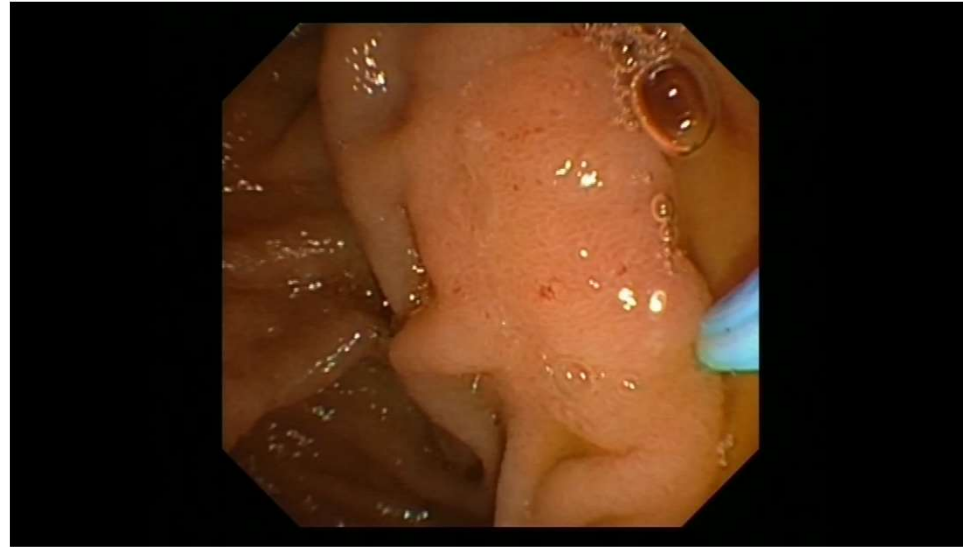
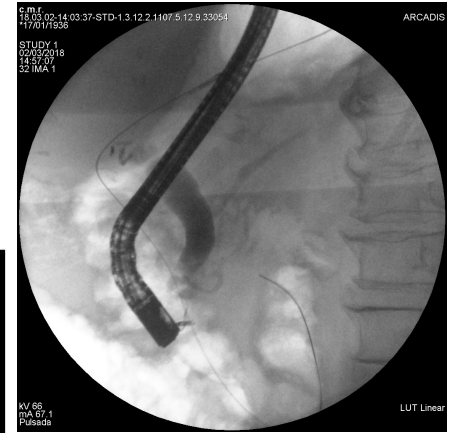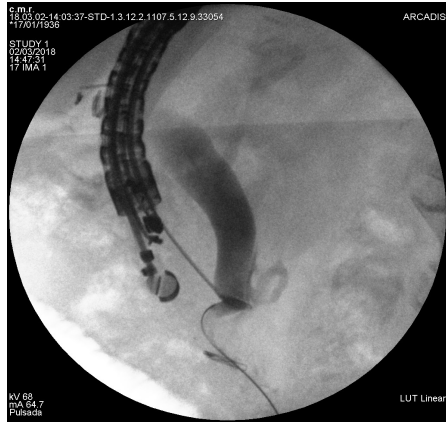


Nationwide, population-based data from 11,074 ERCP procedures from the Swedish Registry for Gallstone Surgery and ERCP

Lars Enochsson, MD, PhD, Fredrik Swahn, MD, Urban Arnelo, MD, PhD, Magnus Nilsson, MD, PhD, Matthias Löhr, MD, PhD, Gunnar Persson, MD, PhD



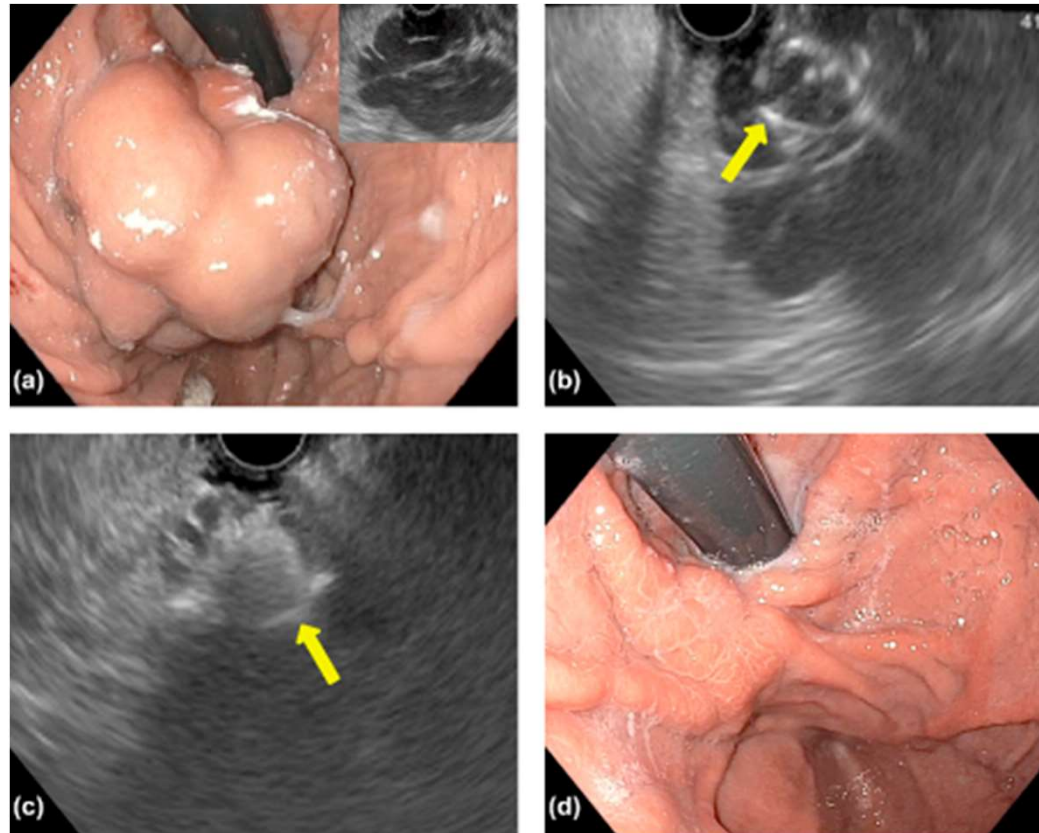
ESGE (2017)
Anderloni (2019)



EUS-guided choledocoduodenostomy

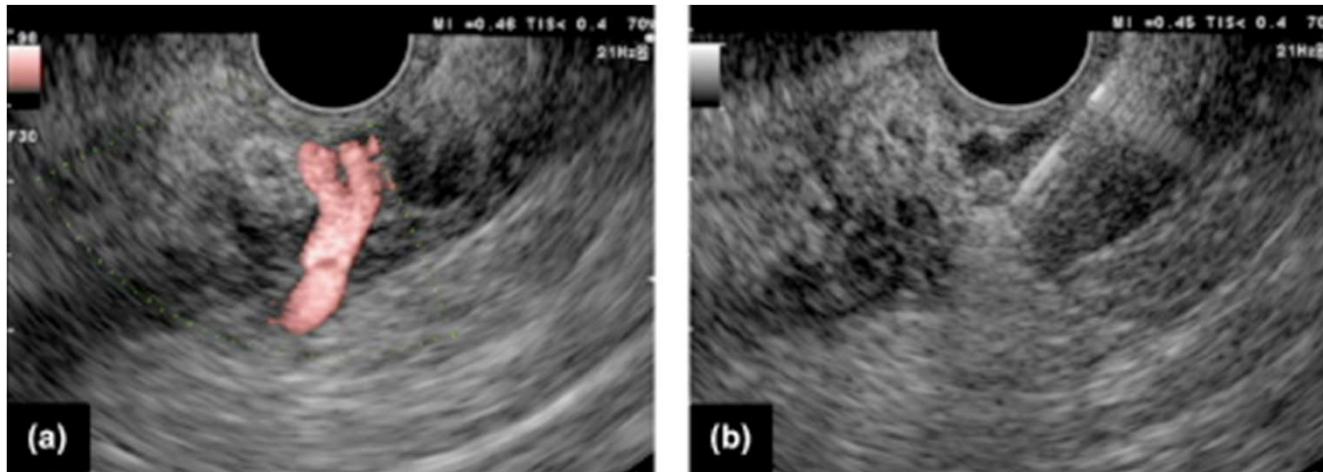
AXIOS

TERAPIA VASCULAR GUIADA POR USE



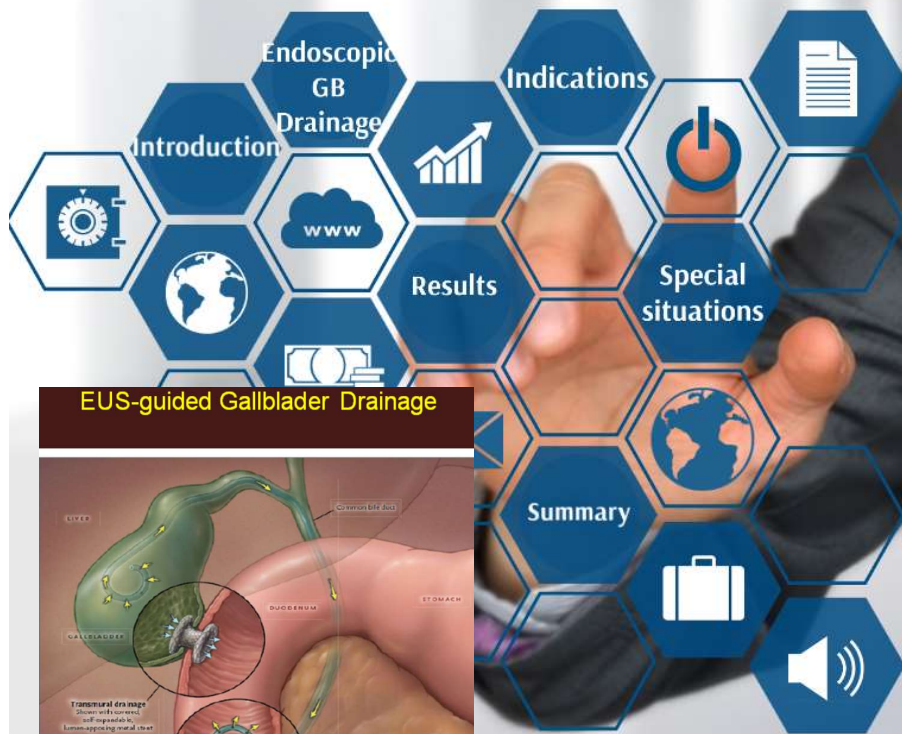Endoscopic ultrasound (EUS)-guided coil and glue therapy for gastric fundal varices. (a) Fundal varix, with EUS image (insert); (b) deployment of coil (arrow) through the 19-gauge needle; (c) glue and coil complex (arrow) after injection of cyanoacrylate glue through the 19-gauge needle; (d) eradication of fundal varices on 9 months follow-up endoscopy

TERAPIA VASCULAR GUIADA POR USE

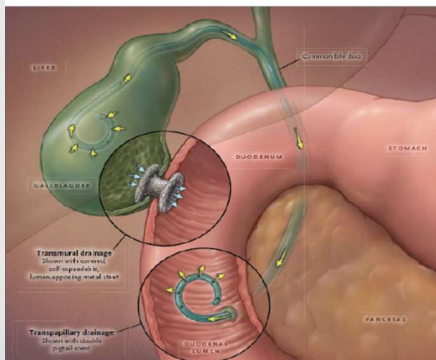


Cyanoacrylate glue injection into the feeder artery of a bleeding Dieulafoy lesion to stop refractory bleeding. (a) Doppler showing feeder vessel traversing the gastric wall; (b) Glue injection through the fine-needle aspiration needle in feeder vessel

- Punción portal para medida de presiones
- TIPS
- Embolización con coils
- Intervencionismo cardíaco



EUS-guided Gallbladder Drainage



Especialización en
Ultrasonografía Endoscópica Avanzada

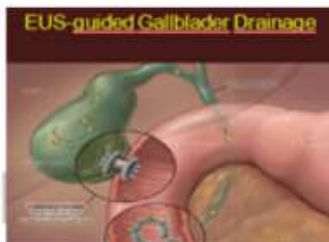DIGESTIVO
RAMON Y CAJAL
MADRID

Universidad de Alcalá

EUS-GUIDED GALLBLADDER DRAINAGE

Enrique Vázquez Sequeiros
Gastroenterology & Hepatology Service
University Hospital Ramón y Cajal. IRYCIS. Madrid.

Hospital Universitario Ramón y Cajal
Comunidad de Madrid



ARTICLE IN PRESS

NEW METHODS


EUS-guided gallbladder drainage for rescue treatment of malignant distal biliary obstruction after unsuccessful ERCP

Hajime Imai, MD, Masayuki Kitano, MD, PhD, Shunsuke Omoto, MD, Kumpei Kadosaka, MD, Ken Kamata, MD, PhD, Takeshi Miyata, MD, Kentaro Yamao, MD, Hiroki Sakamoto, MD, PhD, Yogesh Harwani, MD, Masatoshi Kudo, MD, PhD

Osaka-sayama, Japan

Endoscopic ultrasonography-guided cholecystogastrostomy in patients with unresectable pancreatic cancer using anti-migratory metal stents: A new approach

Jessica Widmer,¹ Paloma Alvarez,² Monica Gaidhane,¹ Naveen Paddu,¹ Hiren Umrana, Reem Sharaiha¹ and Michel Kahaleh¹



Angels Ginès
Hospital Clínic. Barcelona