

Usefulness of endoscopic ultrasonography in preoperative gastric cancer staging: diagnostic yield and therapeutic impact

A. Repiso¹, R. Gómez-Rodríguez¹, R. López-Pardo², M. M. Lombera¹, M. Romero¹, A. Aranzana², S. Abad², R. Rodríguez-Merlo³, L. López⁴ and J. M. Carrobles¹

Departments of ¹Gastroenterology, ²General Surgery, ³Pathology, and ⁴Medical Oncology. Hospital "Virgen de la Salud". Toledo, Spain

ABSTRACT

Objectives: to evaluate the diagnostic yield of endoscopic ultrasonography in loco-regional staging of gastric cancer in our medium and to determine the impact of this technique on later therapeutic management.

Material and methods: this is a retrospective study carried out on patients histologically diagnosed with gastric adenocarcinoma who had been referred for endoscopic ultrasonographic examination. The technique results were compared with those obtained from surgical samples and/or from exploratory laparoscopy-laparotomy. We compared the initial therapeutic decision based on conventional diagnostic techniques with the final therapeutic management based on the endoscopic ultrasonography results.

Results: forty-six patients with gastric adenocarcinoma were included in the study (a reference exploration was available in 36 cases). Diagnostic precision was 70% in stage T, while in stages T1, T2, T3 y T4 was 100, 38, 82, and 100%, respectively. The sensitivity and specificity to differentiate T1-2 from T3-4 was 94 and 85%, respectively. We could not identify factors associated with obtaining a correct diagnosis in staging T. Diagnostic precision was 72% for stage N (N0: 58%; Nx 88%). The presence of free perigastric fluid was identified in 7 cases; the presence of peritoneal carcinomatosis was later confirmed in 5 of these. The result of endoscopic ultrasonography led to a modification in the subsequent therapeutic management in 13 patients (28%).

Conclusions: endoscopic ultrasonography is a useful technique for loco-regional staging of gastric adenocarcinoma, which may have important implications in the therapeutic management of these patients.

Key words: Gastric cancer. Endoscopic ultrasonography. Treatment.

Repiso A, Gómez-Rodríguez R, López-Pardo R, Lombera MM, Romero M, Aranzana A, Abad S, Rodríguez-Merlo R, López L, Carrobles JM. Usefulness of endoscopic ultrasonography in preoperative gastric cancer staging: diagnostic yield and therapeutic impact. *Rev Esp Enferm Dig* 2010; 102: 413-420.

Received: 30-12-09.

Accepted: 26-01-10.

Correspondence: Alejandro Repiso Ortega. Servicio de Aparato Digestivo. Hospital "Virgen de la Salud". Avda Barber, 30. 45004 Toledo, Spain. e-mail: arepiso@sescam.jccm.es).

RESUMEN

Objetivos: valorar la rentabilidad diagnóstica de la ecoendoscopia en la estadificación locorregional del cáncer gástrico en nuestro medio y determinar el impacto de la técnica sobre el manejo terapéutico posterior.

Material y métodos: estudio retrospectivo realizado en pacientes diagnosticados histológicamente de adenocarcinoma gástrico que habían sido remitidos para la realización de ecoendoscopia. Se comparó el resultado de la técnica con el estudio final obtenido en la pieza operatoria y/o laparoscopia-laparotomía exploradora. Se comparó la decisión terapéutica inicial basada en los resultados de las técnicas diagnósticas convencionales, con el manejo terapéutico final basado en el resultado de la ecoendoscopia.

Resultados: se incluyeron en el estudio 46 pacientes con adenocarcinoma gástrico (en 36 de los cuales se disponía de exploración de referencia). La precisión diagnóstica fue del 70% para el estadio T, y para T1, T2, T3 y T4 del 100, 38, 82 y 100%, respectivamente. La sensibilidad y especificidad para diferenciar el estadio T1-2 del T3-4 fue del 94 y 85% respectivamente. No se identificaron factores relacionados con la obtención de un diagnóstico correcto en la estadificación T. La precisión diagnóstica fue del 72% para el estadio N (N0: 58%; Nx 88%). En 7 pacientes se identificó la presencia de líquido libre perigástrico, en 5 de los cuales se confirmó posteriormente la existencia de carcinomatosis peritoneal. En 13 pacientes (28%) del resultado de la ecoendoscopia se derivó una modificación en el manejo terapéutico posterior.

Conclusiones: la ecoendoscopia es una técnica útil en la estadificación locorregional del adenocarcinoma gástrico, lo que puede tener importantes implicaciones en el manejo terapéutico de estos pacientes.

Palabras clave: Cáncer gástrico. Ecoendoscopia. Tratamiento.

INTRODUCTION

Despite a global decrease in cases of gastric cancer in the last decade, it is still one of the most common gastrointestinal tumors and the second most common cause of death by cancer in the world (1). At the present, only surgical treatment is potentially curative in these patients and survival after surgery largely depends on the stage of the cancer at the time of the operation. Therefore precision in preoperational staging is the most important prognosis factor in the prediction of the results of surgery and survival rates and will be essential when individualized stage-dependant treatment of gastric cancer is considered, avoiding unnecessary surgery in patients with an irremovable tumors (2).

At the present, with the development of radiological, surgical and endoscopic procedures, exists a large diagnostic arsenal, but the real possibilities of each technique and the place they should occupy in preoperational staging of gastric cancer has not been clearly established in clinical practice.

It is possible to get high quality images of the gastric wall and anatomical perigastric structures by means of endoscopic ultrasonography, therefore, it is being used with high diagnostic yield in the loco-regional staging of the gastric cancer (3-6). However, the importance that these have for everyday medical practice has been cause for debate. While some authors do not consider a preoperational endoscopic ultrasonography study essential, as the management of these patients is surgical, independently of the loco-regional stage (7), other authors consider that the additional information supplied by endoscopic ultrasonography with regards to other imaging techniques may have important implications in the therapeutic management of these patients (8,9).

The aim of our study was: a) to value the diagnostic yield of endoscopic ultrasonography in gastric cancer loco-regional staging in our medium; b) to determine the factors related to the results of the technique; and c) to try to establish the impact of the technique on subsequent therapeutic management.

MATERIAL AND METHODS

Study group

Retrospective study carried out on patients referred to the Endoscopy Unit of the Gastroenterology Department at our hospital from January 2005 to January 2009. In the study we have included patients who had an acceptable surgical risk and who after taking their clinical history and carrying out a physical examination, analytical study, upper gastrointestinal endoscopy including biopsy, simple thorax X-ray, abdominal ultrasound and thoracoabdominal CT scan, were histologically diagnosed with gastric adenocarcinoma with an absence of distant metastasis and were then referred for an endoscopic ultrasonography test. The epidemiologic data in these patients and histological characteristics, location and

endoscopic and endoscopic ultrasonography characteristics of these tumors was collected. Patients who an adequate clinical history could not be obtained from (one patient) and those who an endoscopic ultrasonography could not be performed on (two patients with cardias level stenosis which impeded the progression of the ultrasonography endoscope) or who refused endoscopic ultrasonography (one patient).

Endoscopic ultrasound study

The endoscopic equipment used was the Olympus endoscopic ultrasound, GF-UMQ130, utilizing frequencies of 7.5 and 20 MHz. The exploration was carried out with the patient in a left lateral position consciously sedated using midazolam or propofol. Ultrasound images of gastric neoplasia were obtained positioning the tip of the videoscope in the gastric antrum and body trying to obtain perpendicular ultrasound images of the gastric wall. Tumors were considered to be stage T1 when the mucosa-submucosa showed signs of being exclusively affected (Fig. 1), stage T2 when the thickening reaches the layer corresponding to the muscle itself (Fig. 2), stage T3 when the tumor goes beyond the muscle and affects the adventitia, producing irregularity or digitations on the external edge of the tumor (Fig. 3) and stage T4 if neighboring organs are affected (Fig. 4). It was considered to be a probable malignant adenopathy when at least two ultrasound signs of malignancy were identified, including a rounded shape, clearly limited border, homogeneous and/or superior in size to 1 cm (Fig. 5). When adenopathies were discovered in distant ganglion areas it was decided to complete the exploration carrying out an endoscopic ultrasound guided fine needle aspiration (FNAB) in those cases where finding a positive result for

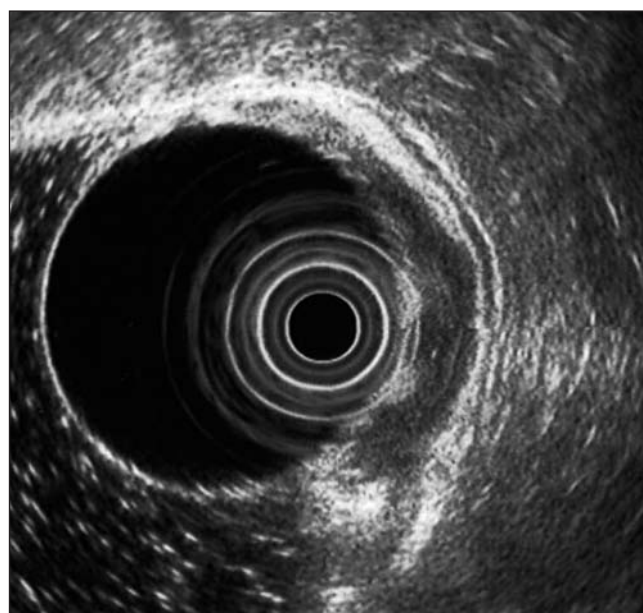


Fig. 1. Early gastric cancer (stage T1) with affected mucosa and submucosa.

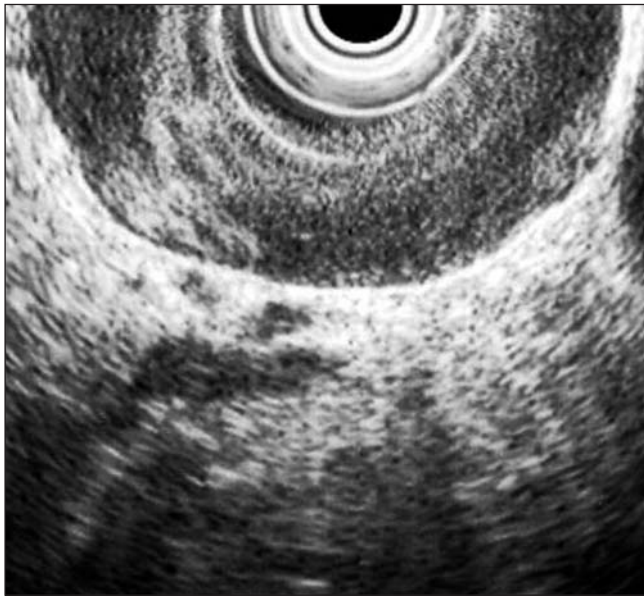

Fig. 2. Gastric cancer (stage T2) with loss of structure in layers and regular external edge.

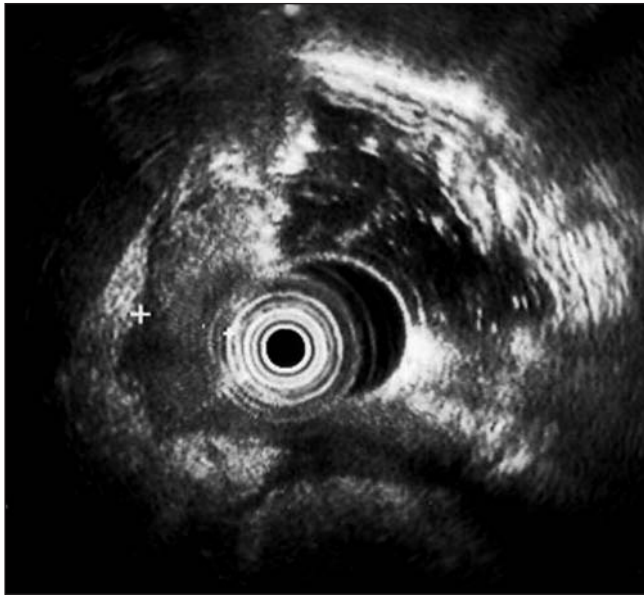


Fig. 3. Gastric cancer (stage T3). The tumor extends beyond the muscle itself and affects the serosa, producing irregularity and digitations of the outer limit of the tumor.

malignant cells could mean a change in therapeutic management of the patients. Two explorers with at least three years' experience carrying out endoscopic ultrasound scans (AR and RGR) in the same unit, using the same method and who knew the results of examinations done before the endoscopic ultrasound scans participated in the studies. Informed consent was obtained from all patients before the endoscopic examination. The result of the technique was compared with the final result obtained from the surgical sample and/or exploratory laparoscope-laparotomy.

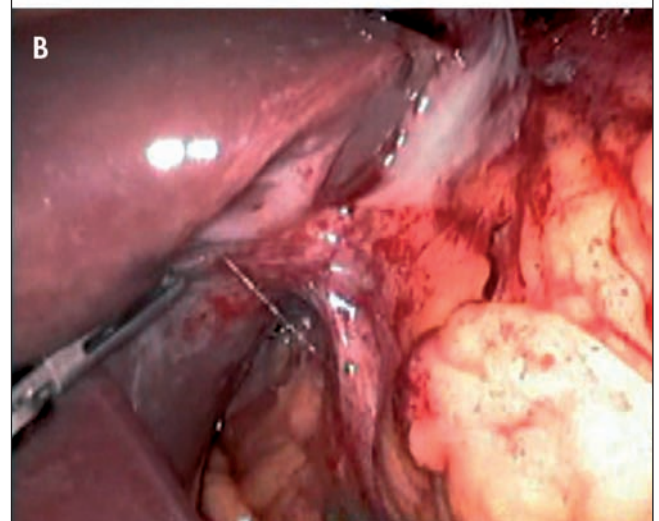
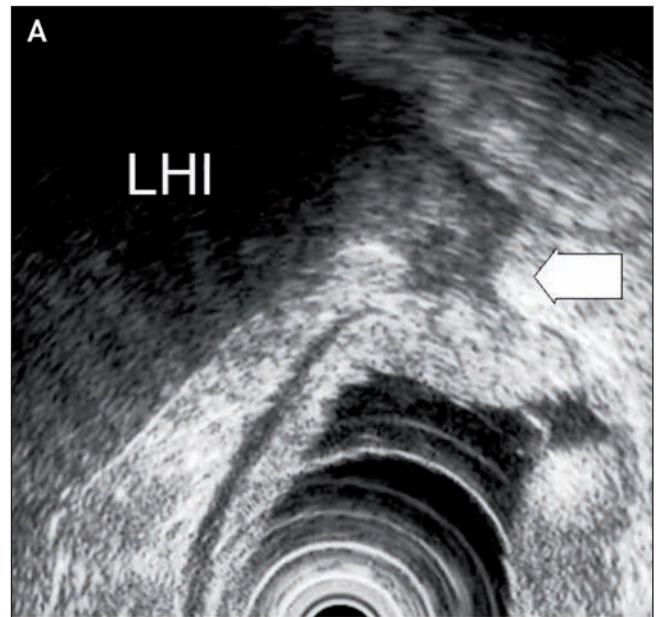


Fig. 4. A. Gastric cancer (stage T4). Hypoecogenic bridge which joins the gastric wall with the left hepatic lobe (LHL) can be seen. B. Diagnostic laparoscope of the same patient who was confirmed to suffer from tumor infiltrated left hepatic lobe.

Analysis of diagnostic-therapeutic yield

All patients were evaluated by a multidisciplinary group made up of gastroenterologists, general surgeons, oncologists and pathologists. Surgery was initially considered, as a general rule, for acceptable risk patients with localized tumors, with an absence of extensively affected ganglions. In locally advanced forms where local organs were suspected of being affected (stage T4) and/or ganglions were extensively affected, in the absence of distant metastasis, neoadjuvant chemotherapy treatment was decided on and later surgical treatment was considered when a significant response to chemotherapy treatment existed. The initial therapeutic treatment based on the results of "conventional" diagnostic

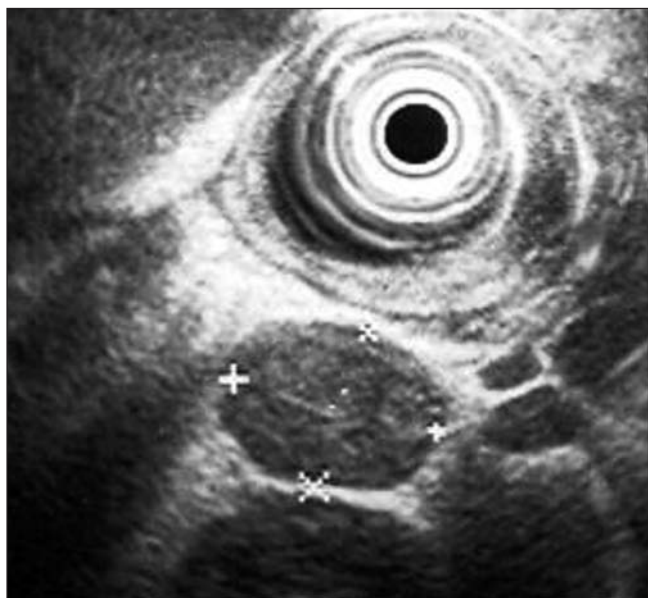


Fig. 5. Perigastric adenopathy with a malignant aspect in ultrasound. Hypoecogenic, well defined, rounded, homogeneous and larger than 1 cm.

techniques was compared with therapeutic management based on the results of endoscopic ultrasound.

Statistical study

The quantitative variables are indicated by the average standard deviation +. For the comparison of percentages the Chi-squared test was used and when at least more than 25% of the expected values were less than 5, the Fisher test was used. Values of p lower than 0.05 were considered statistically significant. All calculations were carried using the statistics software SPSS (SPSS Inc., Chicago, IL).

RESULTS

Forty-six patients diagnosed with gastric adenocarcinoma, with an average age of 64.69 (range 36-81), were

included in the study, 32 were male (70%) and 14 female (30%). Twenty-five cases had ulcerated lesions (54%). The gastric body and or fundus were affected in 36 patients, the antrum in 9 patients and the body and antrum in one case. Histologically, in 15 cases the tumors were poorly differentiated and in 31 moderately or well differentiated.

In the diagnostic yield evaluation 36 patients who had a reference examination available were included. We have included 34 who had a surgical resection available which was histologically studied and 2 patients who had irremovable tumors and whose neighboring organs were confirmed in exploratory laparoscopy (Fig. 4) as being affected (stage T4). In the analysis of diagnostic yield 2 patients who received neoadjuvant chemotherapy and who were later operated on were excluded. The result of the endoscopic ultrasound and the reference exploration coincided in 70% of cases in stages T and in T1, T2, T3 and T4 in 100, 38, 82 and 100%, respectively (Table I). The sensitivity and specificity on differentiating stages T1-2 from T3-4 was 94 and 85% respectively (Table II). No factors relating to obtaining a correct diagnosis in stage T were identified (Table III).

Seventeen patients were identified as having adenopathies with at least two ultrasound signs of malignancy. Endoscopic ultrasound and the reference exploration coincided in 72% of cases in stage N (N0: 58%; Nx 88%) (Table IV). The positive predictive value to diagnose affected ganglions was 88% (Table II). In 3 cases an exploration done using endoscopic ultrasound guided FNAB on mediastinal adenopathies (2 cases) or interaortocava (one case). Cytology of the samples obtained identified the presence of malignant cells in 2 cases.

In 7 patients (15%) the presence of free perigastric fluid was identified, in 5 (71%) the existence of peritoneal carcinomatosis was confirmed by means of a laparoscope (3 cases) (Fig. 6), exploratory laparotomy (one case) or endoscopic ultrasound guided FNAB (one case). In this last case the exploration was completed carrying out an endoscopic ultrasound guided FNAB diagnostic paracentesis at the Douglas cul-de-sac level using the transrectal path (thus avoiding contamination of the sample by tumor cells if the puncture had been

Table I. Results from EUS in the staging of parietal invasion (stage T) in 36 patients with gastric adenocarcinoma

		n	Histopathological staging				Diagnostic yield (%)
			Stage T1	Stage T2	Stage T3	Stage T4	
EUS staging	Stage T1	5	5	0	0	0	100
	Stage T2	13	5	5	2	1	38
	Stage T3	17	0	1	14	2	82
	Stage T4	1	0	0	0	1	100
	Total	36	10	6	16	4	70

Table II. Diagnostic yield with EUS in the staging of parietal (stage T) and ganglionic invasion (stage N) in 36 patients with gastric adenocarcinoma

	<i>Sensibility (%)</i>	<i>Specificity (%)</i>	<i>Positive predictive value (%)</i>	<i>Negative predictive value (%)</i>	<i>Accuracy (%)</i>
Stage T1	50	100	100	84	86
Stage T2	83	73	38	95	75
Stage T3	87	85	82	89	86
Stage T4	25	100	100	91	92
Stage T1-T2	94	85	83	94	89
Stage T3-T4	85	94	94	83	89
Stage Nx	65	85	88	59	72

Table III. Epidemiological, histological and endoscopic characteristics of 36 patients with gastric adenocarcinoma

		<i>Number of patients</i>	<i>Correct EUS diagnosis</i>	<i>Incorrect EUS diagnosis</i>	<i>p value</i>
Age	≤ 60 years	12	7 (58%)	5 (42%)	0.3
	> 60 years	24	18 (75%)	6 (25%)	—
Sex	Women	11	9 (82%)	2 (18%)	0.28
	Men	25	16 (64%)	9 (36%)	—
Histologic type	Well differentiated	26	20 (77%)	6 (23%)	0.11
	Undifferentiated	10	5 (50%)	5 (50%)	—
Localization	Gastric body	27	19 (70%)	8 (30%)	0.83
	Gastric antrum	9	6 (67%)	3 (33%)	—
Gastric ulcer	Presence	19	12 (63%)	7 (37%)	0.38
	Absence	17	13 (76%)	4 (24%)	—

Table IV. EUS results in the ganglionic stage (N stage) in 36 patients with gastric adenocarcinoma

		<i>n</i>	<i>Estadificación histopatológica</i>		<i>Diagnostic precision (%)</i>
			<i>Stage N0</i>	<i>Stage Nx</i>	
<i>Stage with EUS</i>	Stage N0	19	11	8	58
	Stage Nx	17	2	15	88
	Total	36	13	23	72

done transgastrically). It was informed as positive for malignant cells. In 5 of the 39 patients (13%) where endoscopic ultrasound did not detect the presence of ascites, peritoneal implants were identified by exploratory laparoscopy/ laparotomy.

In 13 patients (28%), the endoscopic ultrasound result led to a modification in a later therapeutic approach. Including 4 patients in which palliative treatment was indicated based on the discoveries of the endoscopic ultrasound and the endoscopic ultrasound guided FNAB (two cases where the existence of metastatic adenopathies in distant ganglion regions was confirmed, one patient's left hepatic lobe was identified as being affected by a tumor, the presence of ascites was observed in one patient who was later found to have tumorous cells by the transrectal

FNAB. Two of the four patients who started the neoadjuvant treatment were able to be rescued for curative surgical treatment (Table V).

DISCUSSION

Classically, the usefulness of endoscopic ultrasound in the loco-regional extension diagnosis of this neoplasia has been proven in multiple studies (3). Thus the diagnostic precision for stage T varies between 70 and 90% depending on the series and on what type of endoscopic ultrasound is used, ultrasound frequencies and the location of the tumor (cardia or rest of the stomach) (8-12). As we observed in our patients, most errors in

Table V. Change in the therapeutic plan after practicing EUS in 46 patients with gastric adenocarcinoma

		n	Therapeutic management suggested after EUS				Change in the therapeutic plan
			Local resection	Radical gastrectomy	Neoadjuvance treatment	Palliative treatment	
Therapeutic management based on "conventional" diagnostic techniques	Local resection	1	1	0	0	0	0 (0%)
	Radical gastrectomy	33	2	26	2	3	7 (21%)
	Neoadjuvance treatment	4	0	1	2	1	2 (50%)
	Palliative treatment	8	0	4	0	4	4 (50%)
Total		46	3	31	4	8	13 (28%)

deep staging are observed in stage T2 (8-12) tumors diagnosed by endoscopic ultrasound. On most occasions, in our series, it was caused by overstaging (tumors in

stage T1 that were wrongly interpreted as being in stage T2). Although probably due to the reduced number of cases, we did not identify technical or histological factors related to these diagnostic errors. Factors which have been described in cases of overstaging in other series include: inflammation, peritumorous necrosis and fibrosis –which usually exists in ulcerated tumor lesions– or obtaining ultrasound images tangential to the gastric wall, above all in tumors located in gastric antrum, incisura and fundus. Errors due to understaging may be due to deep microscopic invasion undetectable by the technique, ultrasound artefacts in relation to air content, mucous or food remains retained in the stomach or anatomical characteristics such as the absence of serosa at the lesser curvature and anterior wall which is why tumors in this location may be incorrectly interpreted as T2 despite transwall infiltration (8-12).

Diagnostic precision in gastric cancer endoscopic ultrasound ganglion staging is lower than in T staging and varies from 55 to 87% in published series (3). The proportion of malignant adenopathies detected is high in perigastric ganglions located in the lesser curvature but lower in other locations. Diagnostic errors described in ganglion staging has been related to the lack of diagnostic precision of ultrasound characteristics that should allow a distinction between metastatic and reactive-inflammatory adenopathies, the frequency and penetration depth of the transducers used in endoscopic ultrasound, the existence of ganglion level micrometastasis or the extension of surgical lymphadenectomy. Thus, the more ganglions are removed the more metastatic adenopathies are identified and consequently more cases of understaging with imaging techniques occur (8-12).

One endoscopic ultrasound discovery which turned out to be of great use in the management of patients with gastric cancer in our series was the presence of free perigastric fluid. In this regard, the results of a prospective series have been published which included 402 patients with gastric cancer who had not previously had the presence of ascites detected by abdominal CT and who had had the presence of ascites described by endoscopic ultrasound in 36 cases (9%) and the existence of peritoneal carcinomatosis was proven in 23 (64%) cases (13). Nevertheless, although endoscopic

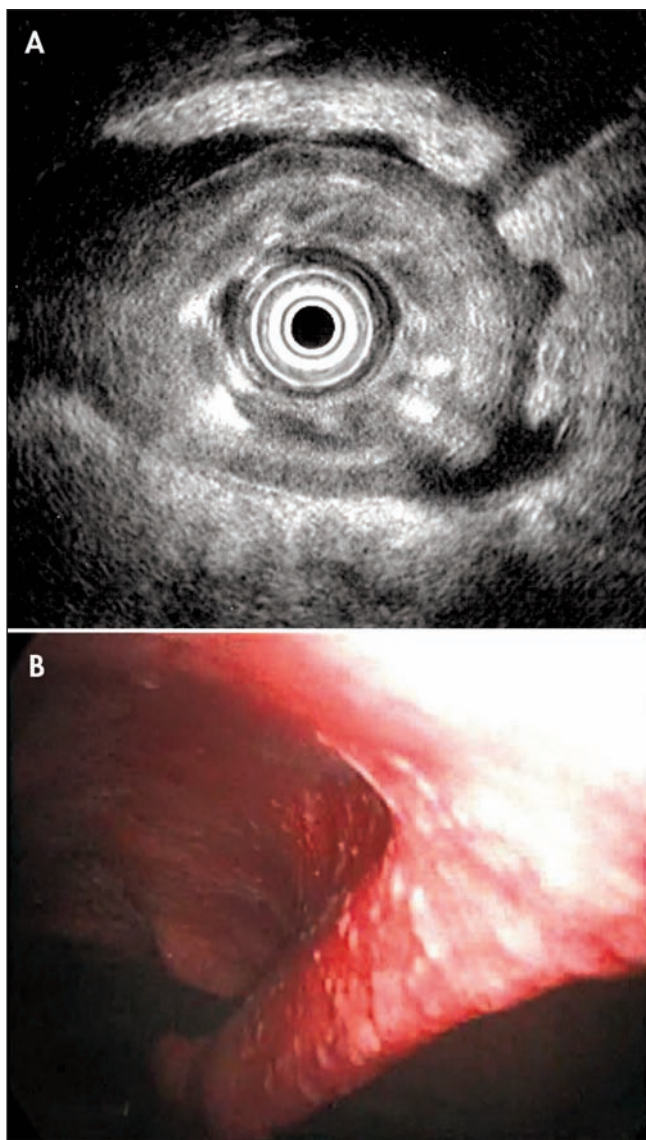


Fig. 6. A. Free perigastric fluid in a patient with adenocarcinoma in the gastric body. B. Diagnostic laparoscope of the same patient who was identified as having multiple millimetric peritoneal tumorous implants.

ultrasound detects small quantities of ascitic fluid invisible to abdominal CT, a negative result does not rule out the presence of peritoneal carcinomatosis. In centers where an exploratory laparoscope is not performed on patients with gastric cancer, the presence of free perigastric fluid in endoscopic ultrasound should lead to its being carried out (13,14).

Classically in gastric neoplasia, unlike other tumors, performance of an endoscopic ultrasound has not been considered essential, because after decades of studies, no neoadjuvant treatment existed that had been proven to be effective, and the treatment of these patients was surgical, intended as curative or palliative, independently of its loco-regional stage (2,7). At this present time, however, coinciding with the development of imaging techniques that have led to more reliable preoperational extended diagnoses and selecting the patients who, in this way, will benefit from neoadjuvant treatments (avoiding overtreatment that could occur in previous studies), a perioperational strategy has proven to prolong survival. Also in a recent English multicentre study (15) 503 patients with potentially removable gastric cancer were included (stage T2-T4 and/or N1-N3) who were randomized to receive either only surgery or perioperational chemotherapy, using three cycles prior to surgery followed by additional cycles after removal, and after a period of follow up in the chemotherapy therapy group of patients, a significant improvement in global survival levels was observed (36 vs. 23%). Nevertheless, the implications that these results have on endoscopic ultrasound staging of patients with gastric cancer is limited because with the exception of stage T tumors (early gastric cancer) where the initial analysis would be either surgical or ultrasound (in selected cases), the decision to begin neoadjuvant treatment depended on the presence of absence of distant metastasis and not on stage T or N. Therefore, in most cases the result of the endoscopic ultrasound did not modify patient management based on abdominal CT results. Based on these results, in many centers the neoadjuvant treatment has become the normal procedure to follow (16,17) and in addition it has led to other studies which are evaluating complex preoperational models depending on the stage of the tumor, and as is established in esophagus and rectum cancer only patients with certain stages will benefit from the treatment, which is why precise staging is essential to therapeutic management (18). In this respect, endoscopic ultrasound, despite its limitations, could have important implications in the therapeutic management of these patients, as we have been able to show, our series allows us to distinguish, with a high degree of diagnostic yield, tumors in T1-2 from those which are locally advanced in stage T3-4. While waiting for these results another possible procedural model, closer to what we have been using in our medium is to reserve neoadjuvant treatment for patients in stage T4 without distant metastasis or with extensively affected ganglions, which would mean carrying out an extended lymphadenectomy and consider later surgical treatment

when a significant response to chemotherapy treatment existed (19). Endoscopic ultrasound plays an important role in this decision as the diagnostic precision is still superior to other imaging techniques in the study of invasion depth (11).

To sum up, endoscopic ultrasound is a useful technique in preoperative staging of gastric cancer where the results can lead to important decisions in the management of these patients. Decisions about potentially removable tumour endoscopic ultrasound preoperational staging must be individualized according to the experience, availability and the decision of multidisciplinary work groups that evaluate possible diagnostic-therapeutic strategies.

REFERENCES

- Roder DM. The epidemiology of gastric cancer. *Gastric Cancer* 2002; 5: S5-11.
- Allum WH, Griffin SM, Watson A, Colin-Jones D; Association of Upper Gastrointestinal Surgeons of Great Britain and Ireland; British Society of Gastroenterology; British Association of Surgical Oncology. Guidelines for the management of oesophageal and gastric cancer. *Gut* 2002; 50: 1-23.
- Puli SR, Reddy JBK, Bechtold ML, Antillon MR, Ibdah JA. How good is endoscopic ultrasound for TNM staging of gastric cancers? A meta-analysis and systemic review. *World J Gastroenterol* 2008; 14: 4011-9.
- Habermann CR, Weiss F, Riecken R, Honarpisheh H, Bohnacker S, Staedtler C, et al. Preoperative staging of gastric adenocarcinoma: comparison of helical CT and endoscopic US. *Radiology* 2004; 230: 465-71.
- Hizawa K, Iwai K, Esaki M, Matsumoto T, Suekane H, Iida M. Is endoscopic ultrasonography indispensable in assessing the appropriateness of endoscopic resection for gastric cancer? *Endoscopy* 2002; 34: 973-8.
- Bhandari S, Shim CS, Kim JH, Jung IS, Cho JY, Lee JS, et al. Usefulness of three-dimensional, multidetector row CT (virtual gastroscopy and multiplanar reconstruction) in the evaluation of gastric cancer: a comparison with conventional endoscopy, EUS, and histopathology. *Gastrointest Endosc* 2004; 59: 619-26.
- Soria MT, Fuenmayor R, Llach J. Ecoendoscopia en el diagnóstico de extensión de las neoplasias digestivas. *Gastroenterol Hepatol* 2002; 25: 7-12.
- Xi WD, Zhao C, Ren GS. Endoscopic ultrasonography in preoperative staging of gastric cancer: determination of tumor invasion depth, nodal involvement and surgical respectability. *World J Gastroenterol* 2003; 9: 254-7.
- Ganpathi IS, So JB, Ho KY. Endoscopic ultrasonography for gastric cancer. Does it influence treatment? *Surg Endosc* 2006; 20: 559-62.
- Tsendsuren T, Jun SM, Mian XH. Usefulness of endoscopic ultrasonography in preoperative TNM staging of gastric cancer. *World J Gastroenterol* 2006; 12: 43-7.
- Polkowski M, Palucki J, Wronska E, Szawlowski A, Nasierowska-Guttmejer A, Butruk E. Endosonography versus helical computed tomography for locoregional staging of gastric cancer. *Endoscopy* 2004; 36: 617-23.
- Willis S, Truong S, Gribnitz S, Fass J, Schumpelick V. Endoscopic ultrasonography in the preoperative staging of gastric cancer. *Surg Endosc* 2000; 14: 951-4.
- Chu KM, Kwok KF, Law S, Wong KH. A prospective evaluation of catheter probe EUS for the detection of ascites in patients with gastric carcinoma. *Gastrointest Endosc* 2004; 59: 471-4.
- Sultan J, Robinson S, Hayes N, Griffin SM, Richardson DL, Preston SR. Endoscopic ultrasonography-detected low-volume ascites as a predictor of inoperability for oesophagogastric cancer. *Br J Surg*

- 2008; 95: 1127-30.
15. Cunningham D, Allum WH, Stenning SP, Thompson JN, Van de Velde CJ, Nicolson M, et al. Perioperative chemotherapy versus surgery alone for resectable gastroesophageal cancer. *N Engl J Med* 2006; 355: 11-20.
 16. Van Cutsem E, Dicato M, Arber N, Benson A, Cunningham D, Díaz-Rubio E, et al. The neo-adjuvant, surgical and adjuvant treatment of gastric adenocarcinoma. Current expert opinion derived from the Seventh World Congress on Gastrointestinal Cancer, Barcelona, 2005. *Ann Oncol* 2006; 17: 13-8.
 17. Cunningham D, Oliveira J. Gastric cancer: ESMO clinical recommendations for diagnosis, treatment and follow-up. *Ann Oncol* 2008; 19: 23-4.
 18. De Vita F, Giuliani F, Galizia G, Belli C, Aurilio G, Santabarbara G, et al. Neo-adjuvant and adjuvant chemotherapy of gastric cancer. *Ann Oncol* 2007; 18: 20-3.
 19. Kida M. EUS in gastric cancer. In: Hawes RH, Fockens P, editors. *Endosonography*. Philadelphia: Elsevier Inc.; 2006. p. 111-26.