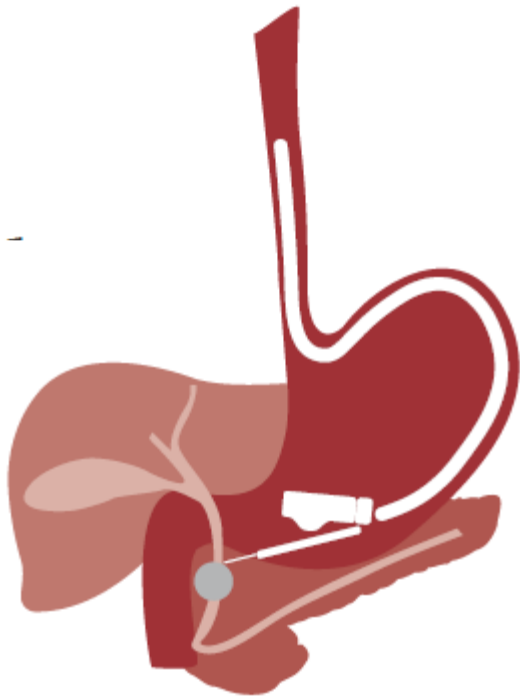


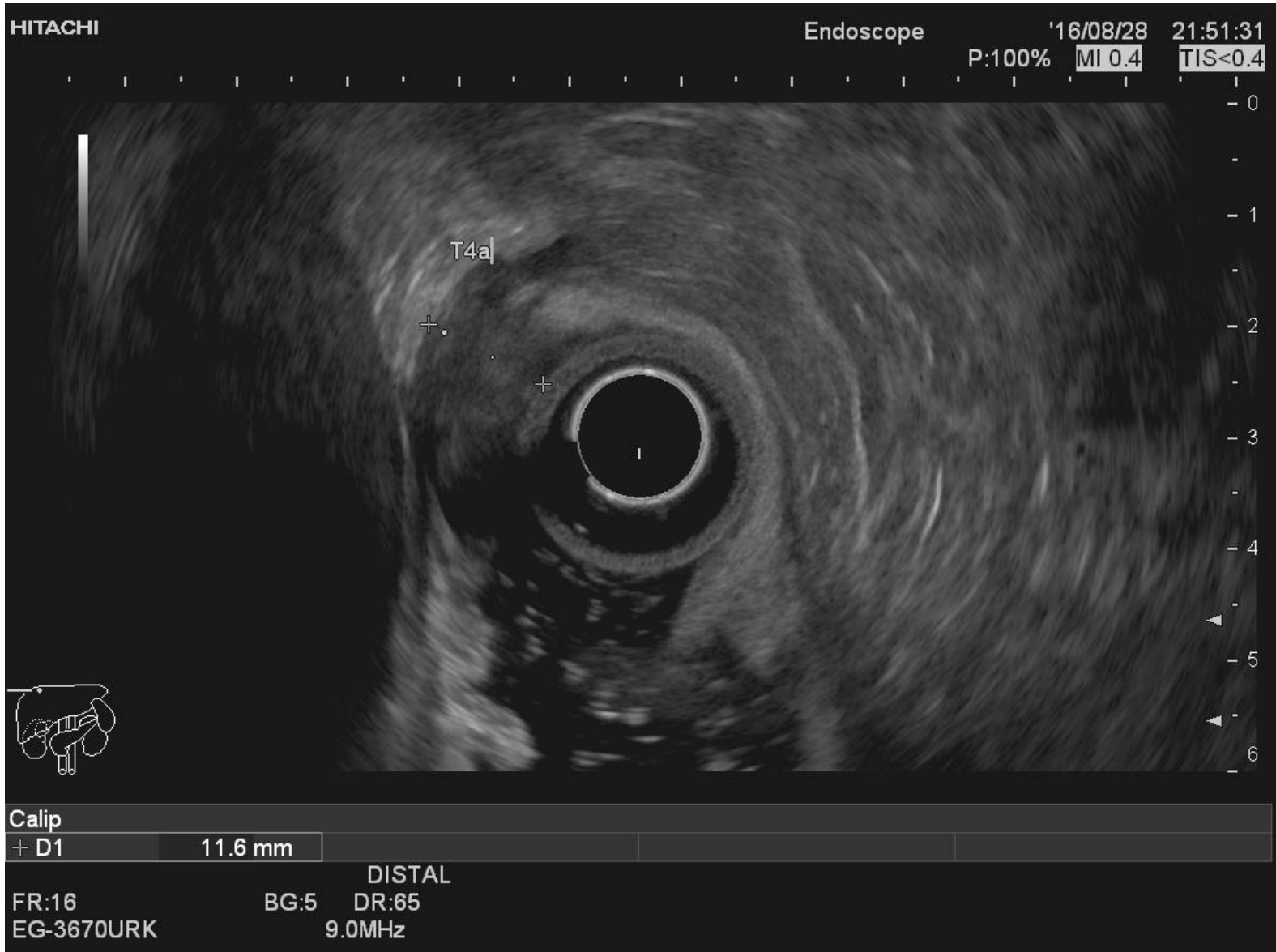**Especialización en
Ultrasonografía
Endoscópica Avanzada**



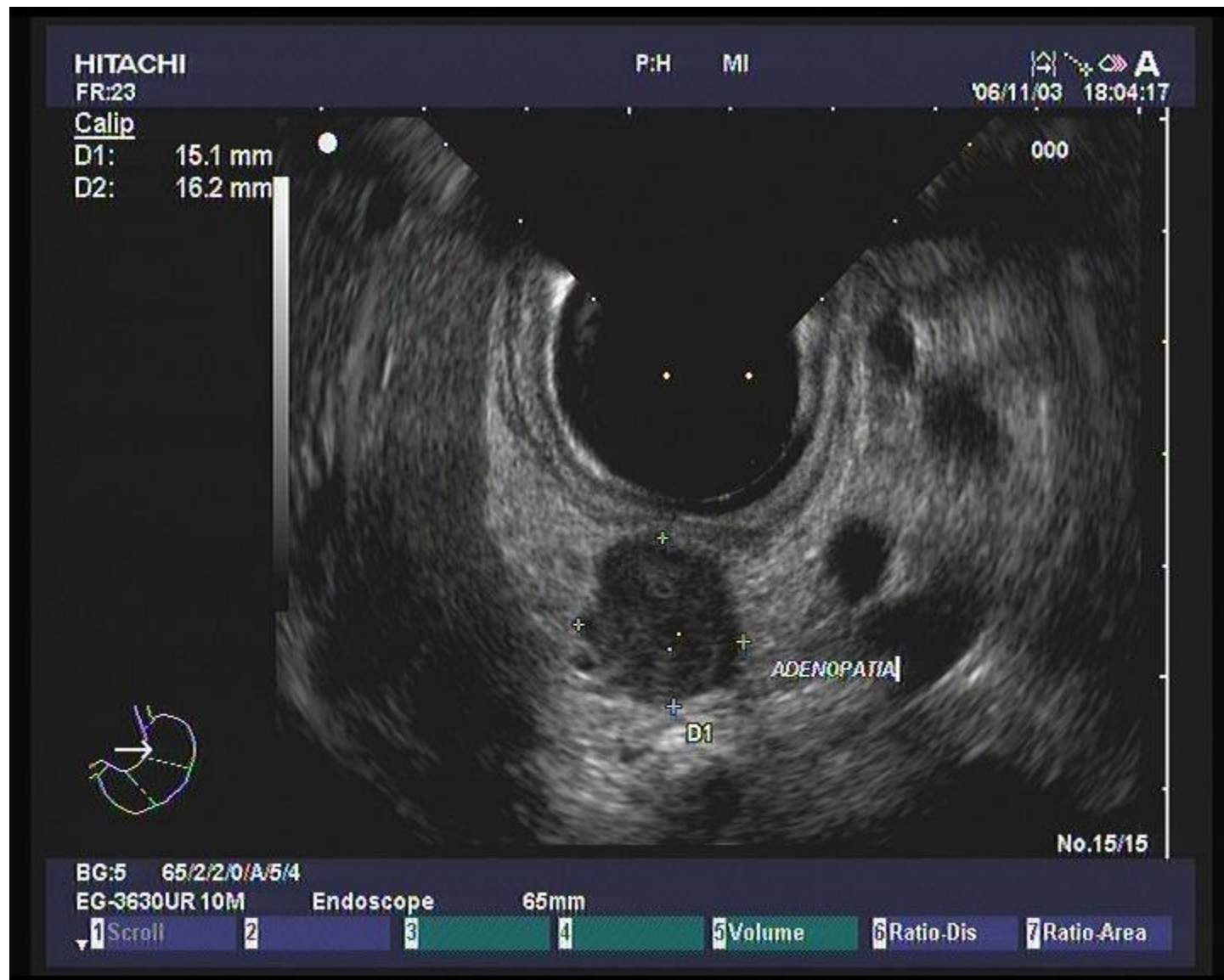GALERÍA IMÁGENES ECOENDOSCOPIA NEOPLASIA GÁSTRICA Y LINFOMA

Servicio de Gastroenterología y Hepatología
Hospital Universitario Ramón y Cajal

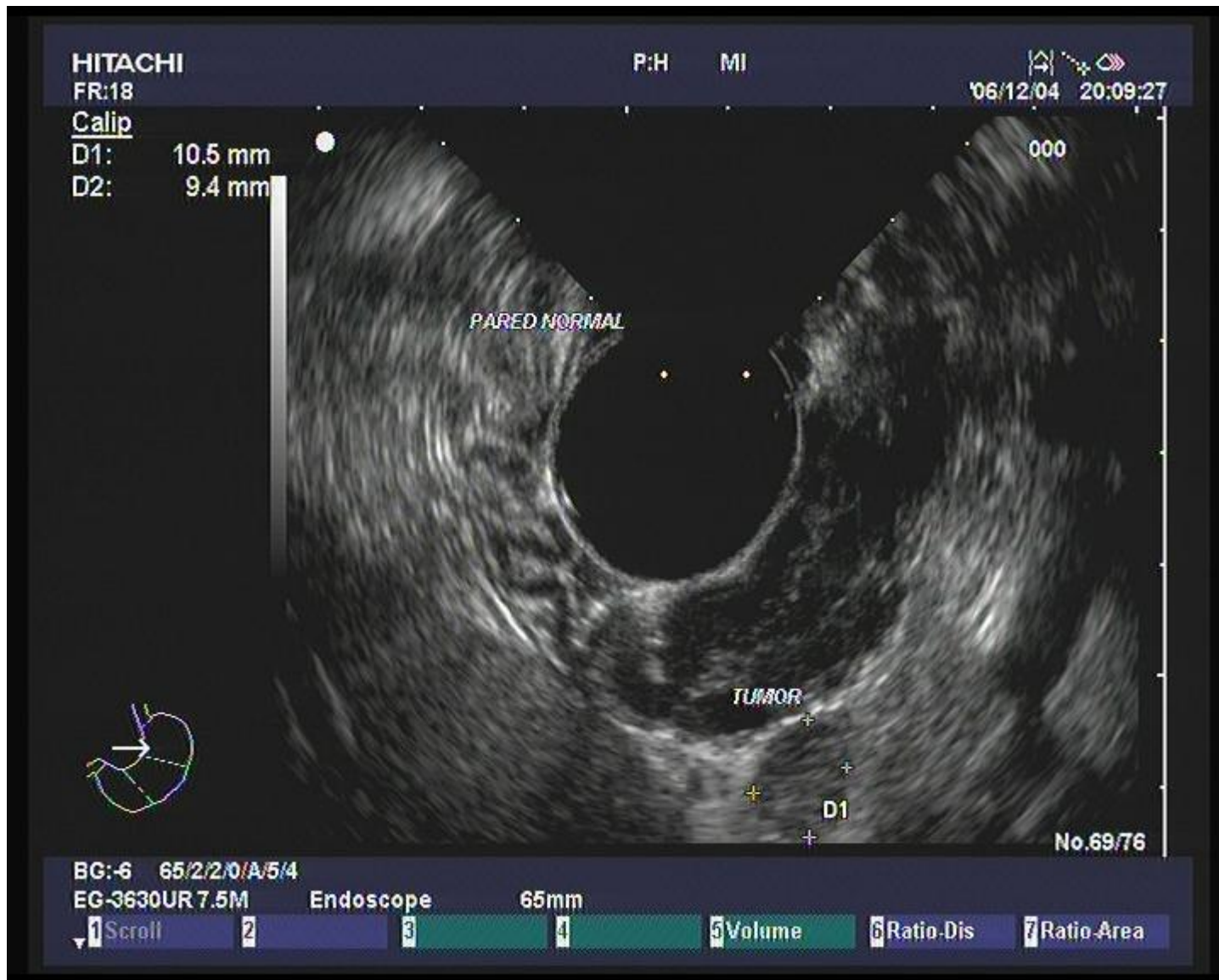NEOPLASIA GÁSTRICA T4a



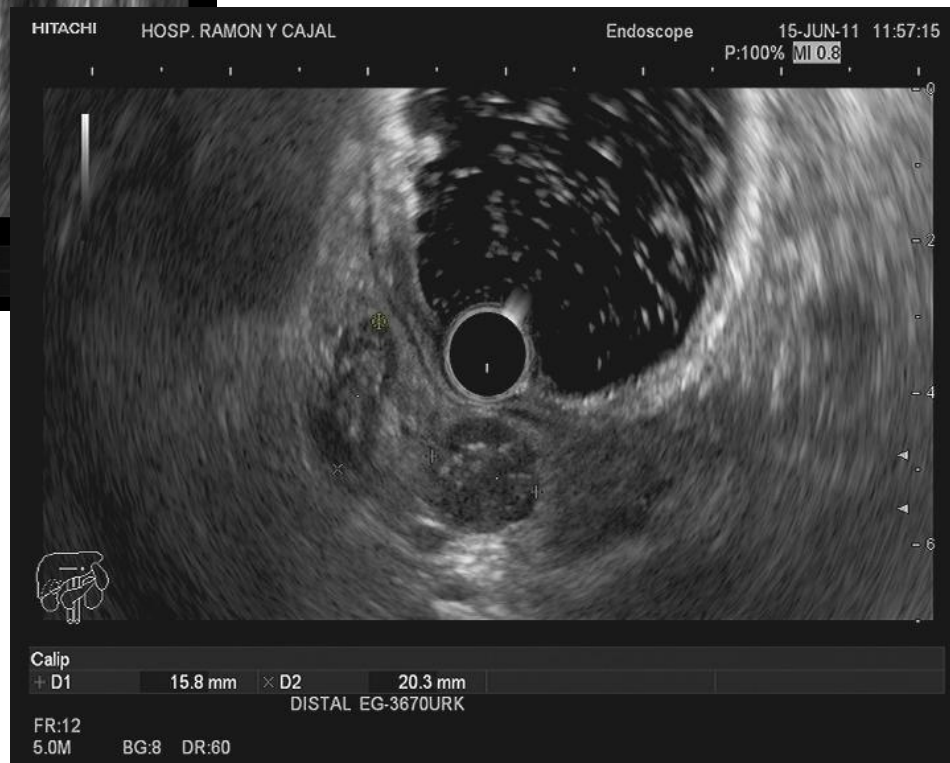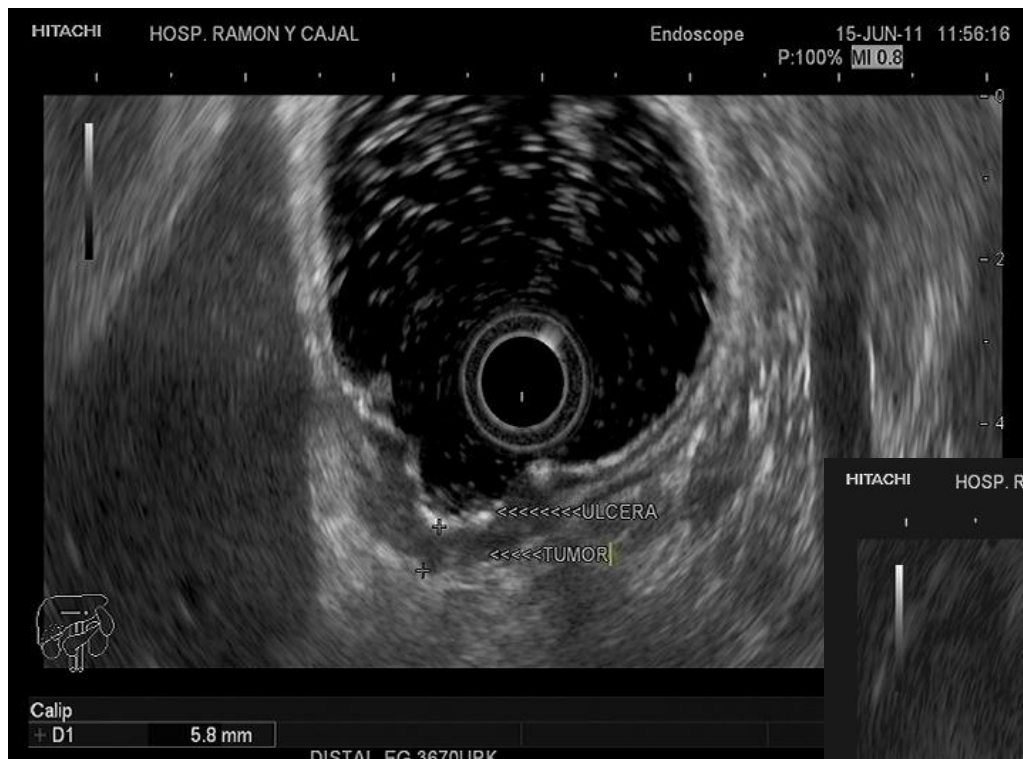ADENOPATÍA NEOPLÁSICA EN ADENOCARCINOMA GÁSTRICO



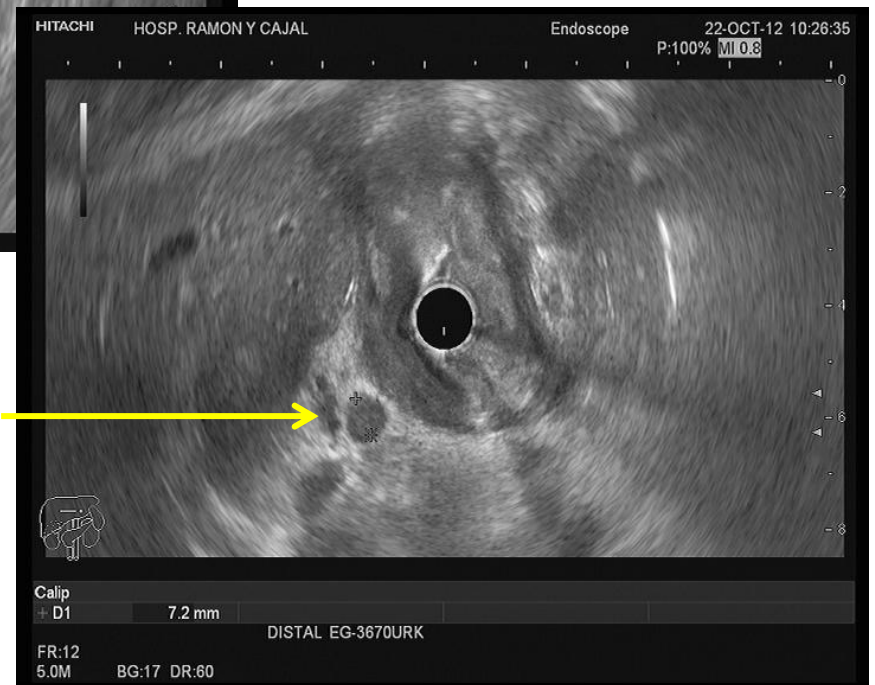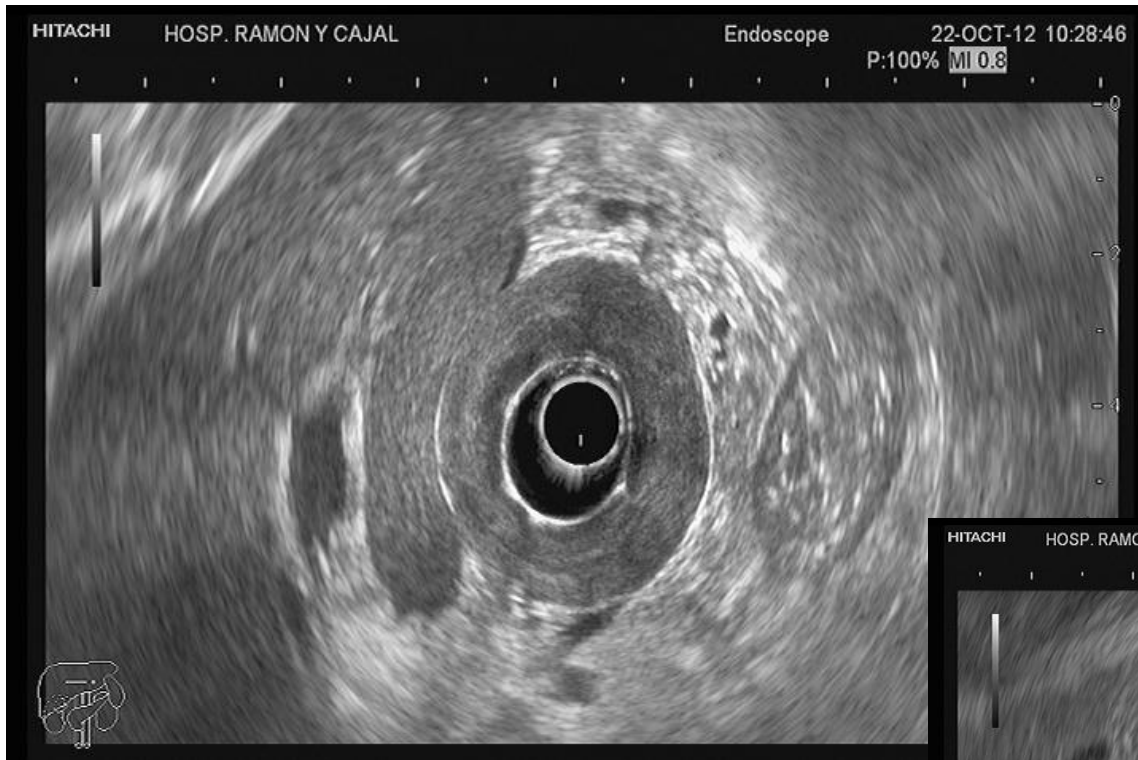ADENOCARCINOMA GÁSTRICO T4a y ADENOPATÍA



ADENOCARCINOMA GÁSTRICO T4aN2

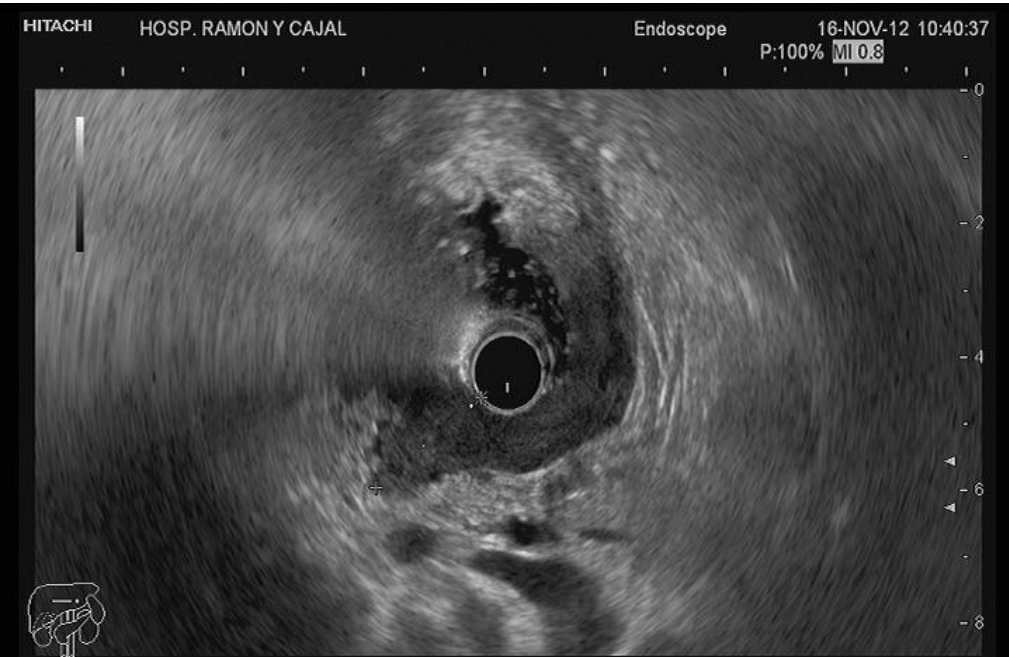
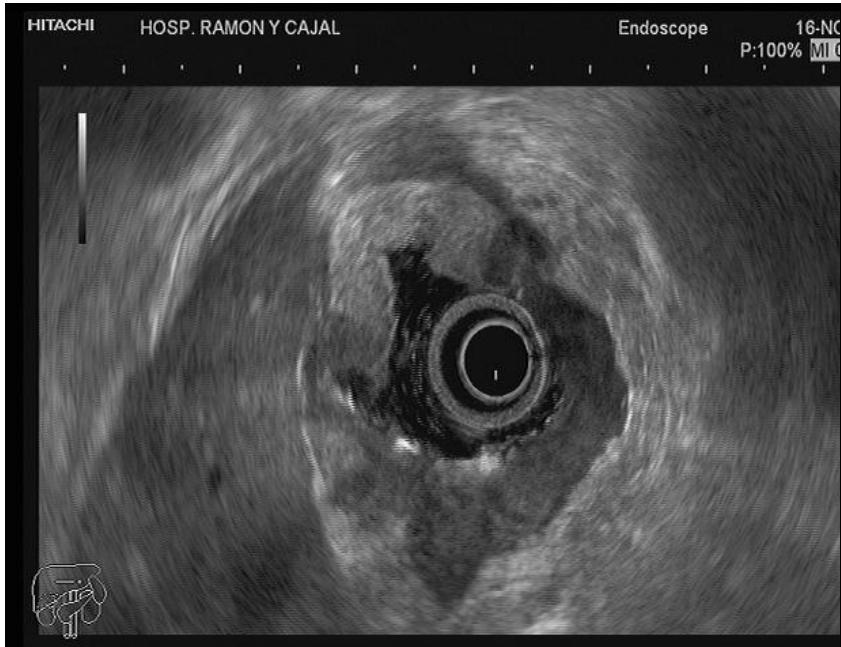
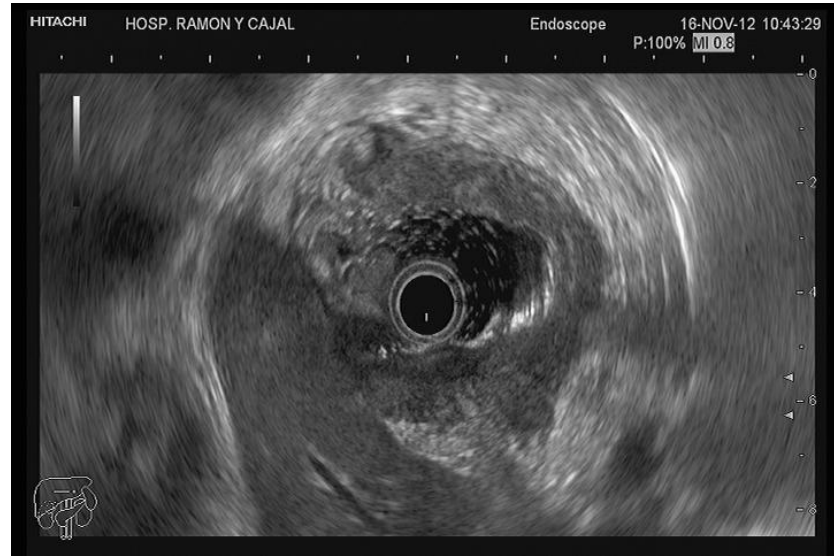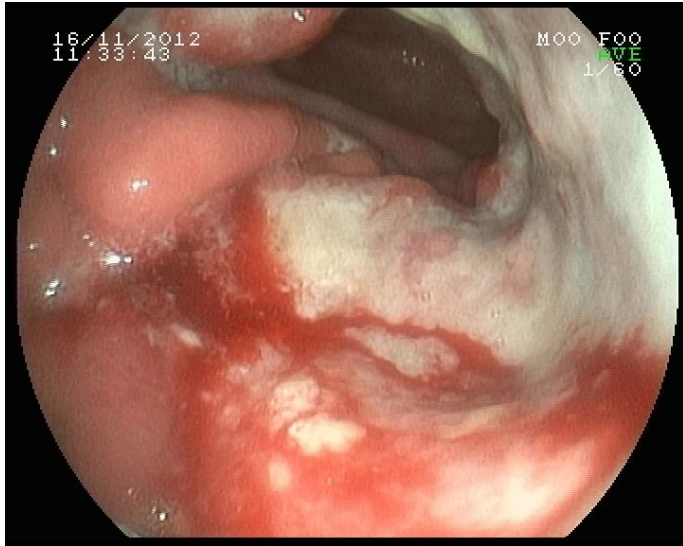


ADENOCARCINOMA ANILLO SELLO /LINITIS PLÁSTICA

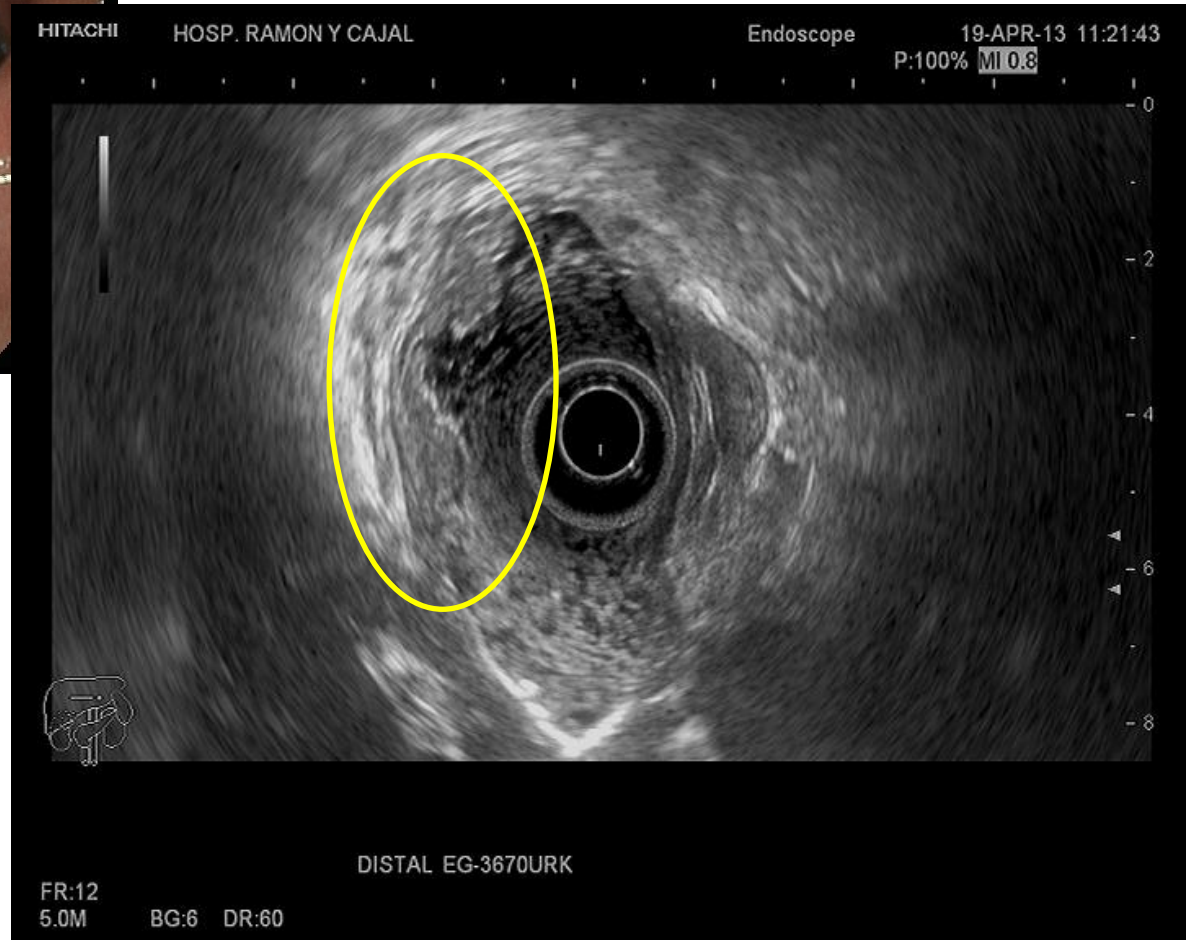
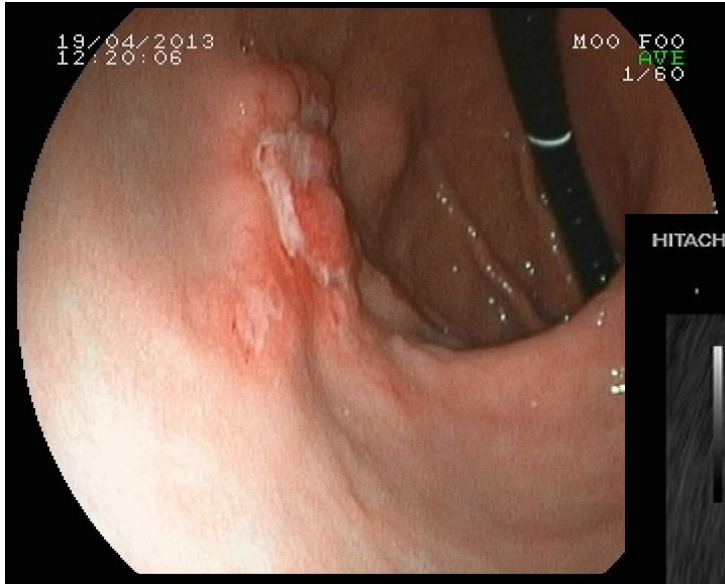


ADENOPATÍA NEOPLÁSICA

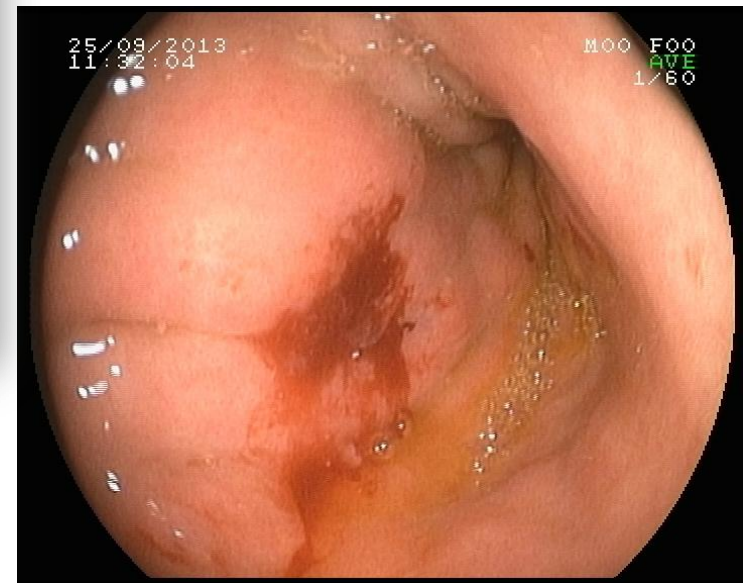
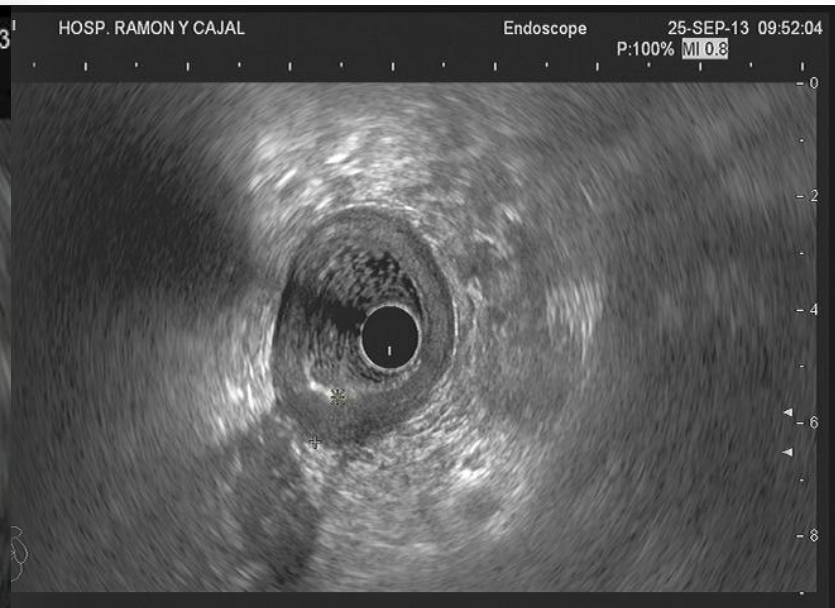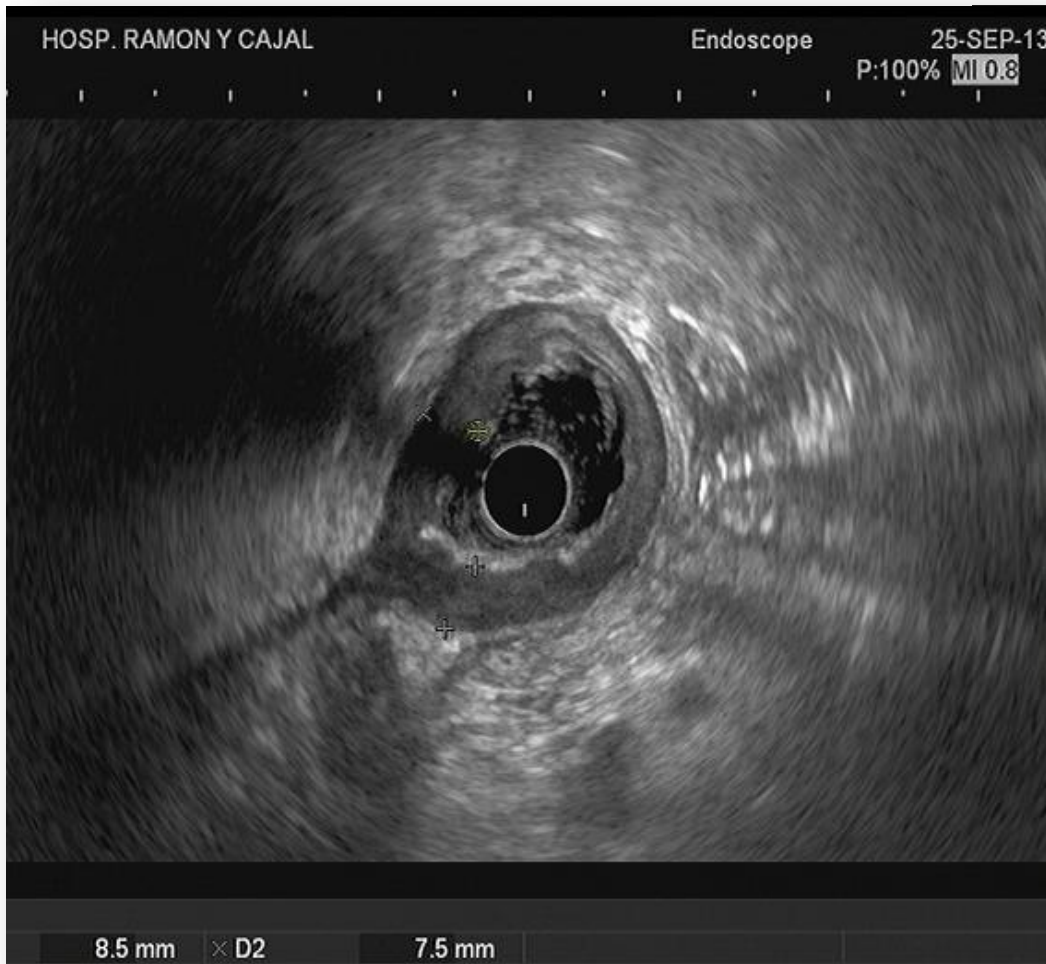ADENOCARCINOMA GÁSTRICO T4aN2



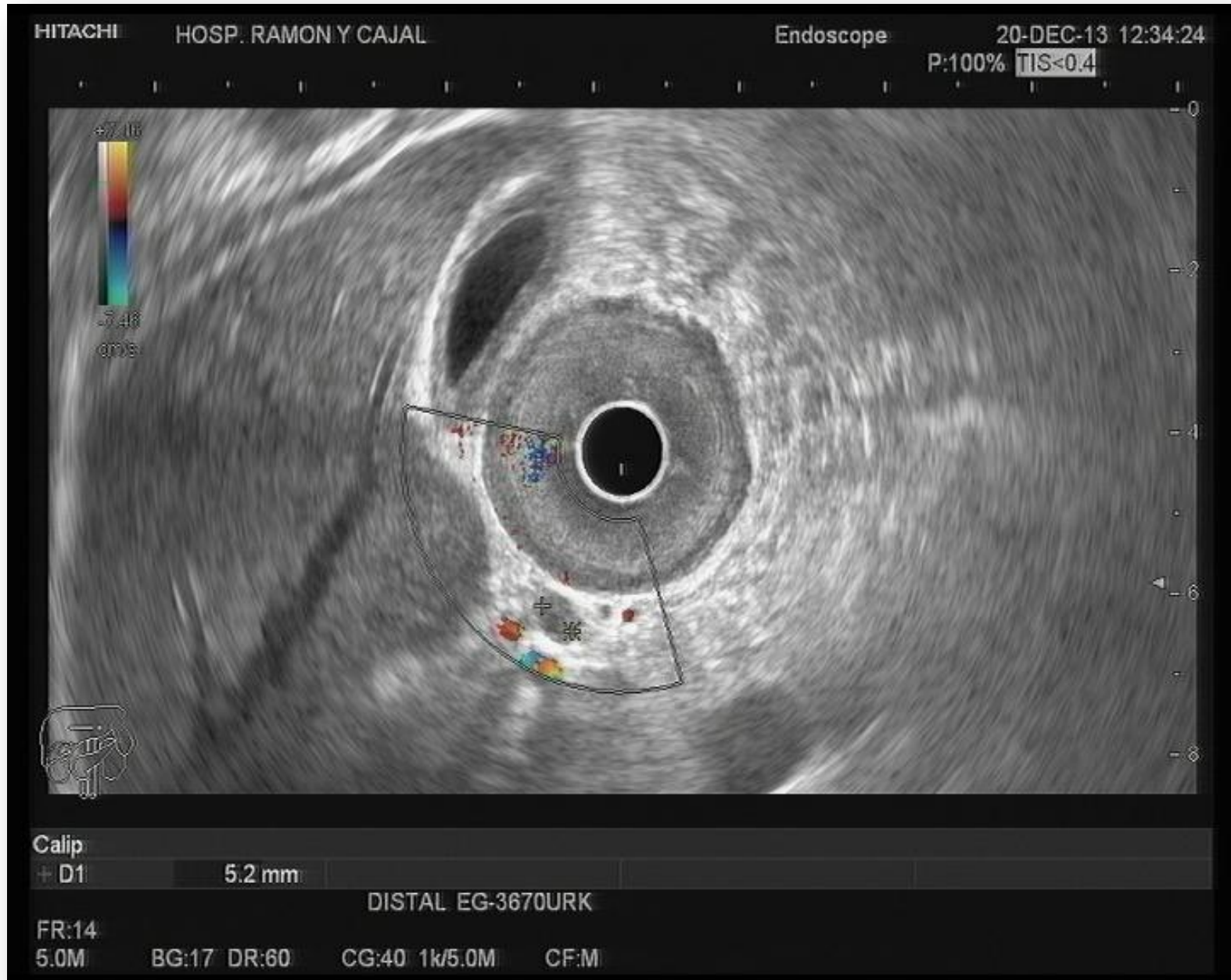ADENOCARCINOMA GÁSTRICO T2N0



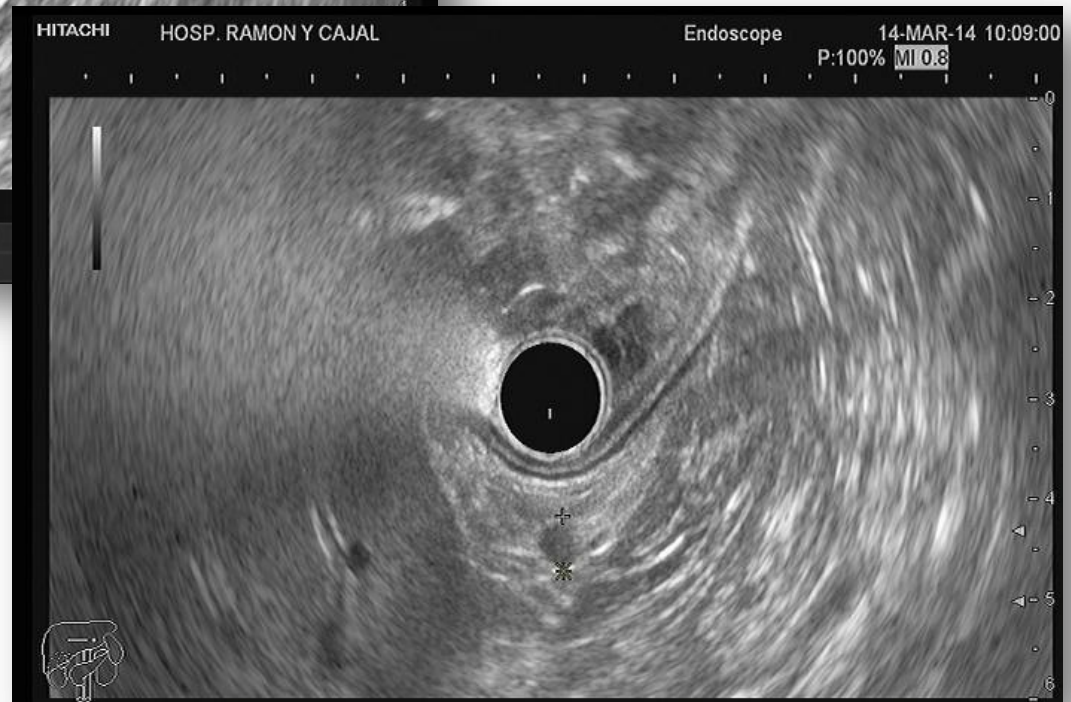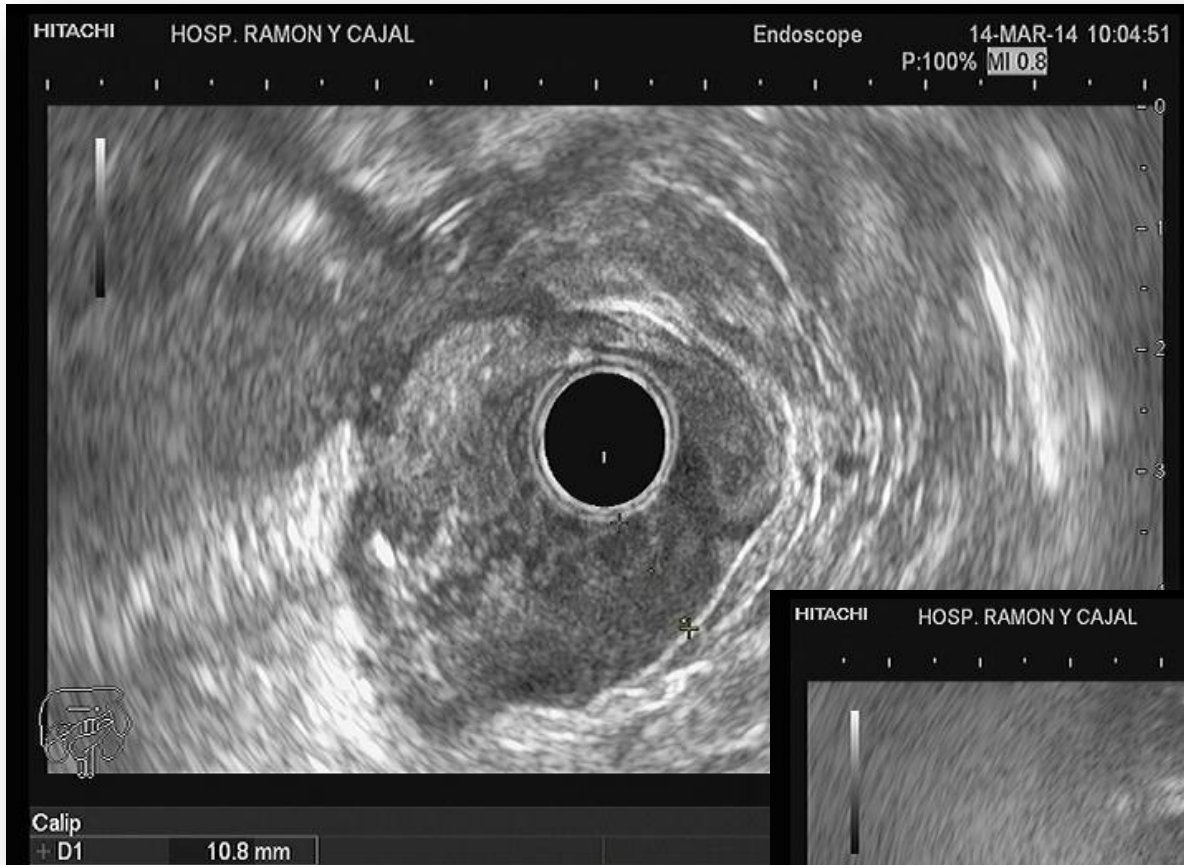LINITIS PLÁSTICA



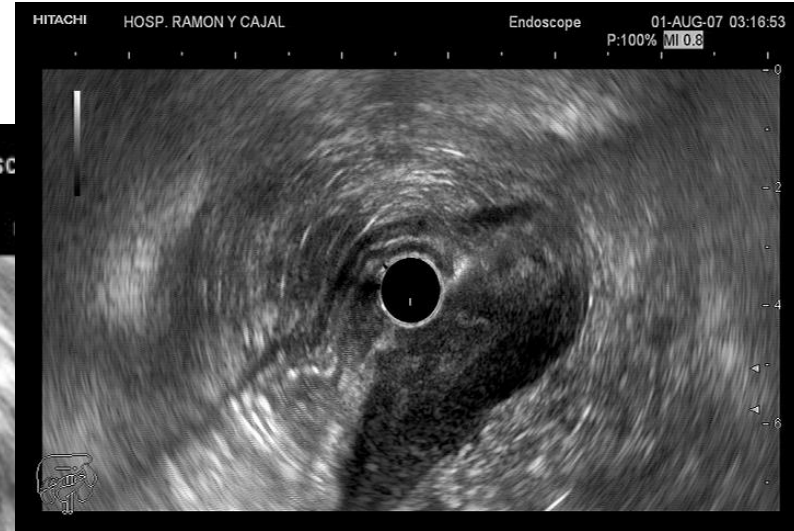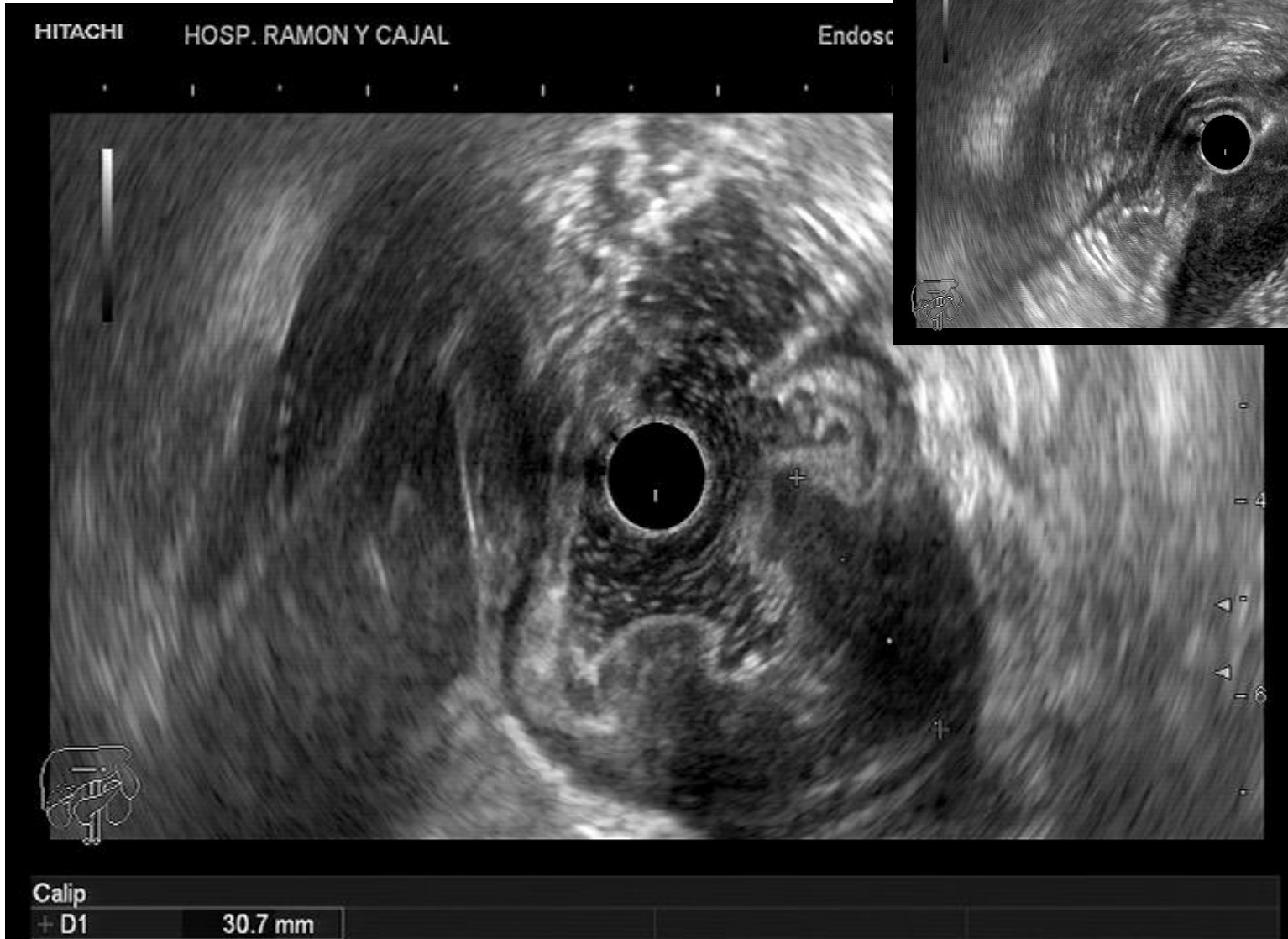
ADENOCARCINOMA GÁSTRICO T2N1



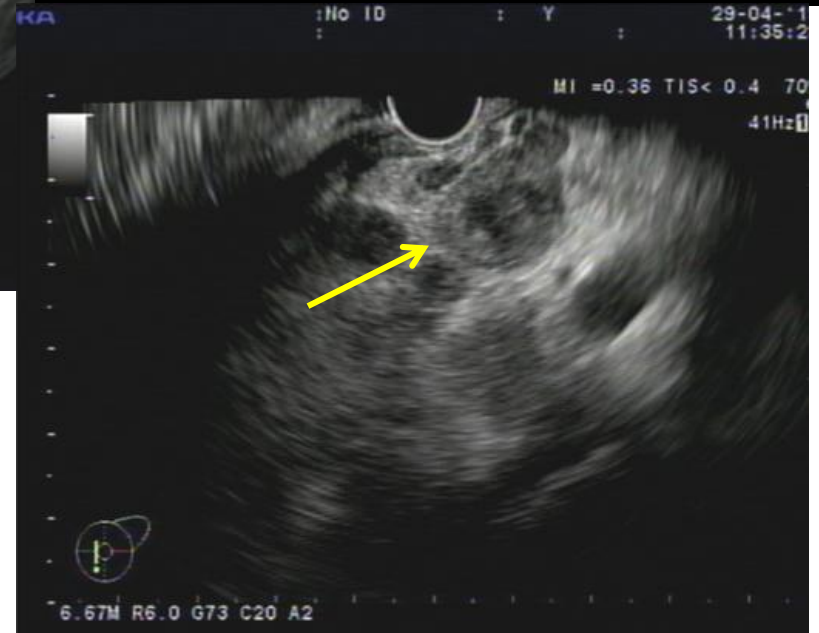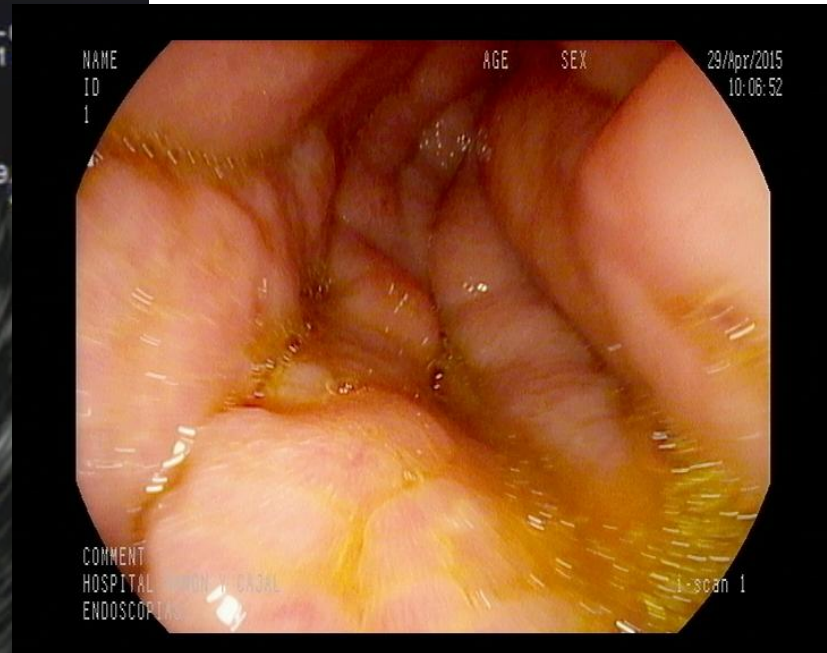
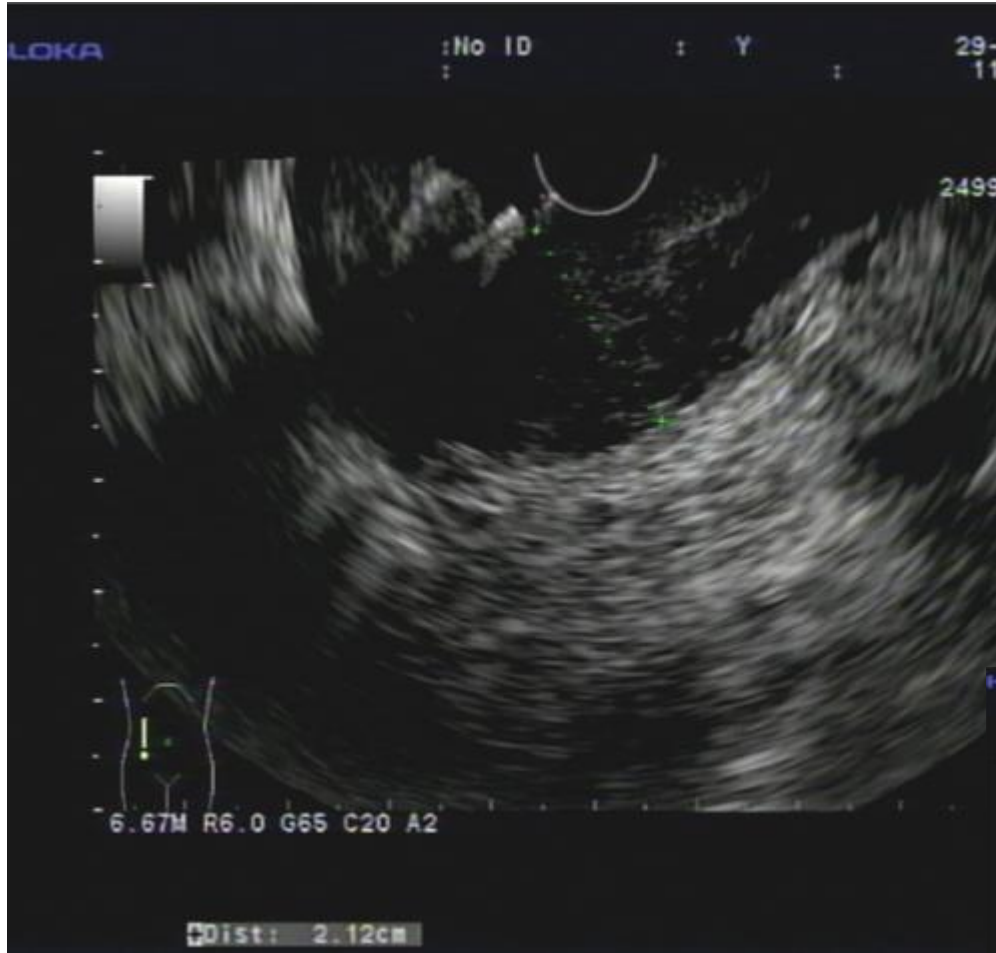ADENOCARCINOMA GÁSTRICO T4aN1



ADENOCARCINOMA GÁSTRICO T3N0

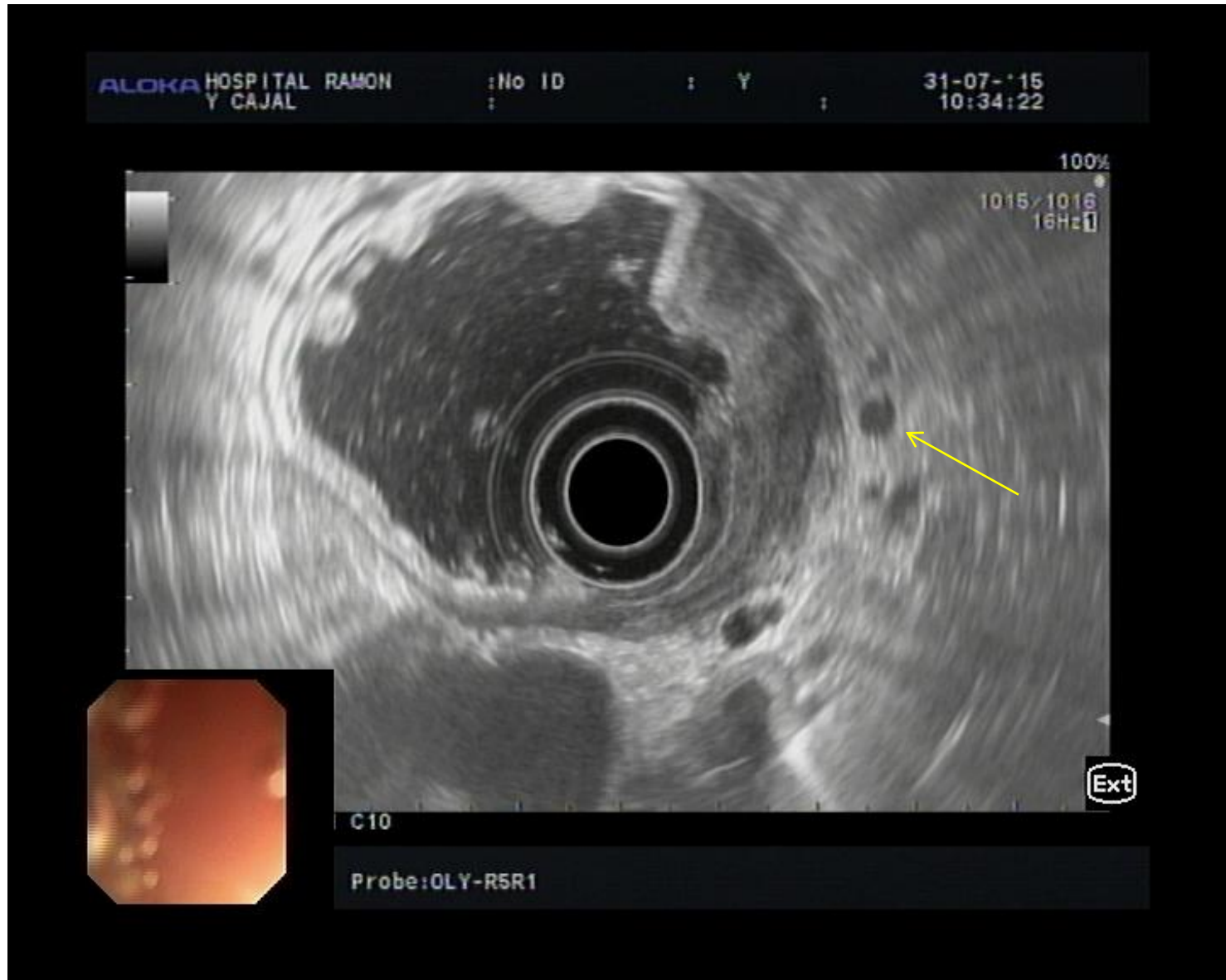


LINITIS PLÁSTICA (USE lineal)

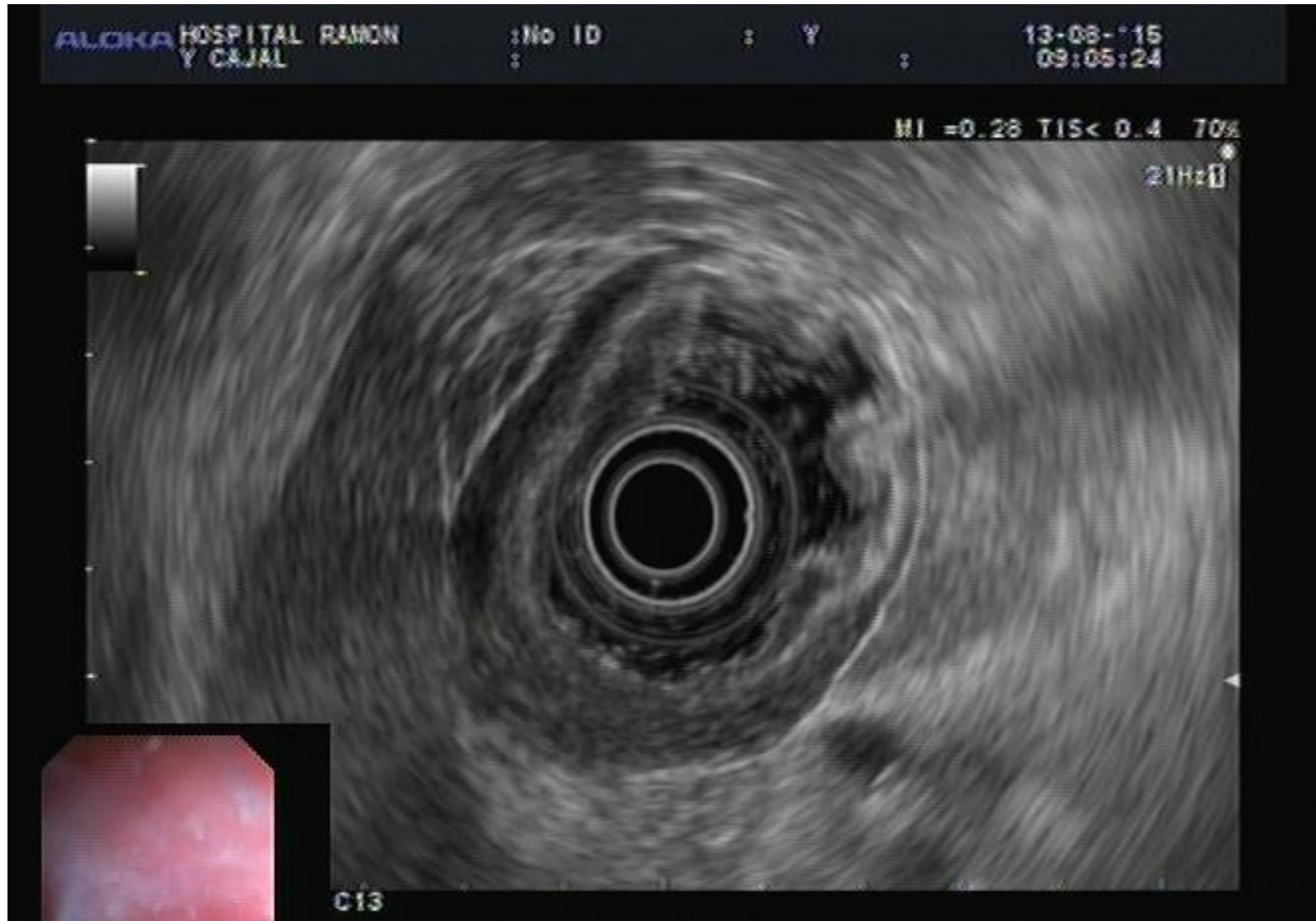

Adenopatía centro necrótico

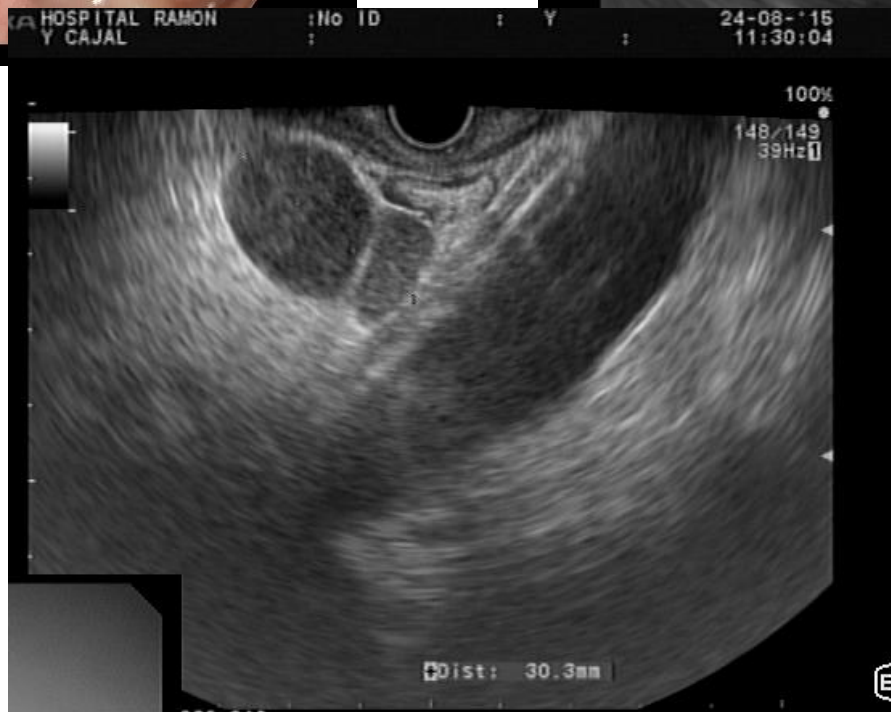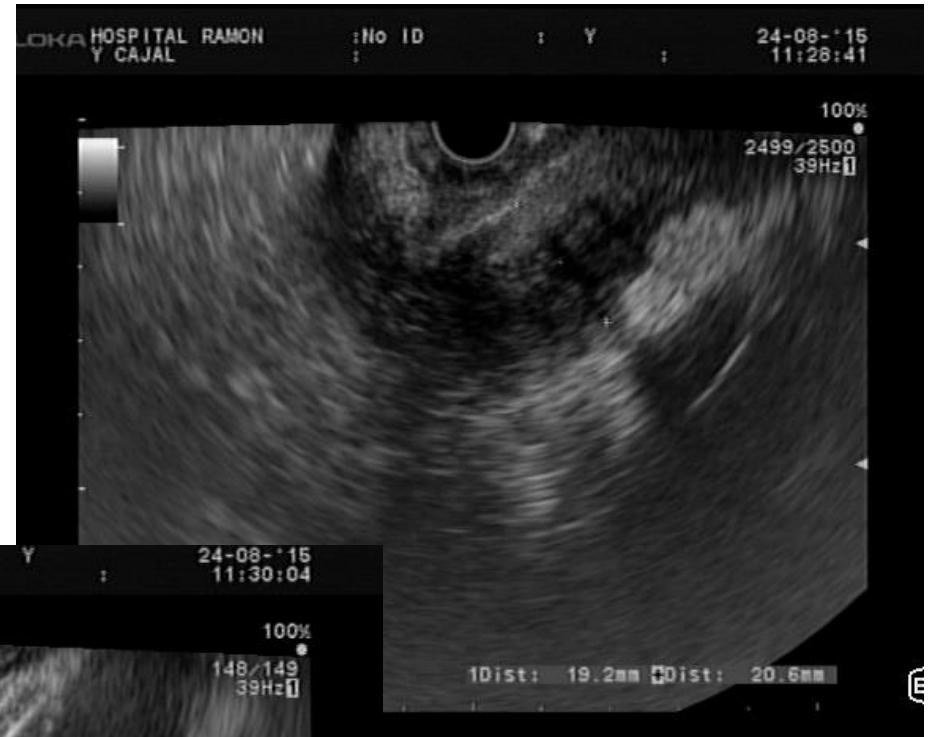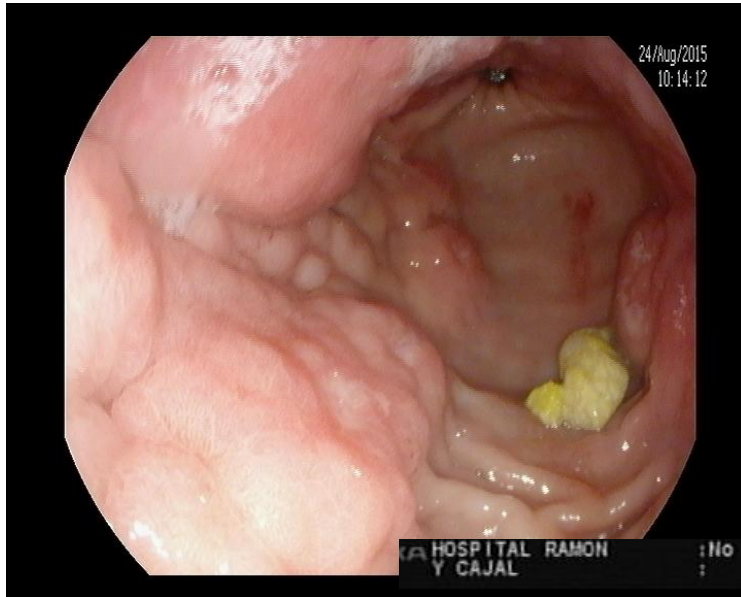
ADENOCARCINOMA GÁSTRICO T3N1



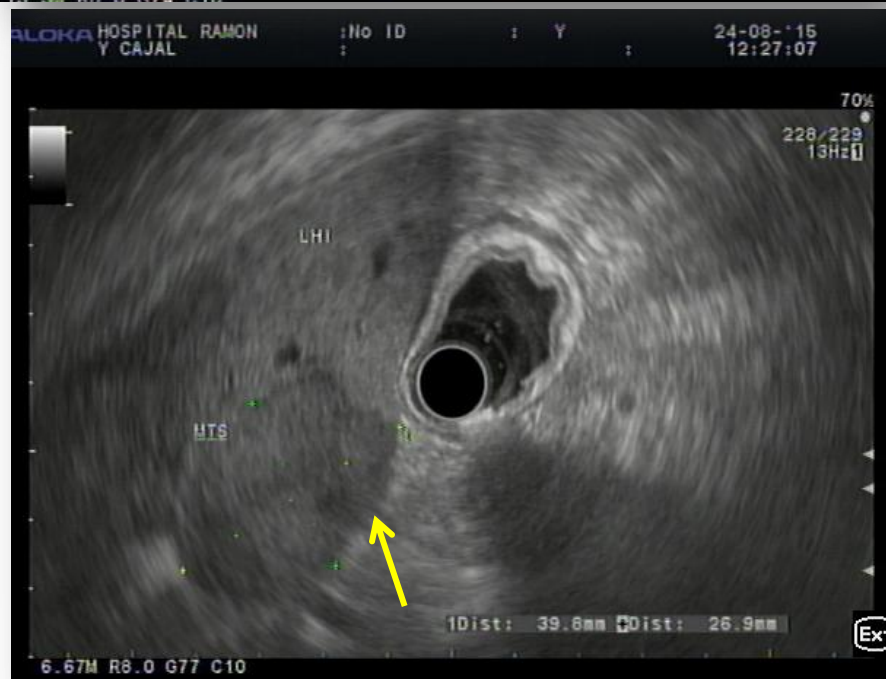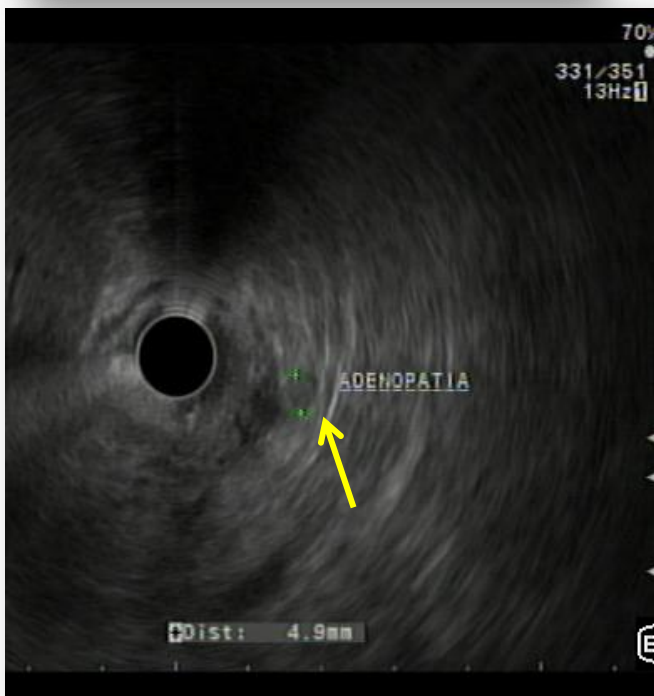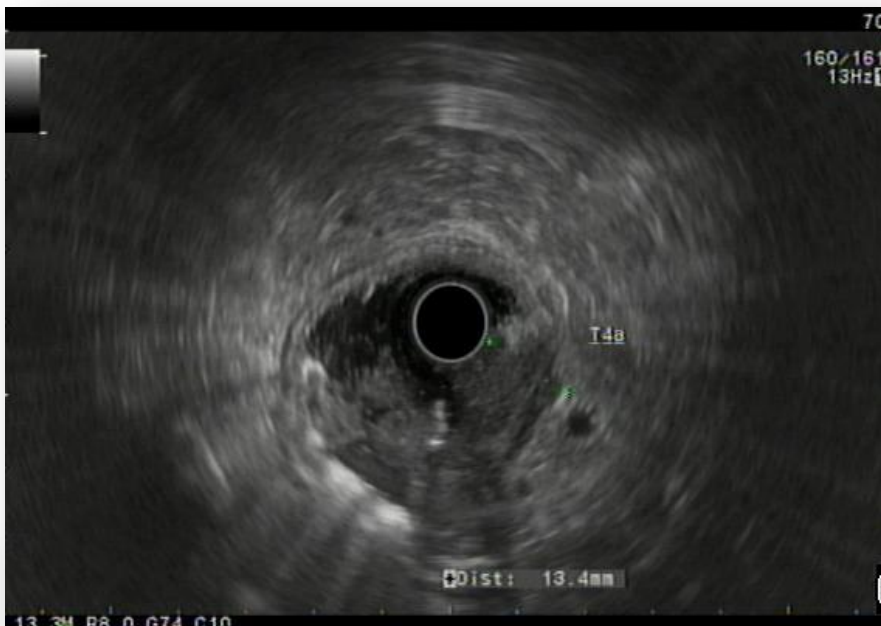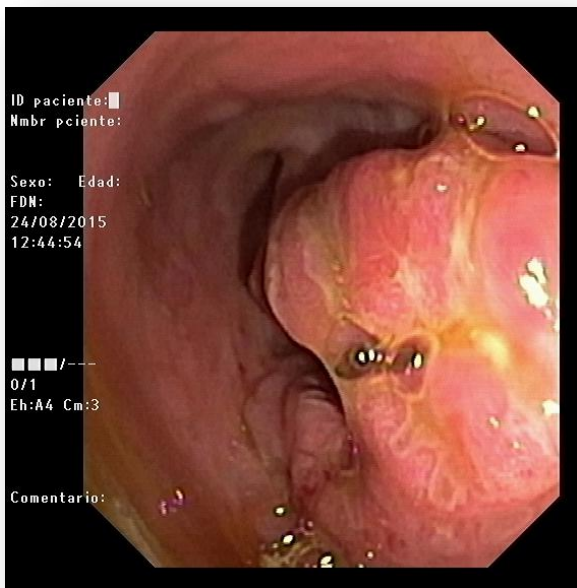
ADENOCARCINOMA GÁSTRICO T3N0



LINITIS PLÁSTICA (USE lineal)



ADENOCARCINOMA GÁSTRICO T4aN1M1



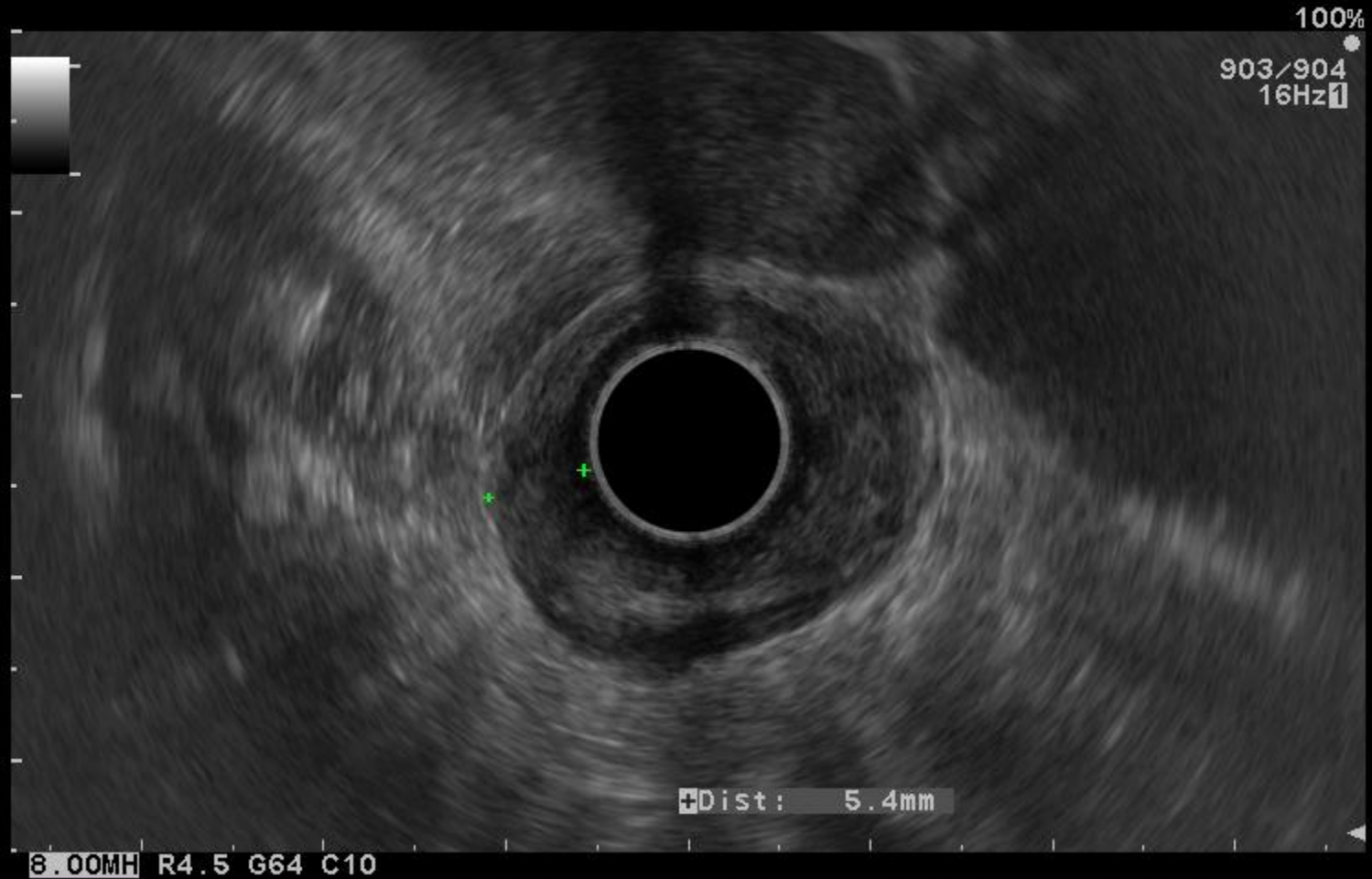ALOKA HOSPITAL RAMON Y CAJAL :No ID : Y : 24-08-'15 12:27:07

LINFOMA MALT ESTADIO IE2 (T2)

ALOKA HOSPITAL RAMON
Y CAJAL

: Y :

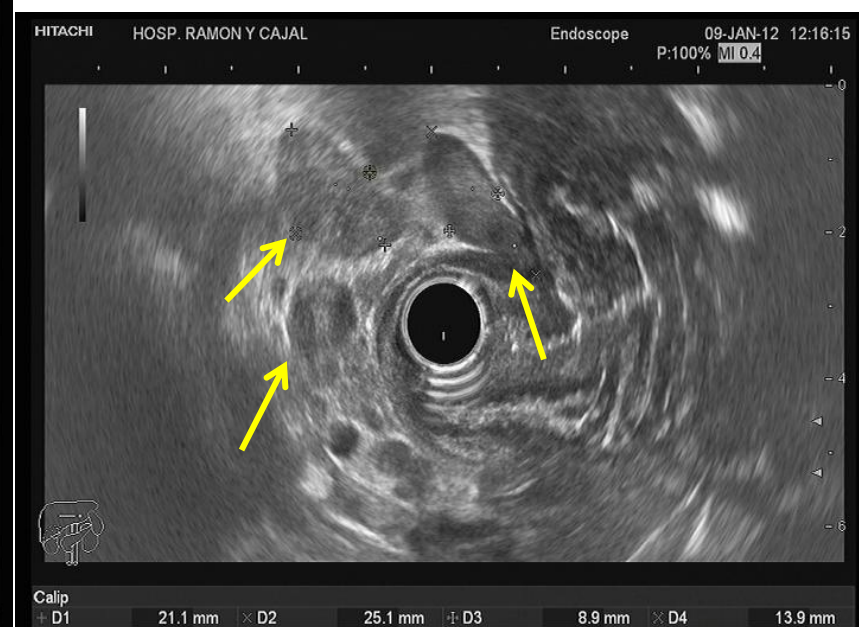
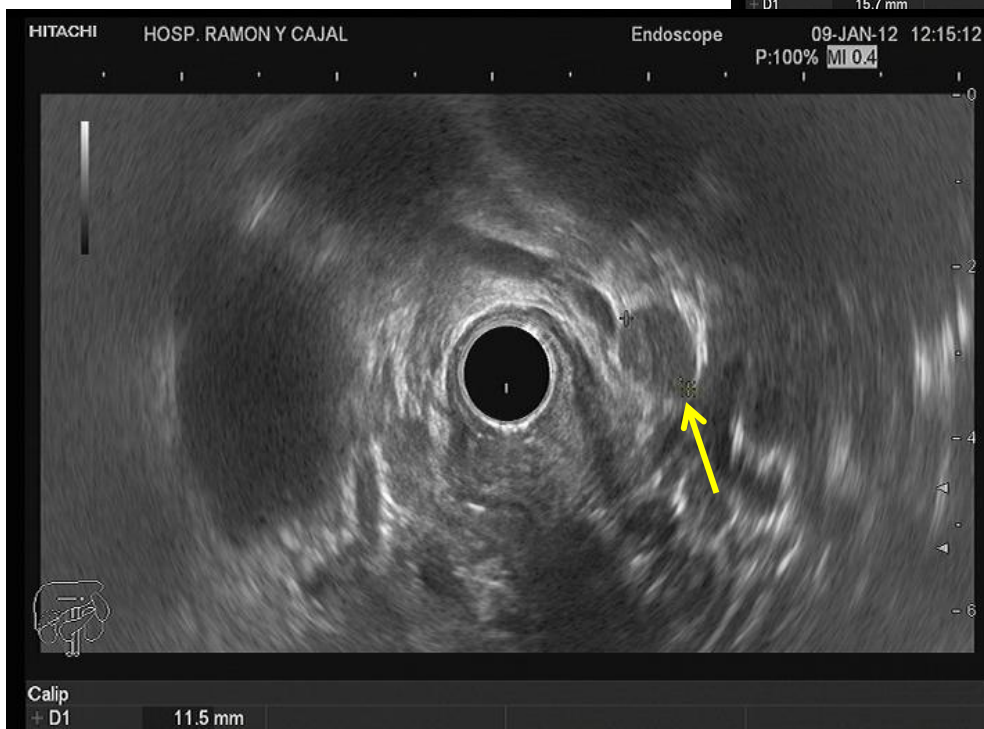
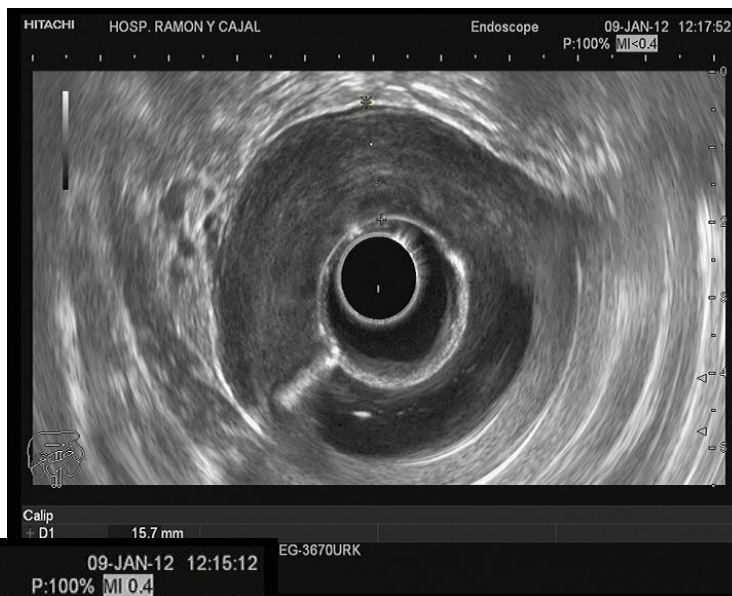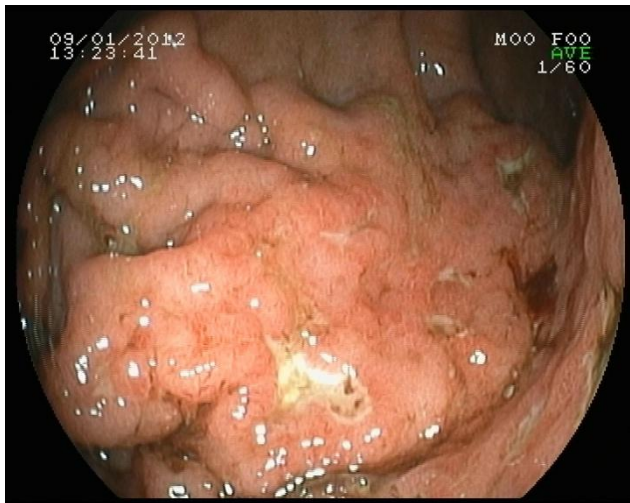23-09-15
09:37:04



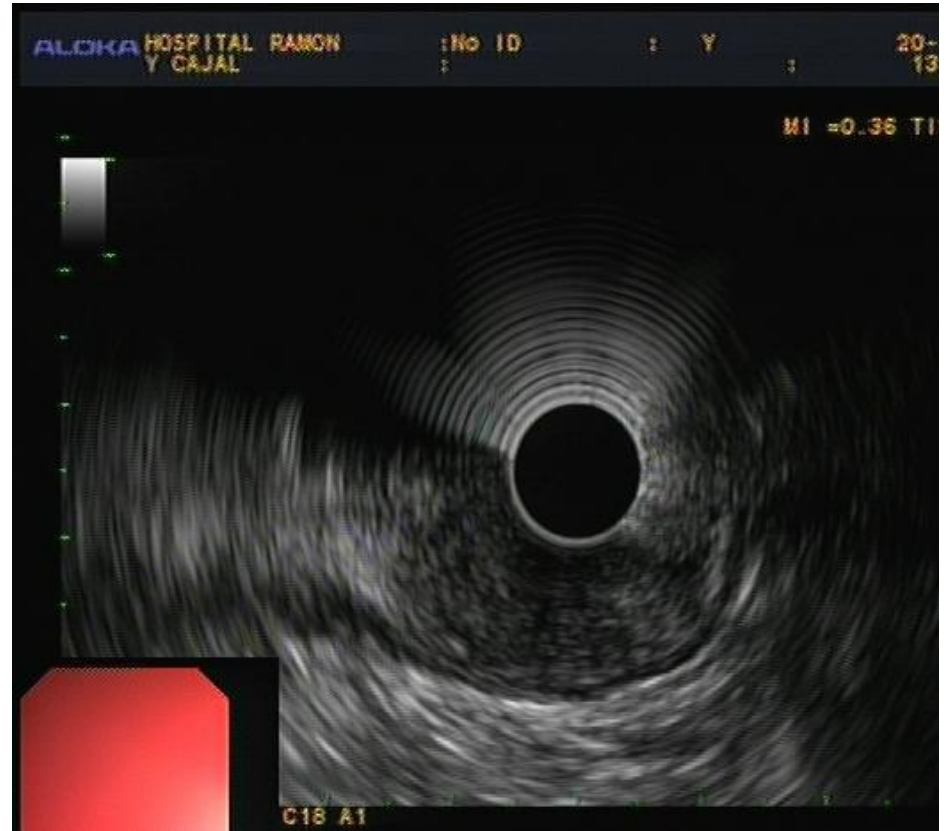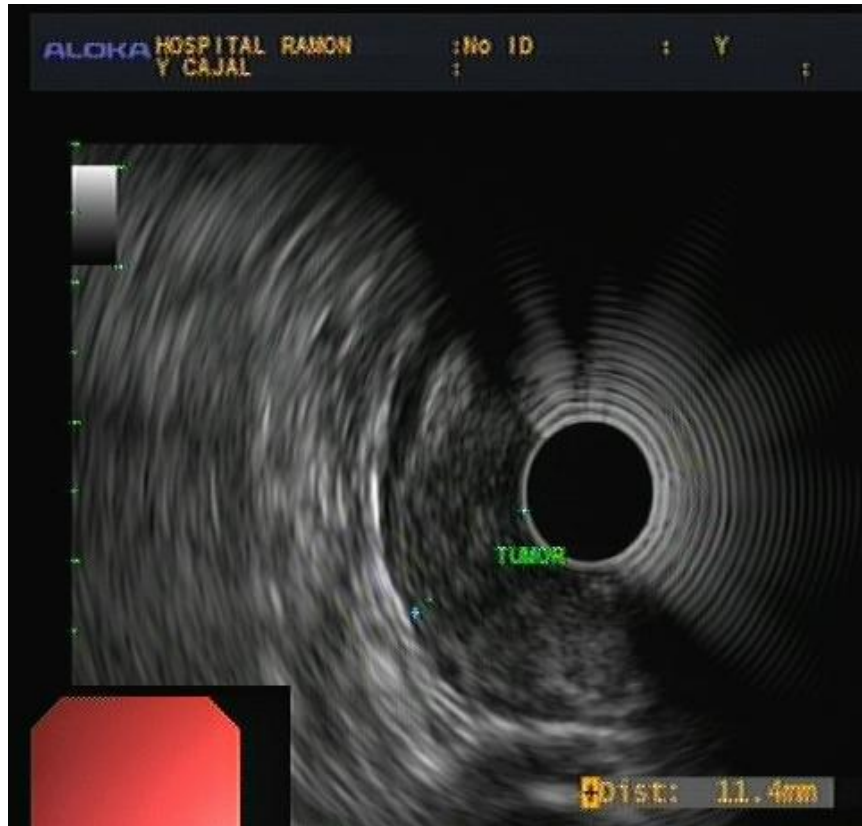2:RAD OLY 360

Probe:OLY-R5R1

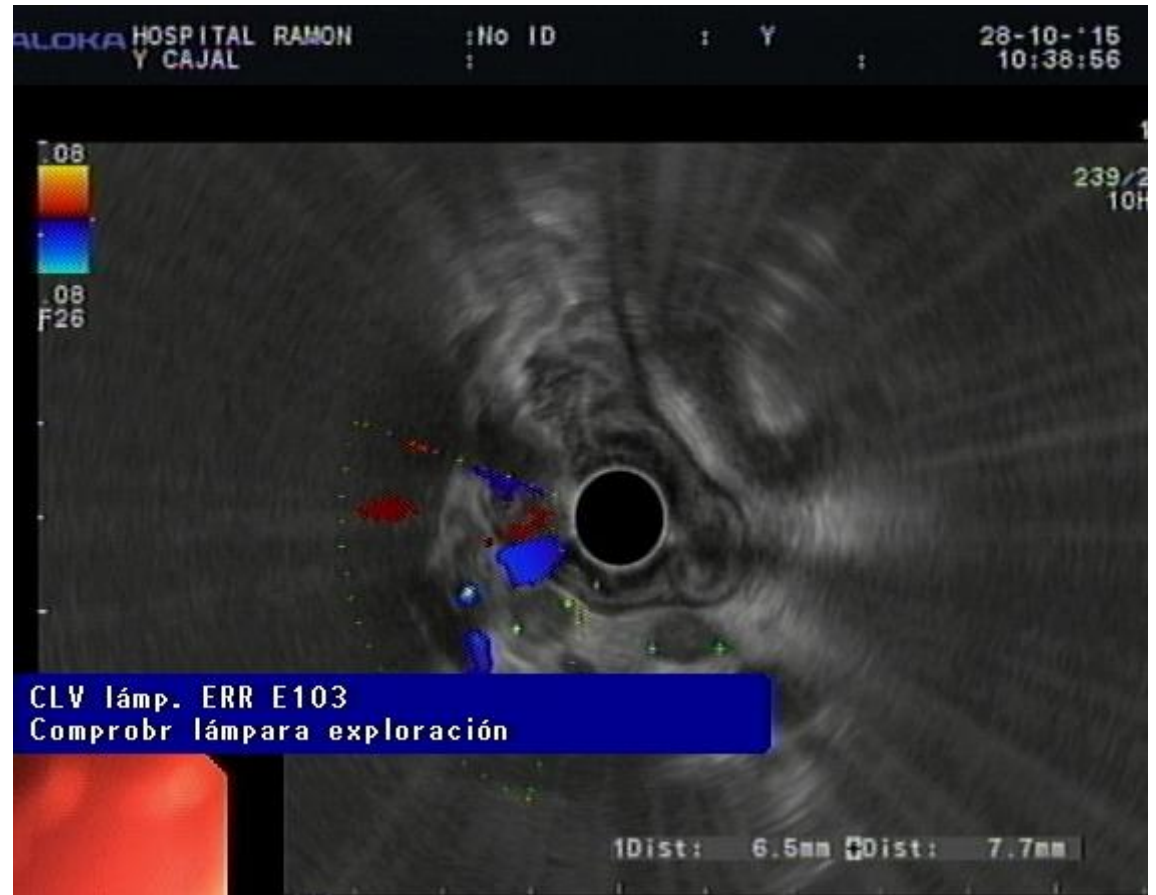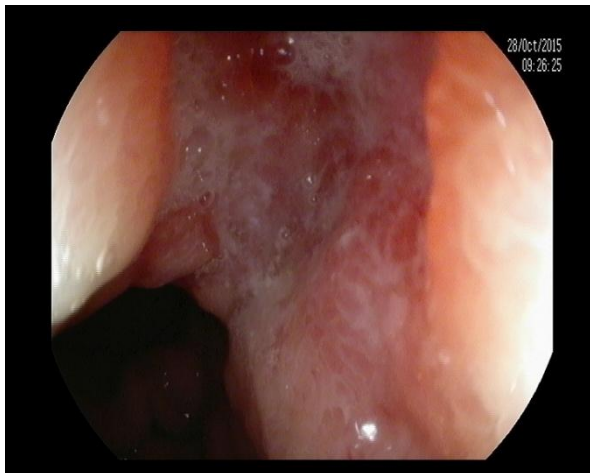
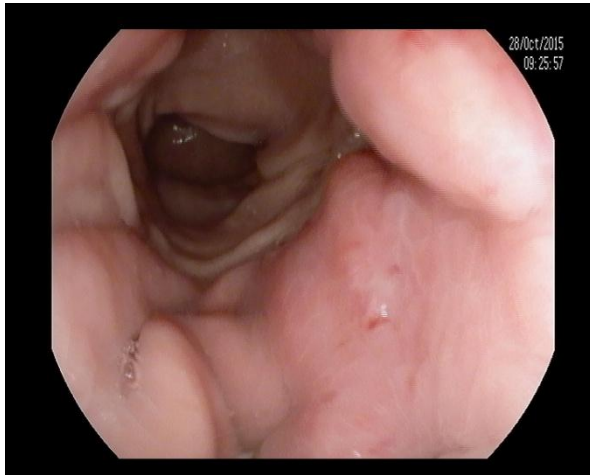LINFOMA MALT ESTADIO IIE



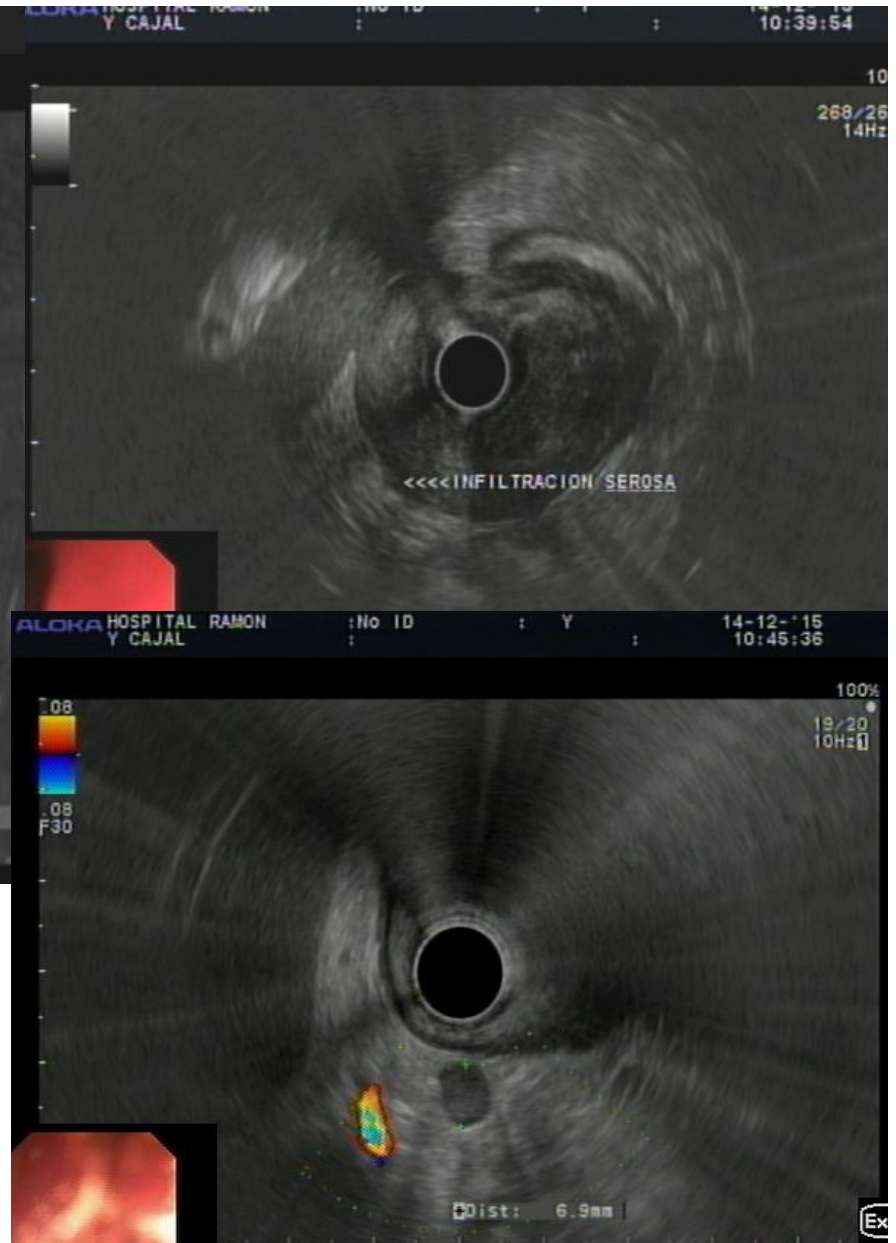
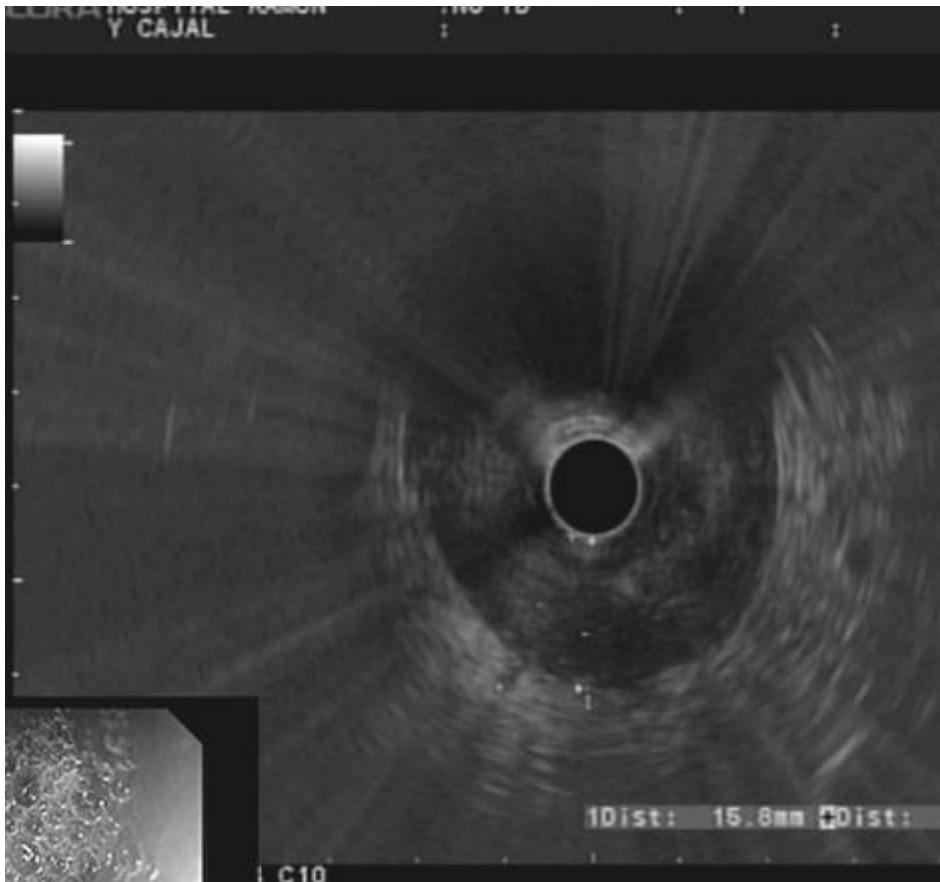ADENOCARCINOMA GÁSTRICO T2N0



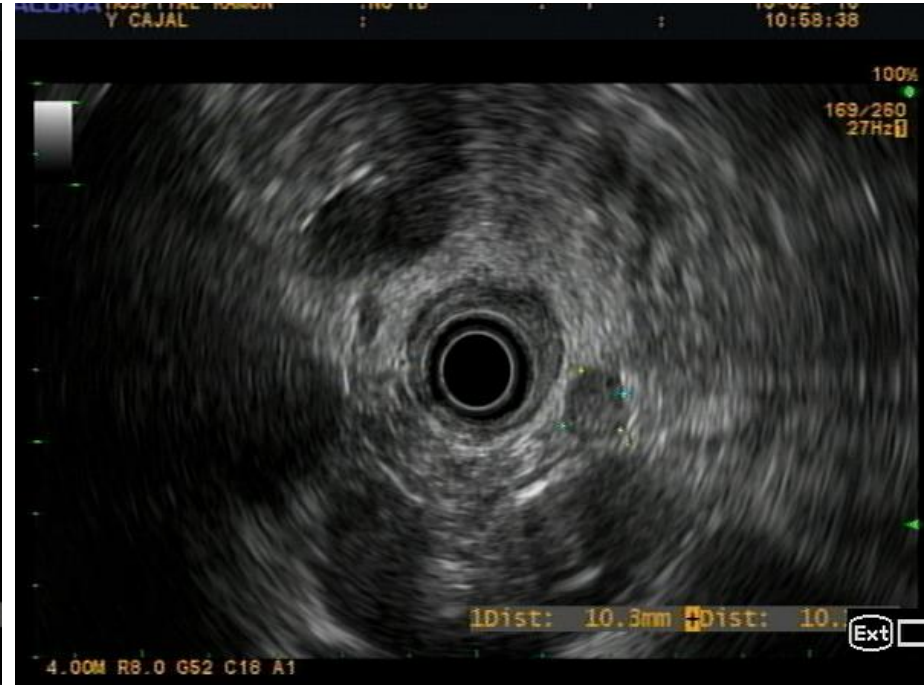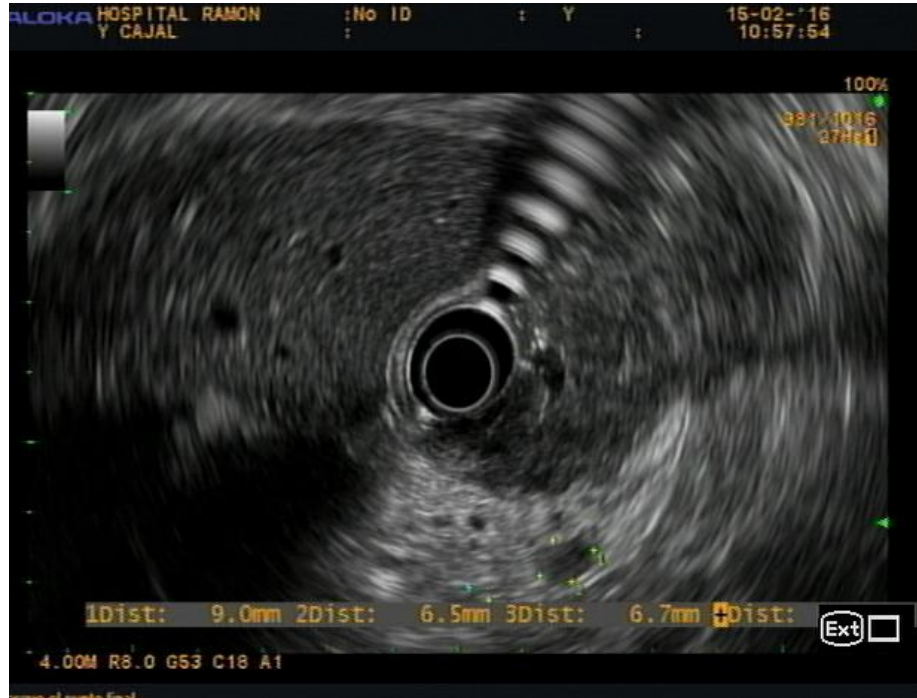LINITIS CON ADENOPATÍAS



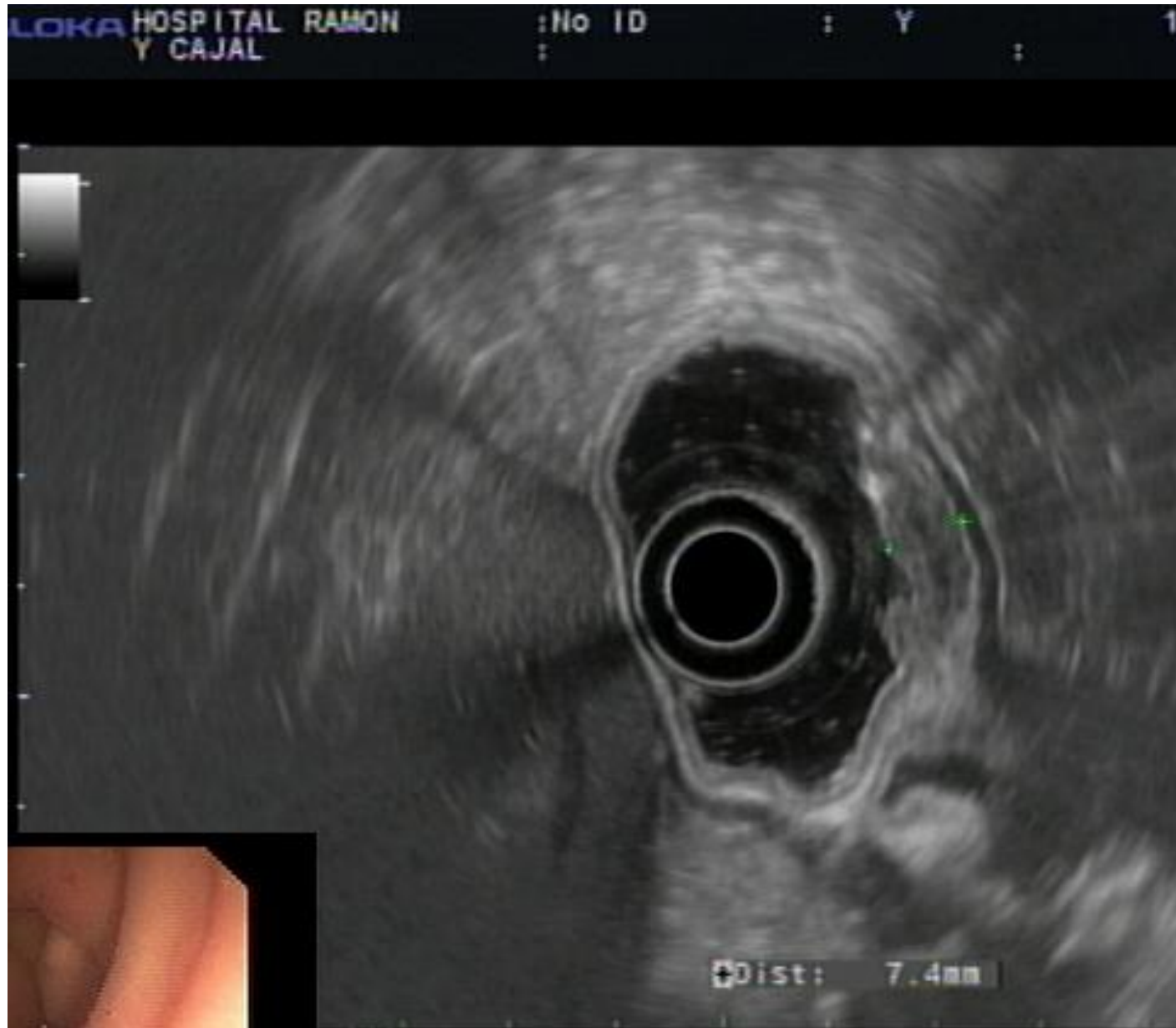ADENOCARCINOMA GÁSTRICO T3-4aN2



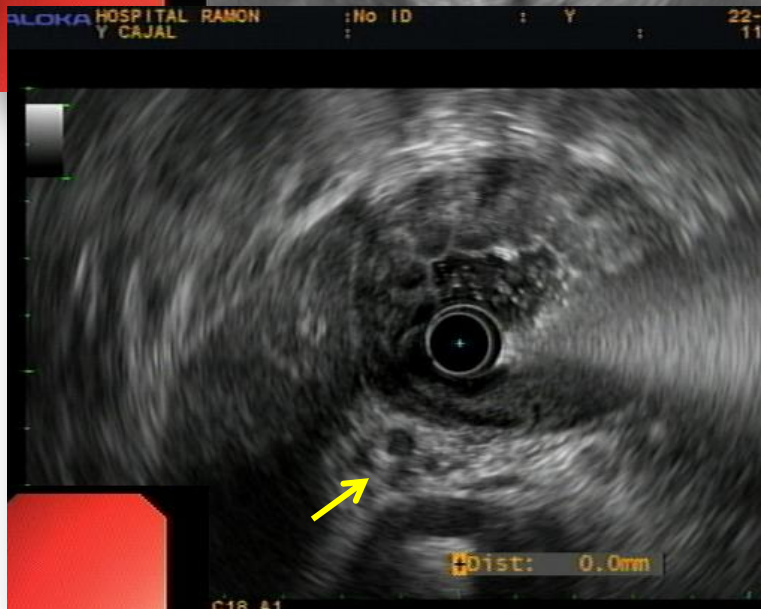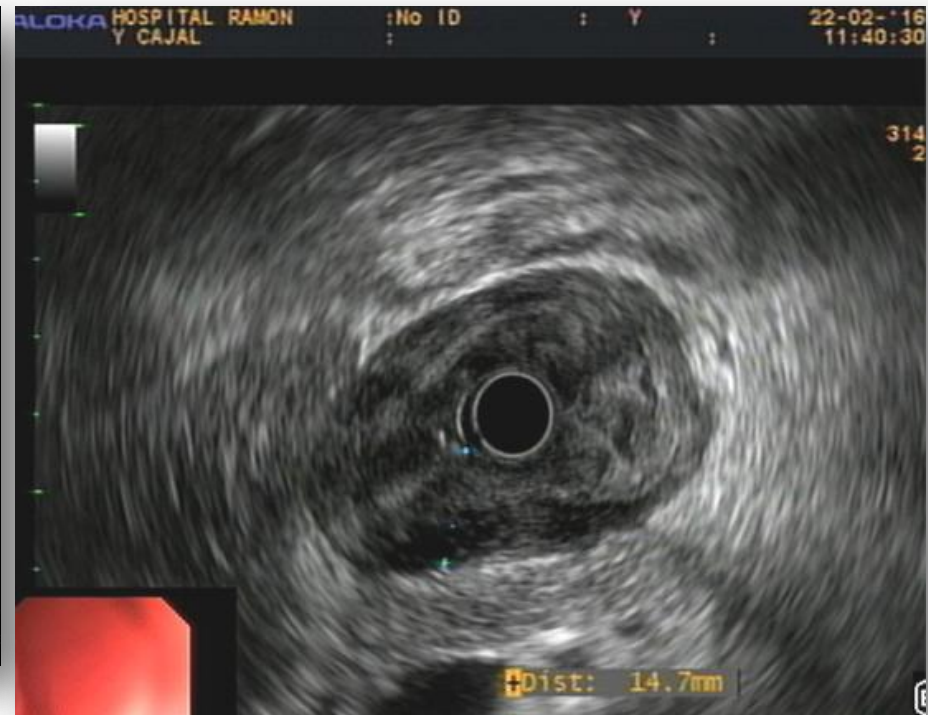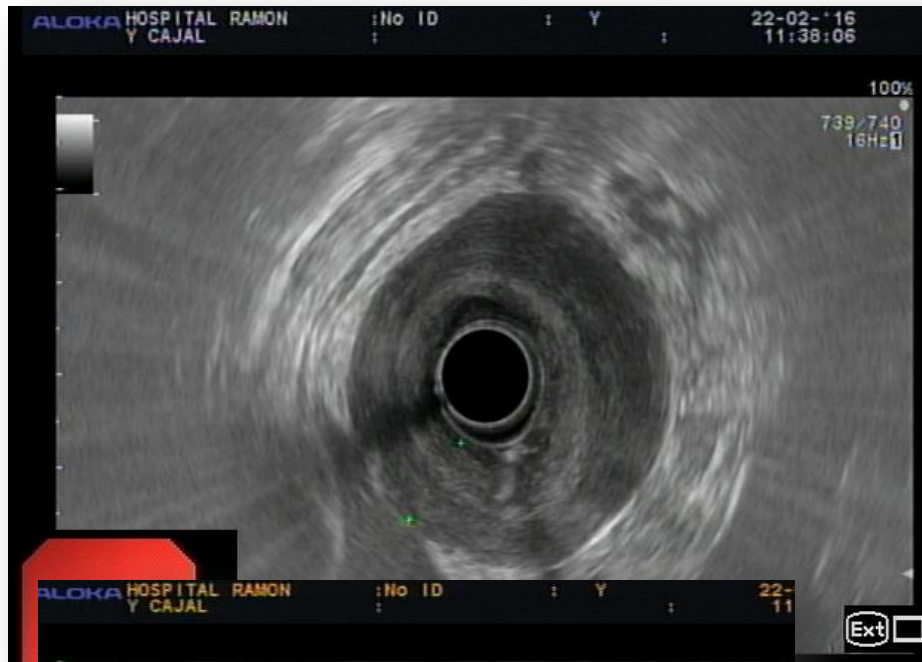ADENOCARCINOMA GÁSTRICO T4aN2



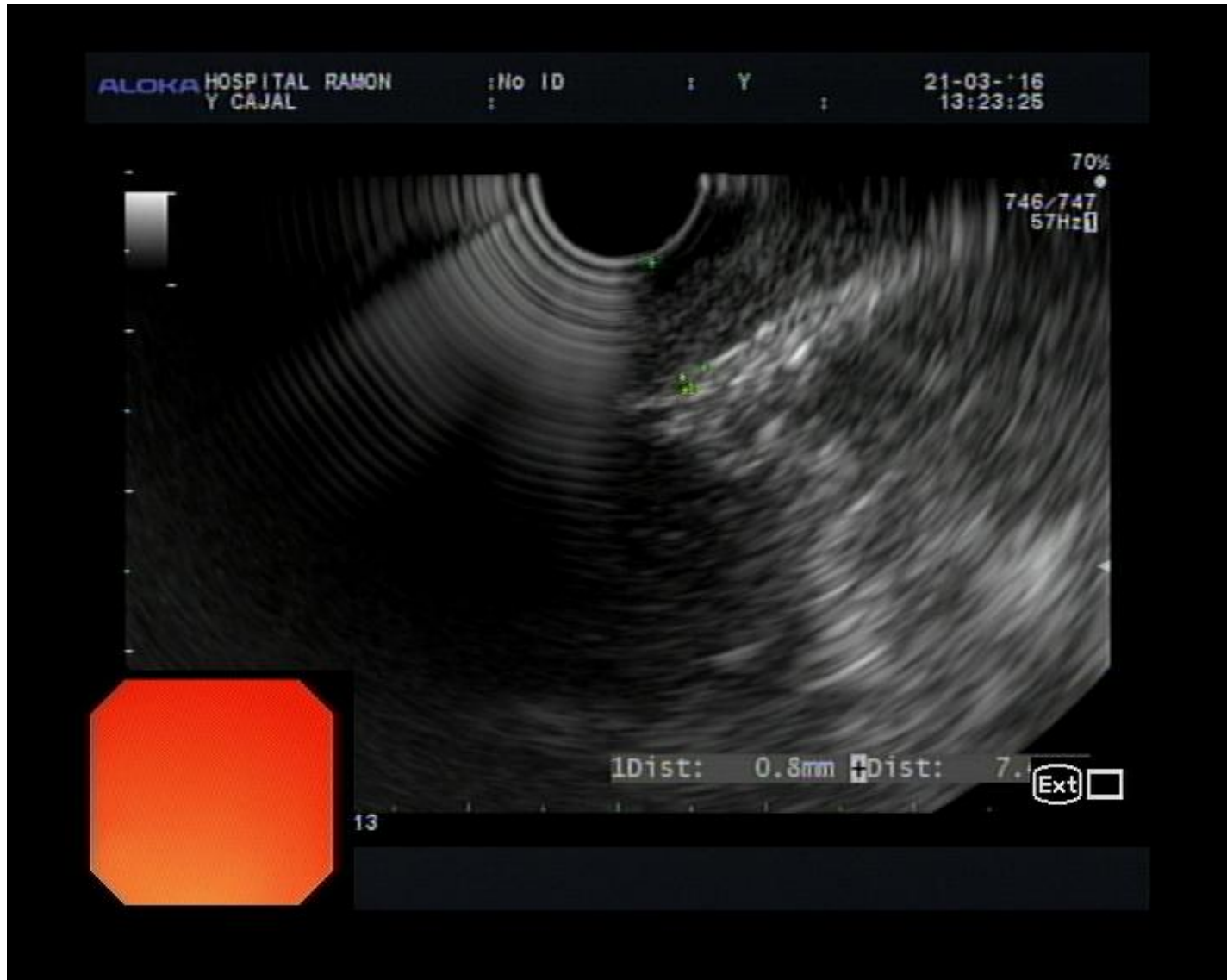
ADENOCARCINOMA GÁSTRICO T1bN0



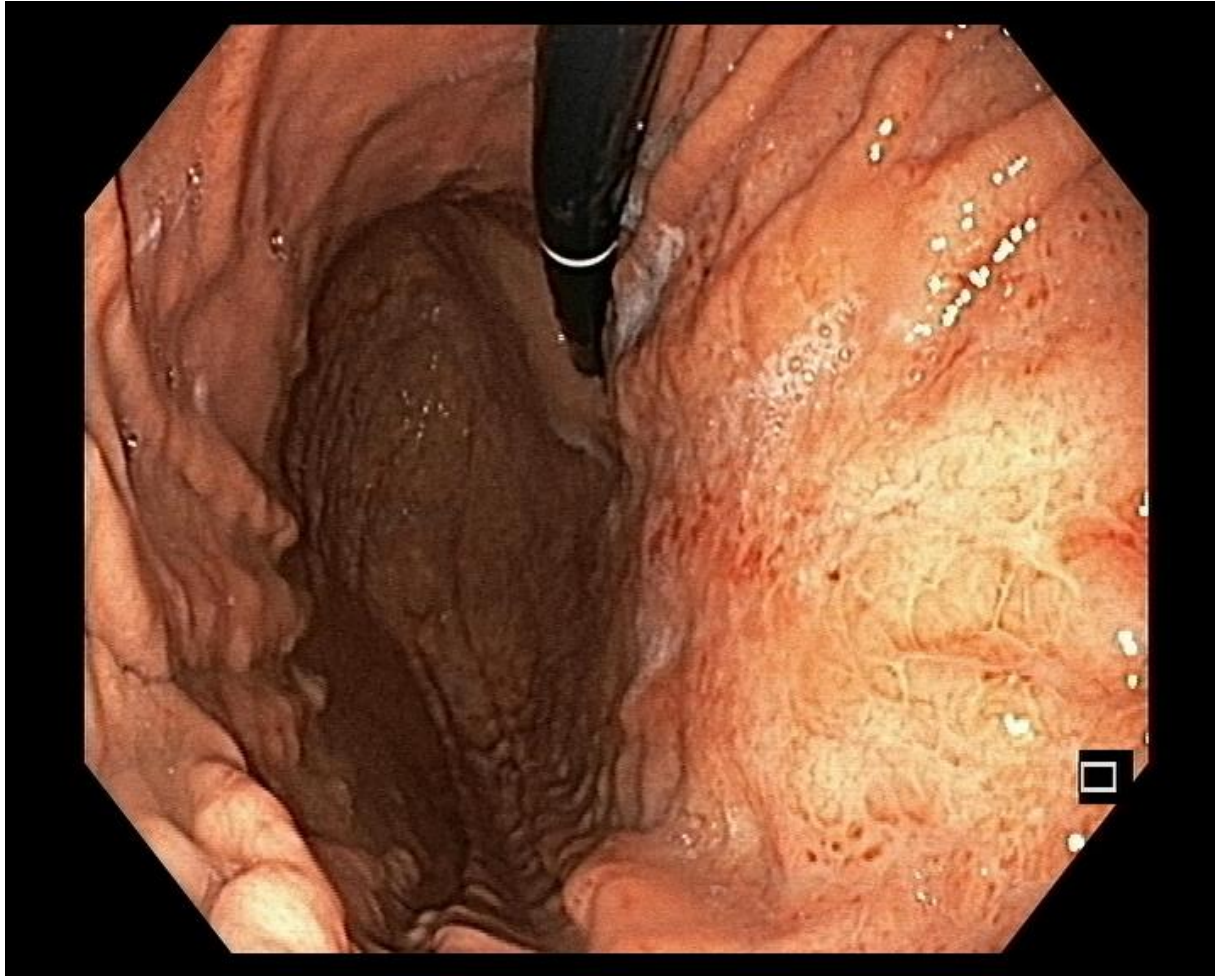ADENOCARCINOMA GÁSTRICO T3N2



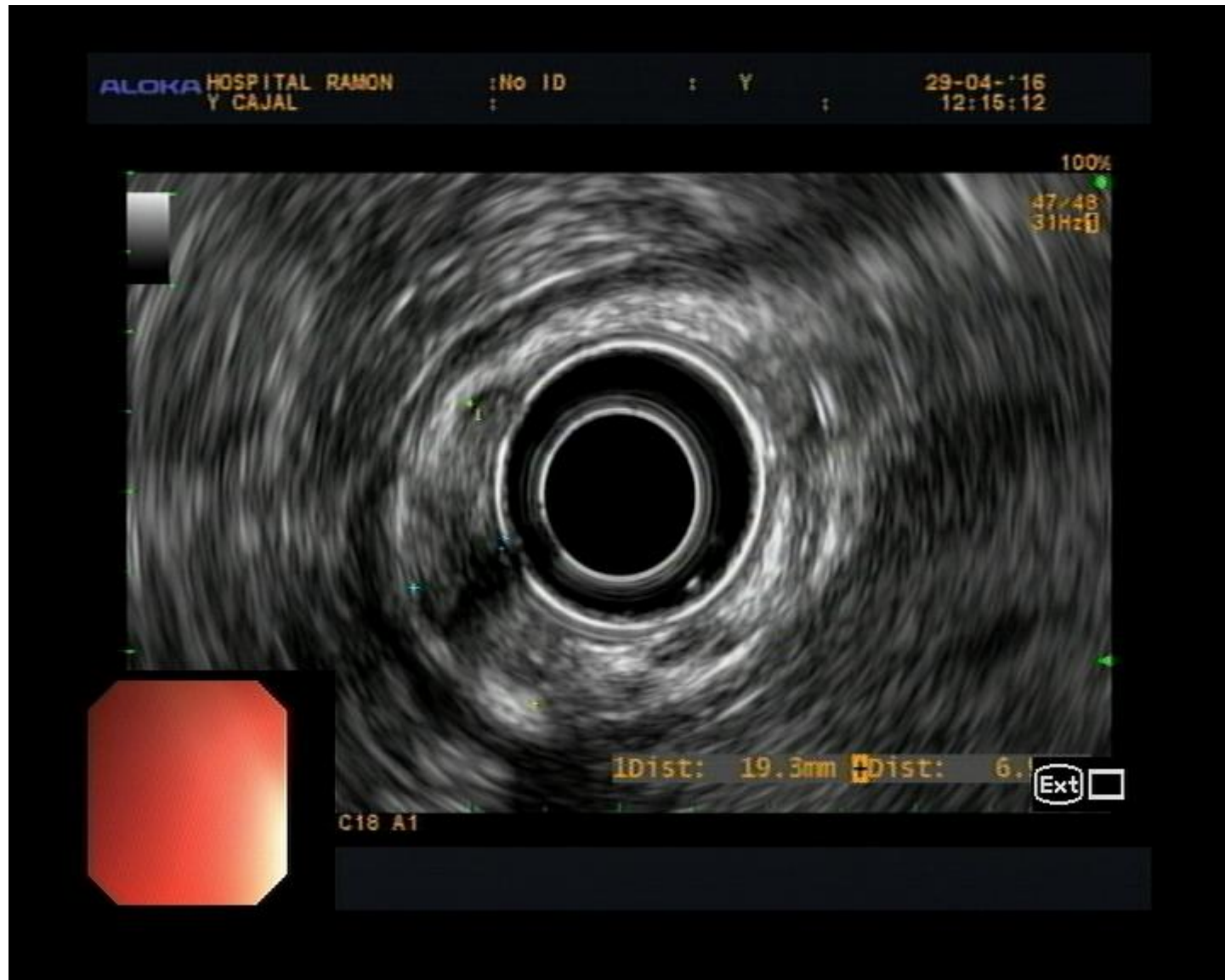ADENOCARCINOMA GÁSTRICO T3 (USE lineal)



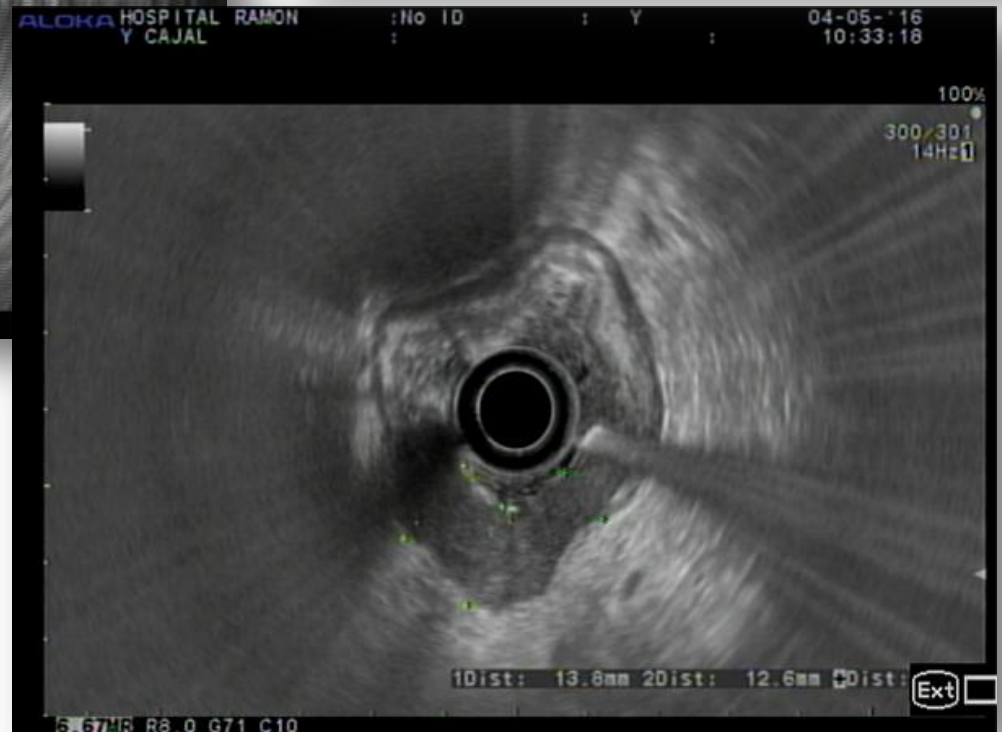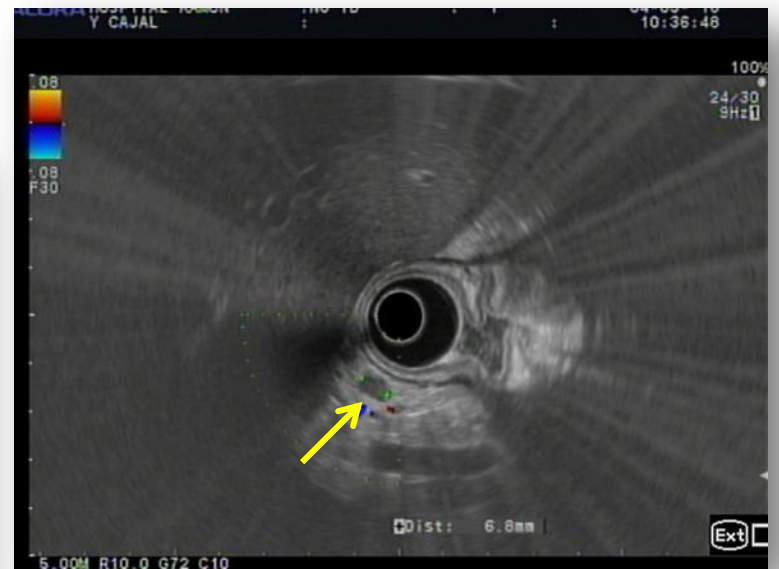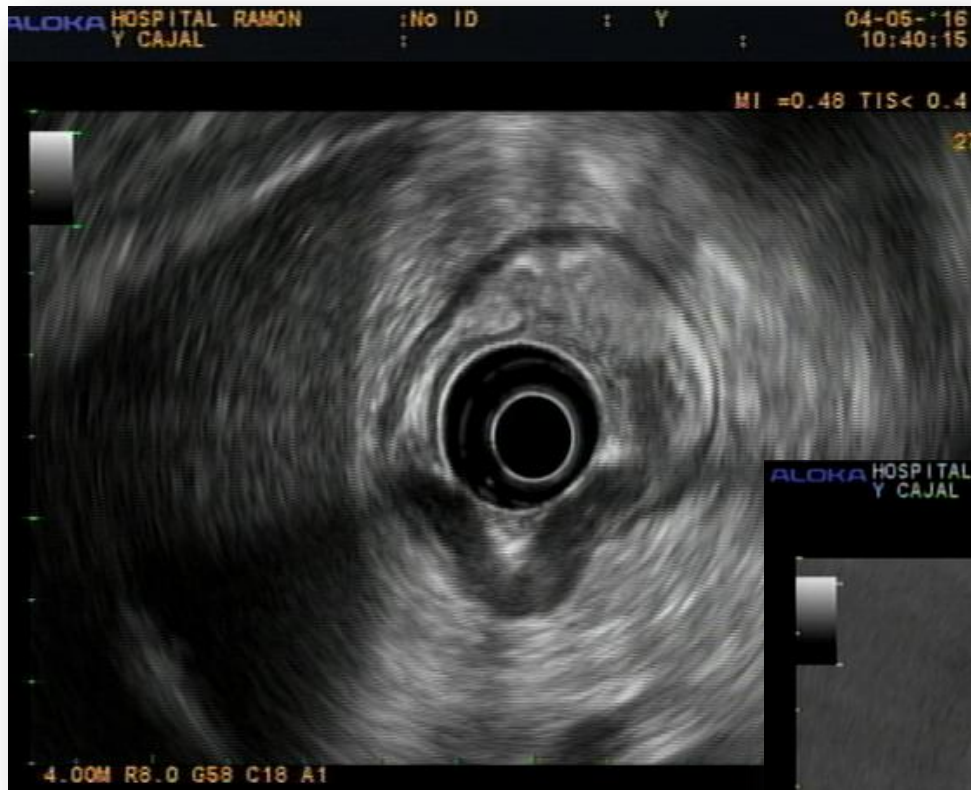LINFOMA MALT CURVATURA MENOR



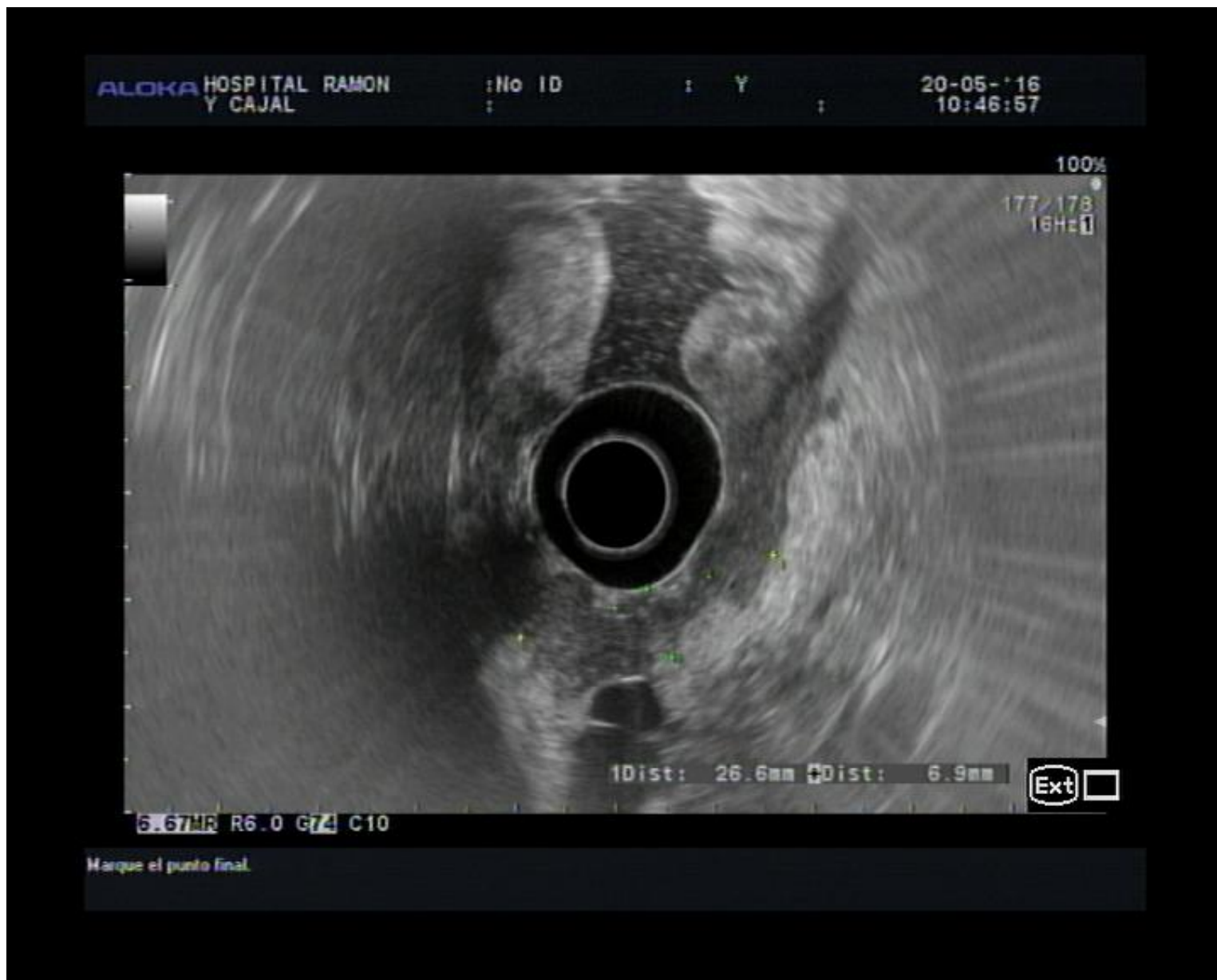ADENOCARCINOMA GÁSTRICO T3



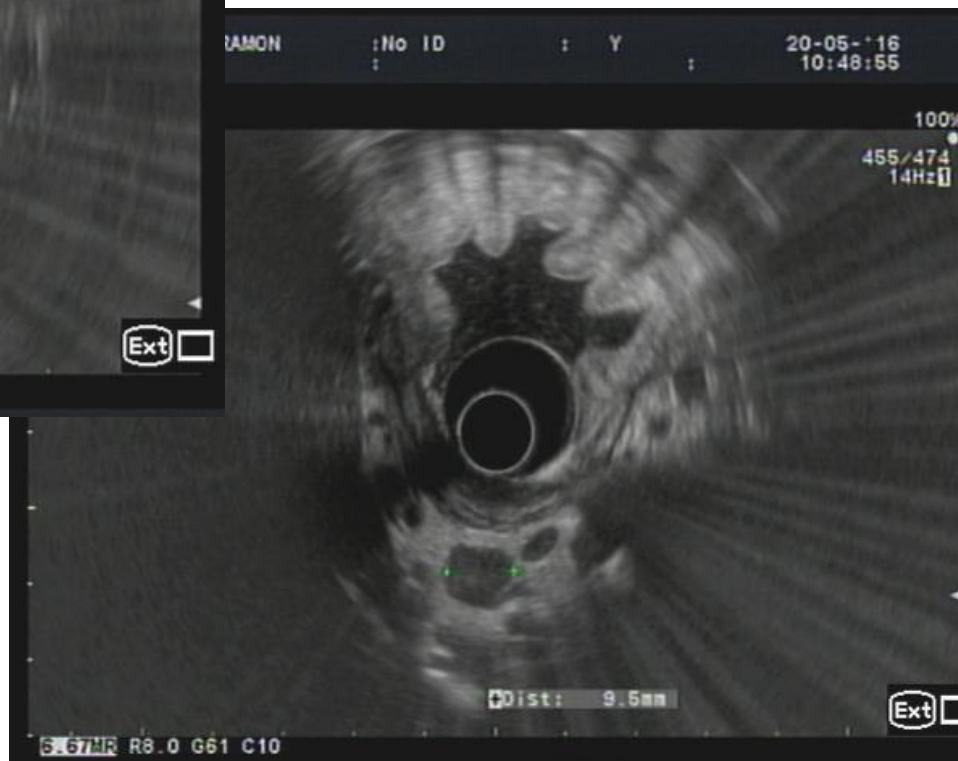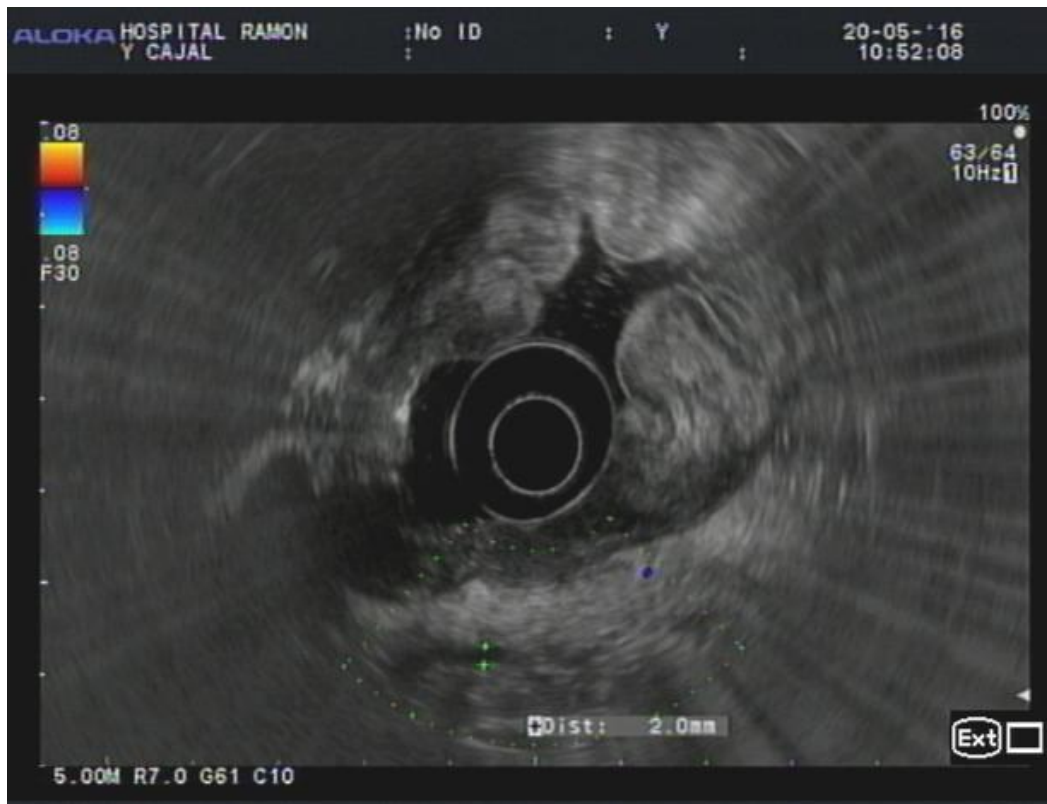ADENOCARCINOMA T4aN1



ADENOCARCINOMA T4 b(infiltración pancreática)N2



ADENOCARCINOMA T4 b(infiltración pancreática)N2



LINFOMA MALT

