

Endoscopic ultrasound-guided transesophageal drainage of a mediastinal pancreatic pseudocyst using a novel lumen-apposing metal stent

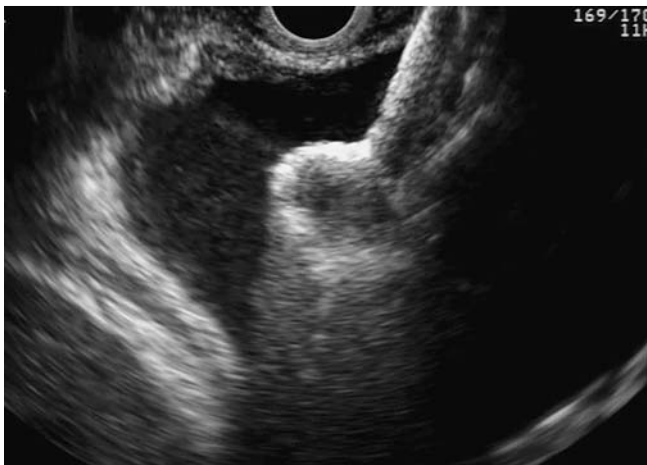

Fig. 1 View during endoscopic ultrasound (EUS)-guided placement of a lumen-apposing metal AXIOS stent across the cystoesophagostomy.

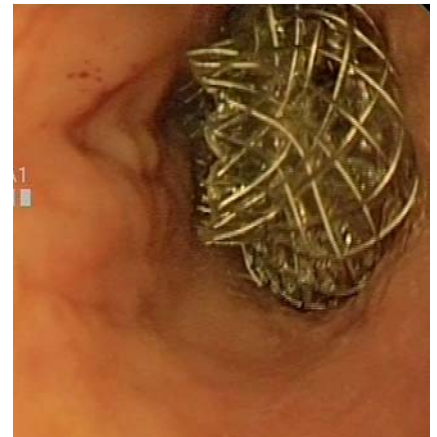


Fig. 2 Endoscopic view of the intraluminal end of the stent within the lower esophagus.

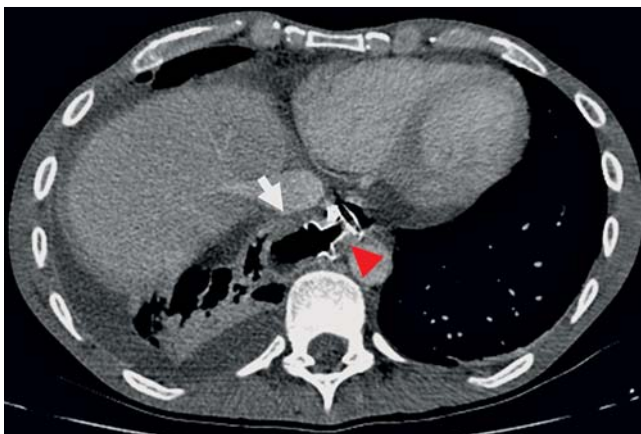

Fig. 3 Follow-up computed tomography (CT) scan after 7 days showing the AXIOS stent (arrowhead) still in place with significant resolution of the lesion (arrow).

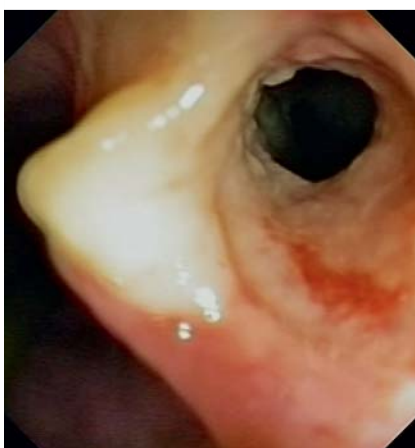

Fig. 4 Endoscopic view of the cystoesophagostomy after the stent had been removed.

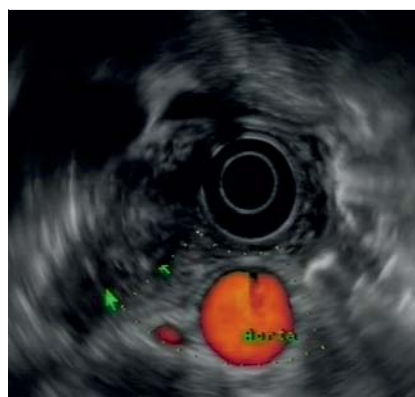

Fig. 5 Follow-up endoscopic ultrasound (EUS) image 6 weeks later showing complete resolution of the lesion.

There have been a few previous reports of transesophageal endoscopic ultrasound (EUS)-guided drainage of pancreatic fluid collections (PFC). In these reports the drainage modality has been a single aspiration or deployment of a plastic stent [1–4]. We report a patient who underwent transesophageal EUS-guided drainage of a mediastinal PFC using a novel lumen-apposing metal stent.

A 37-year-old man with a history of right-sided pneumothorax and four episodes of acute pancreatitis was referred for drainage of a PFC. He was experiencing abdominal pain and cysts of increasing size had been seen on his imaging procedures. Computed tomography (CT) scanning revealed an 80×50-mm PFC, which had herniated into the mediastinum adjacent to the lower esophagus.

The PFC was accessed from the lower esophagus using a linear echoendoscope and a novel access device (NAVIX; Xlumena Inc., Mountain View, California, USA) that enables dilation of a tract up to 10 mm and placement of a guide wire. Once the cystoesophagostomy had been created, a fully covered metal stent with bilateral anchor flanges that can appose nonadherent lumens (AXIOS, 10×10 mm; Xlumena) was placed across the tract (▶ Fig. 1, ▶ Fig. 2 and ▶ Video 1) and 900 mL of fluid was aspirated. An immediate chest radiograph revealed a tension pneu-

mothorax on the right side, which required intercostal drainage. The thoracic surgeon who performed the drainage procedure felt that this was a complication of the orotracheal positive pressure.

By day 7, the patient reported resolution of his abdominal pain and a repeat CT scan revealed a marked reduction in the size of the PFC (● Fig. 3). The AXIOS stent was removed (● Fig. 4) and the patient was discharged with marked improvement in the pneumothorax. Follow-up imaging after 6 weeks showed complete resolution of the lesion by both EUS and CT scanning (● Fig. 5). The patient remains asymptomatic 4 months later.

EUS-guided transesophageal drainage of PFCs has become an alternative to surgery or percutaneous drainage [1–4]. We de-

scribe the first case of transesophageal EUS-guided drainage of a PFC using a novel lumen-apposing metal stent. The procedure was technically successful and led to complete resolution of the lesion, although a pneumothorax occurred as an immediate complication.

Endoscopy_UCTN_Code_TTT_1AS_2AC

Competing interests: None

**J. B. Gornals¹, C. Loras¹, R. Mast²,
J. M. Botargues¹, J. Busquets³,
J. Castellote¹**

¹ Department of Digestive Diseases, Hospital Universitari de Bellvitge-IDIBELL, Barcelona, Spain

² Department of Radiology, Hospital Universitari de Bellvitge-IDIBELL, Barcelona, Spain

³ Department of Surgery, Hospital Universitari de Bellvitge-IDIBELL, Barcelona, Spain

Video 1

Transesophageal endoscopic ultrasound (EUS)-guided mediastinal pseudocyst drainage using a lumen-apposing metal AXIOS stent.

References

- 1 Trevino J, Christein J, Varadarajulu S. EUS-guided transesophageal drainage of peripancreatic fluid collections. *Gastrointest Endosc* 2009; 70: 793–797
- 2 Saftouia A, Cuireia T, Dumitrescu D et al. Endoscopic ultrasound-guided transesophageal drainage of a mediastinal pancreatic pseudocyst. *Endoscopy* 2006; 38: 538–539
- 3 Baron TH, Wiersema MJ. EUS-guided transesophageal pancreatic pseudocyst drainage. *Gastrointest Endosc* 2000; 52: 545–549
- 4 Gupta R, Munoz JC, Garg P et al. Mediastinal pancreatic pseudocyst: a case report and review of the literature. *Med Gen Med* 2007; 9: 8–13

Bibliography

DOI <http://dx.doi.org/10.1055/s-0032-1309384>
Endoscopy 2012; 44: E211–E212
 © Georg Thieme Verlag KG
 Stuttgart · New York
 ISSN 0013-726X

Corresponding author

J. B. Gornals, MD
 Endoscopy Unit
 Department of Digestive Diseases
 Hospital Universitari de Bellvitge
 IDIBELL (Bellvitge Biomedical Research Institute)
 Feixa Llarga Str. s/n
 08907 L'Hospitalet de Llobregat
 Barcelona
 Spain
 Fax: +34-93-2607681
jgornals@bellvitgehospital.cat