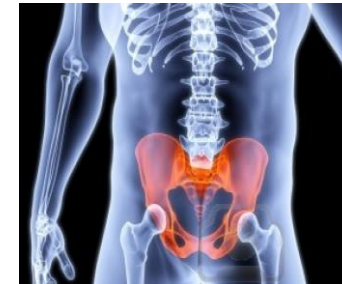

**Especialización en
Ultrasonografía
Endoscópica Avanzada**

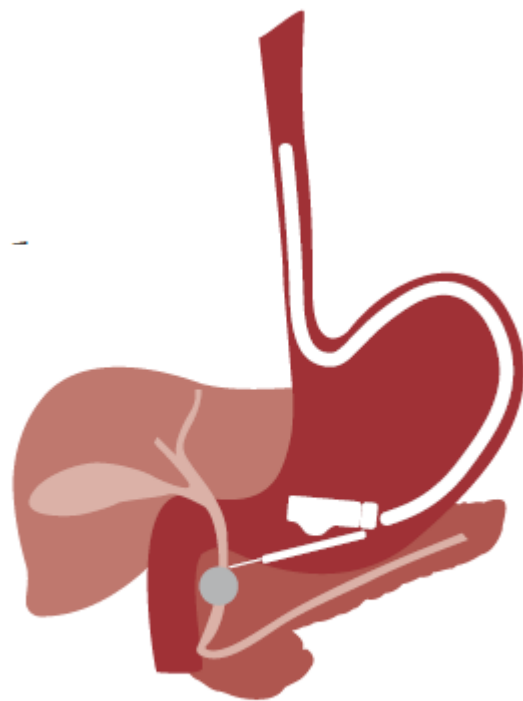


Universidad
de Alcalá



Hospital Universitario
Ramón y Cajal

Comunidad de Madrid



DRENAJE GUIADO POR ECOENDOSCOPIA DE COLECCIONES NO PANCREÁTICAS

José Ramón Foruny Olcina

Servicio de Gastroenterología y Hepatología
Hospital Universitario Ramón y Cajal

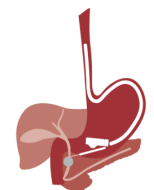
5ª edición
Curso 2021/2022

18/03/2022

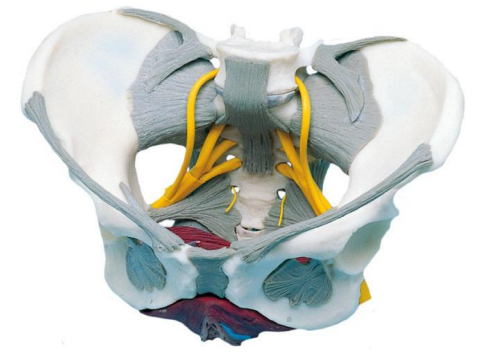
■ ABSCESOS PÉLVICOS

■ COLECCIONES POSTQUIRÚRGICAS INTRABDOMINALES

■ ABSCESOS / COLECCIONES MEDIASTÍNICAS



COLECCIONES PÉLVICAS: ETIOLOGÍA



■ Complicaciones de cirugía

- **Dehiscencia suturas**
- **Hematomas**
- **Seromas**



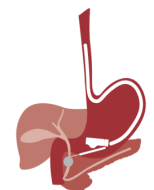
- Edad avanzada
- Desnutrición
- Transfusiones
- Tratamiento corticoideo
- Neoplasia maligna subyacente

■ Perforación de víscera hueca

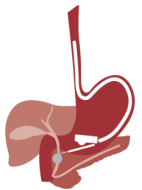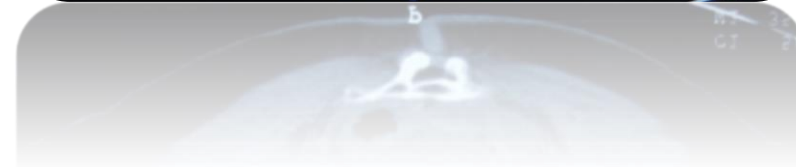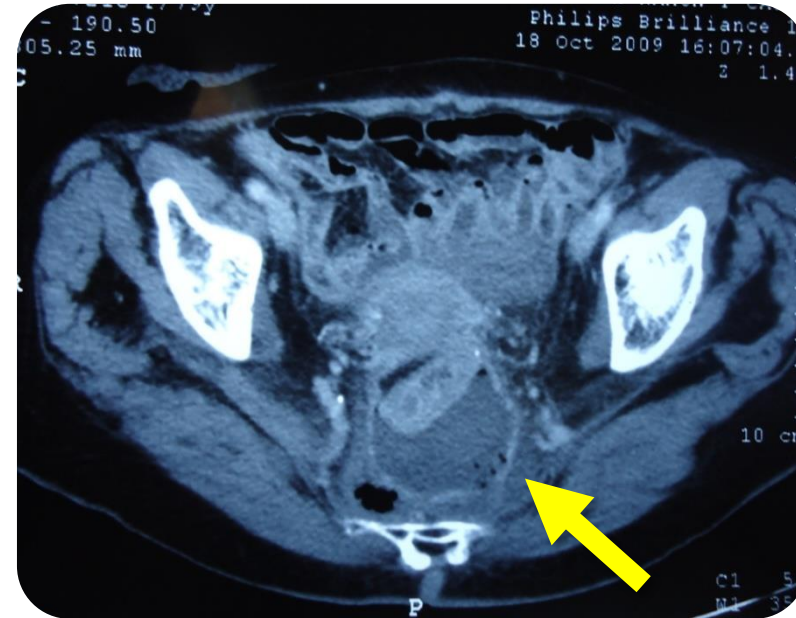
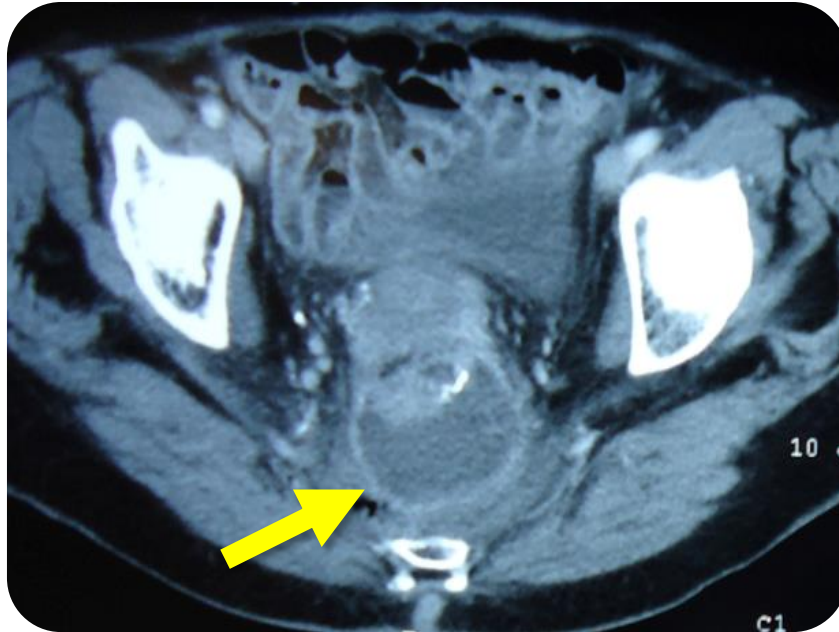
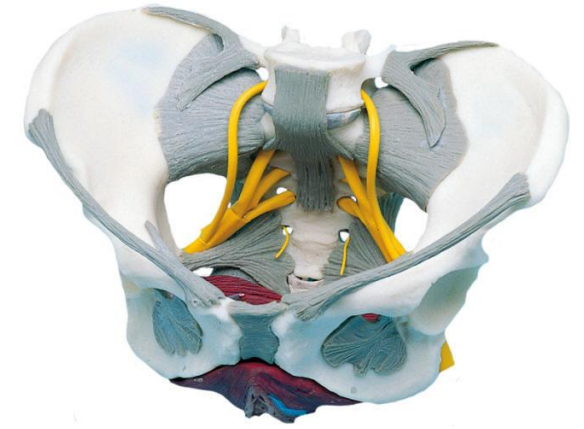
- **Apendicitis**
- **Diverticulitis**

■ Enfermedad inflamatoria intestinal (enfermedad de Crohn)

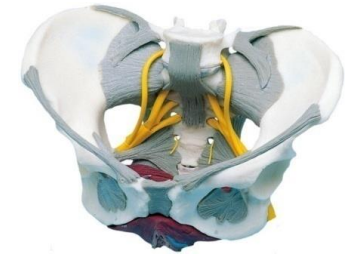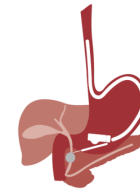■ Traumatismos abdominales (contusos o penetrantes)



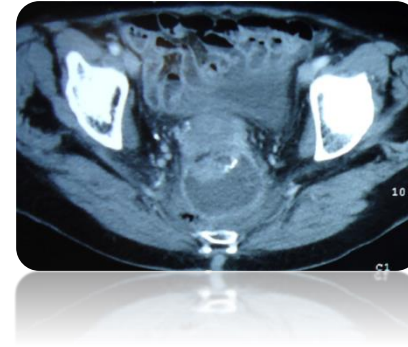
DIAGNÓSTICO



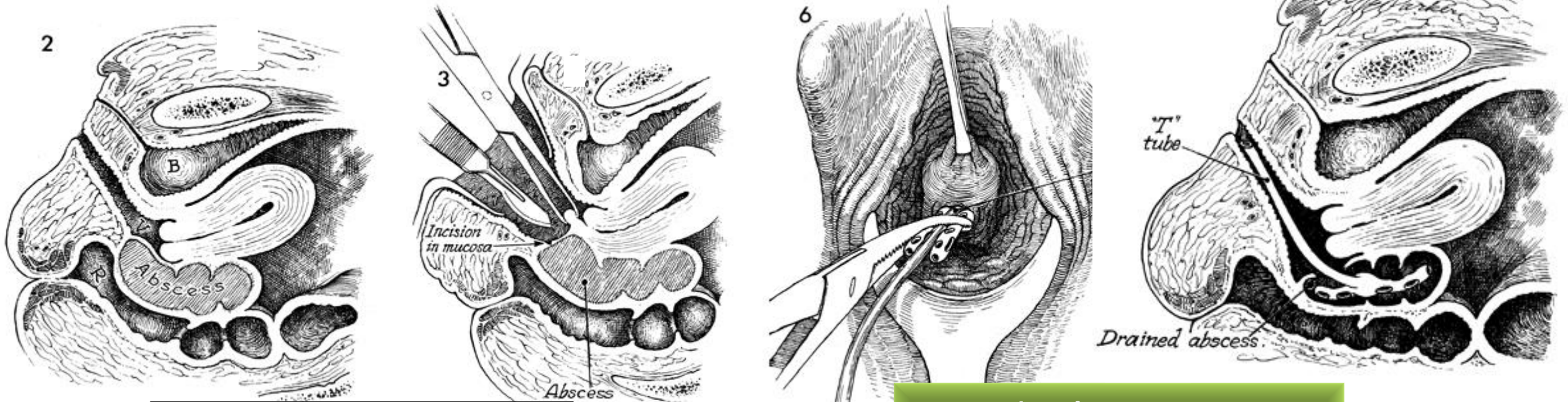
Medidas terapéuticas



- SOPORTE HEMODINÁMICO
- TRATAMIENTO ANTIBIÓTICO
- DRENAJE



Quirúrgico

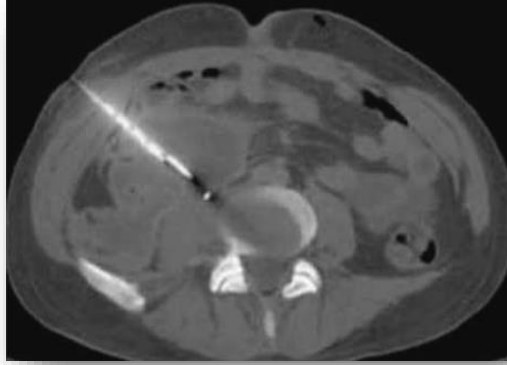


Golfieri R. Tech Coloproctol 2007

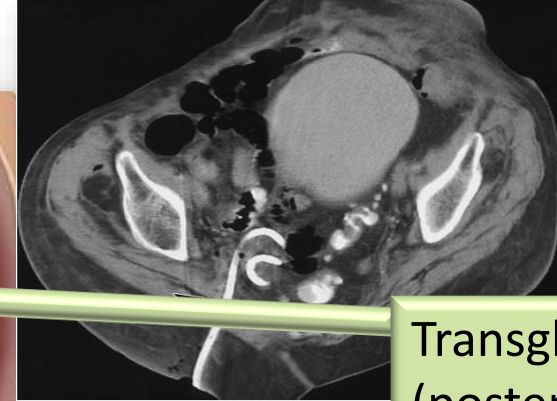
Tasa de éxito: 56-96%

Drenaje radiológico

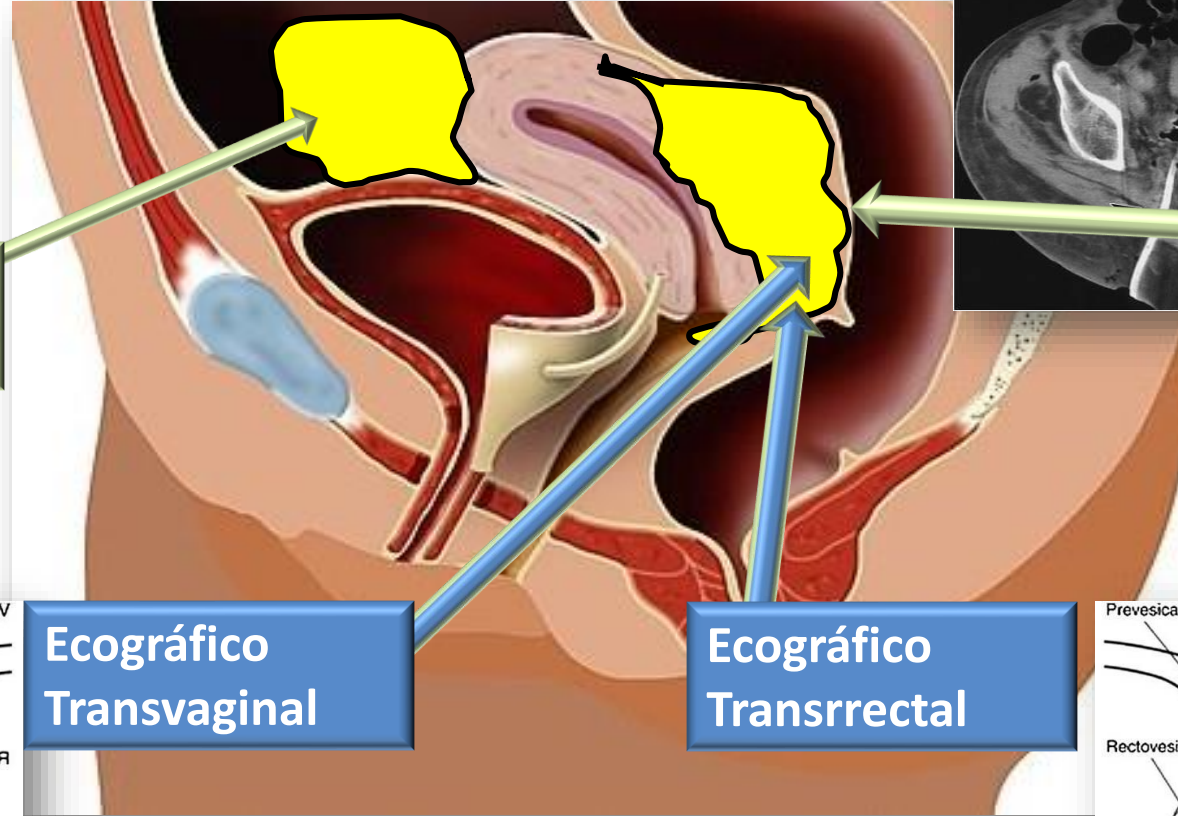
Tasa éxito: 27-96%
Complicaciones: 8-10%



Transabdominal
(anterior o lateral)

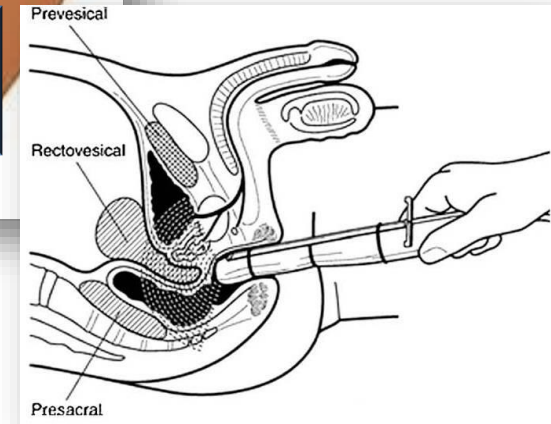
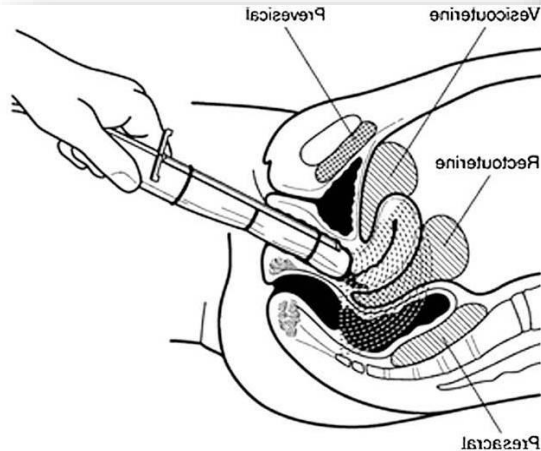


Transglúteo
(posterior)



Ecográfico
Transvaginal

Ecográfico
Transrectal



Tasa éxito: 75-91%

Drainage of Deep Pelvic Abscesses Using Therapeutic Echo Endoscopy

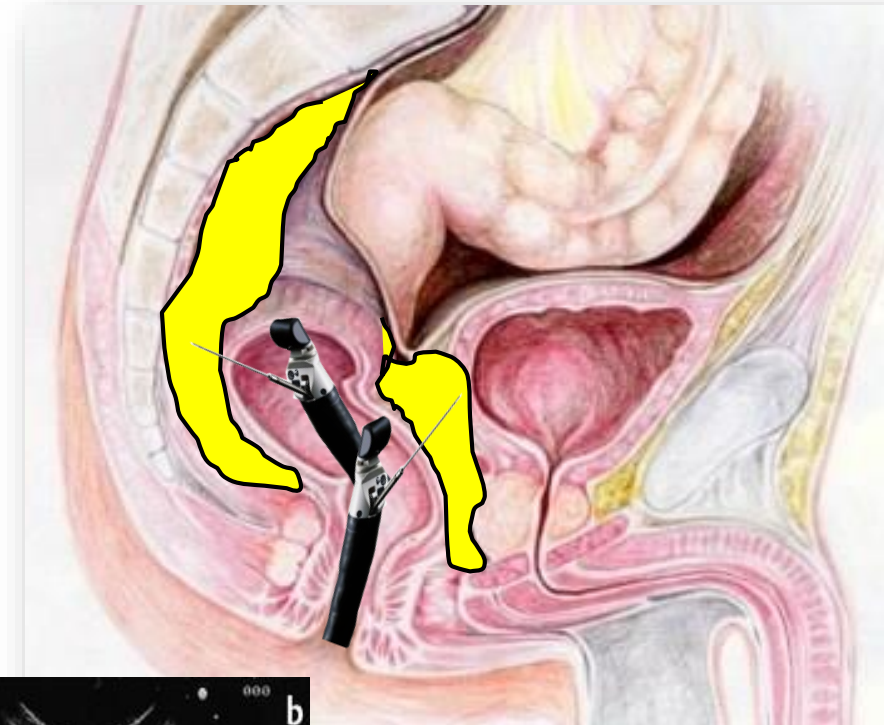
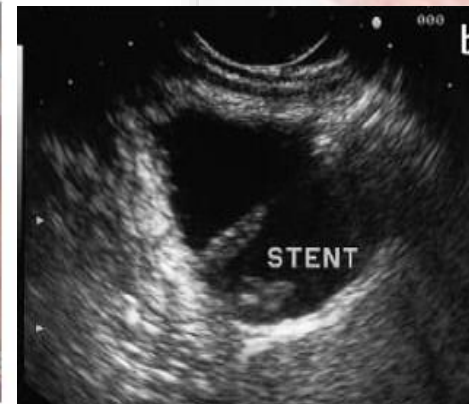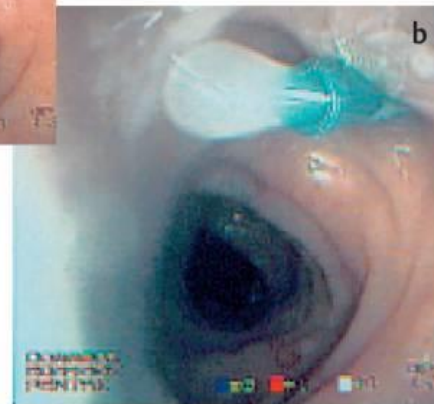
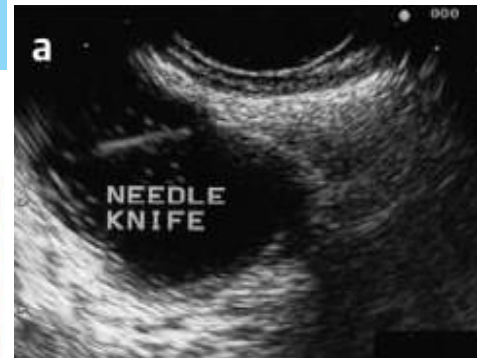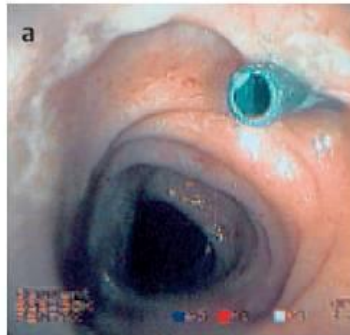
Endoscopy 2003; 35: 511 – 514

M. Giovannini¹
E. Bories¹
V. Moutardier²
C. Pesenti¹
A. Guillemin¹
B. Lelong²
J. R. Delpéro²

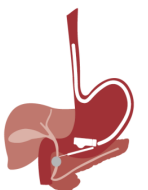- 12 pacientes

9 prótesis

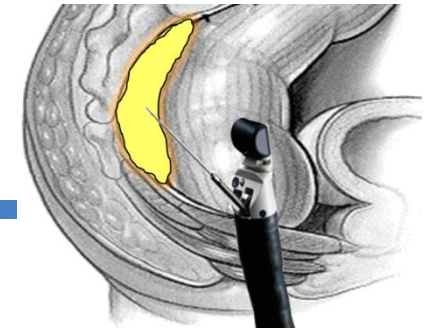
3 aspiración



-75% resolución
completa
(seguimiento 10,4 meses)



Potenciales ventajas del drenaje por ecoendoscopia



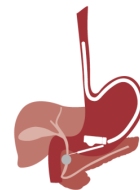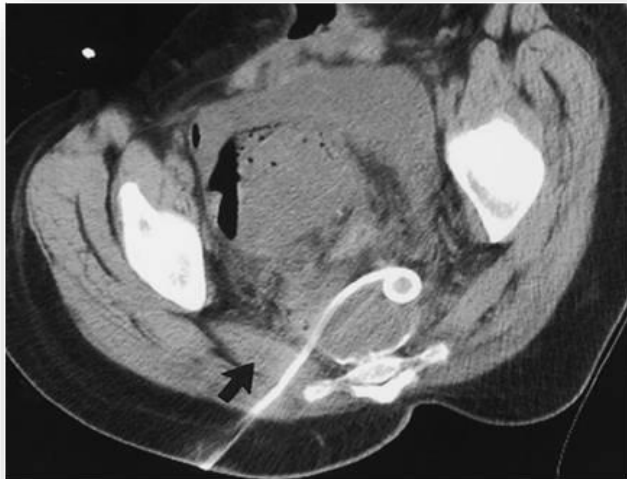
Frente al drenaje-TC

Permite colocación de prótesis internas

Procedimiento menos doloroso

No riesgo de lesión de nervio ciático
ni de los vasos glúteos inferiores

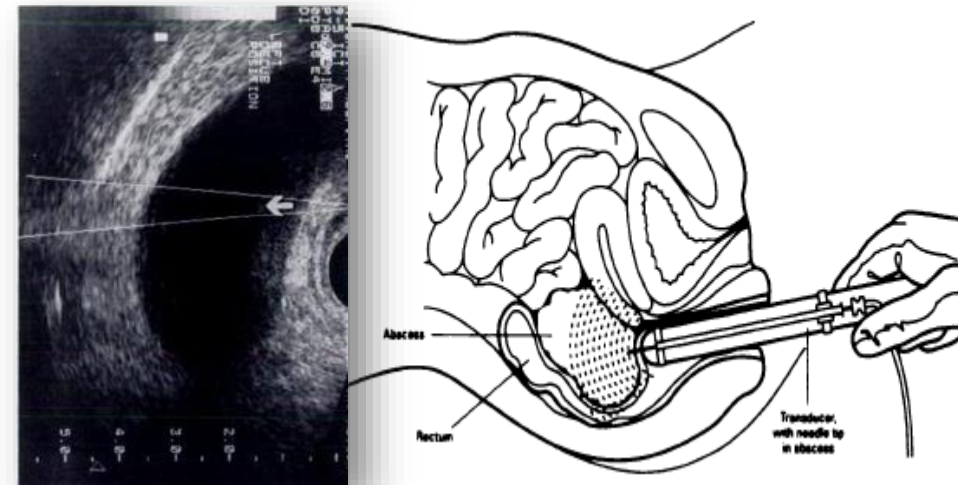
No precisa traslado del paciente



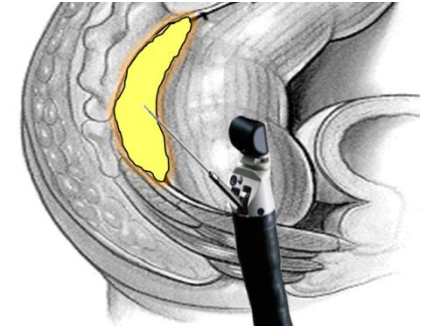
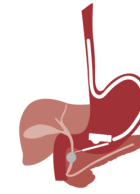Frente a drenaje-eco (sonda rígida)

Permite colocación de prótesis internas

Accesos a territorios proximales



Limitaciones drenaje por USE



- Colecciones multiloculadas
- Colecciones menores de 4 cm
- Paredes inmaduras
- Colecciones muy distales (adyacentes a la línea dentada)
- Distancia > 1,5-2 cm respecto al transductor de ecoendoscopia
- Abscesos secundarios a diverticulitis (controvertido)

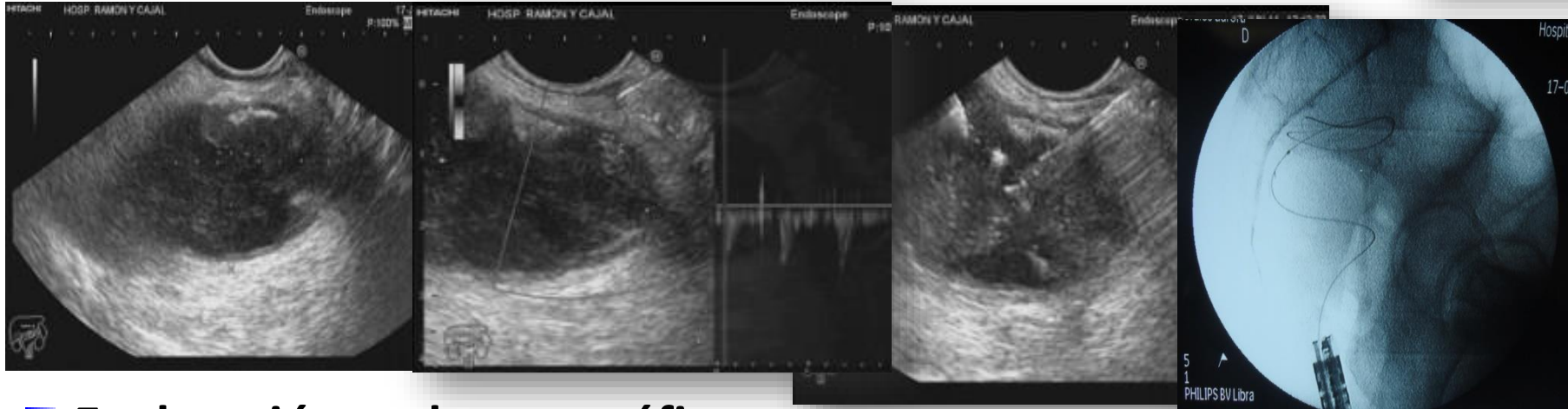
- Preparación colónica
- Profilaxis antibiótica
- Sondaje vesical
- Sedación

Técnica

EUS 2008 Working Group document: evaluation of EUS-guided drainage of pelvic-fluid collections (with video) 

Shyam Varadarajulu, MD, Yuk Tong Lee, MD

GASTROINTESTINAL ENDOSCOPY Volume 69, No. 2 : 2009



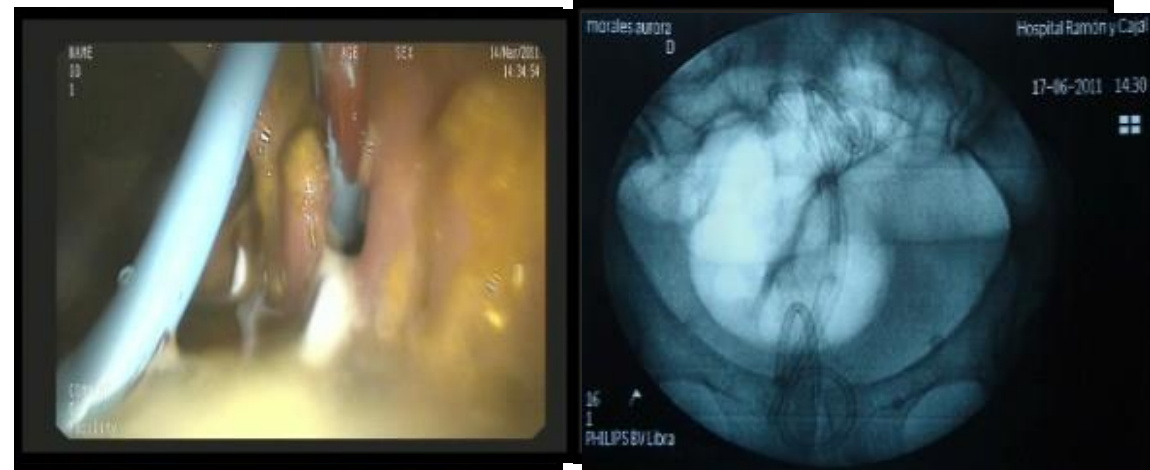
- **Exploración endosonográfica**
 - Localización del absceso (relaciones anatómicas-vasculares)

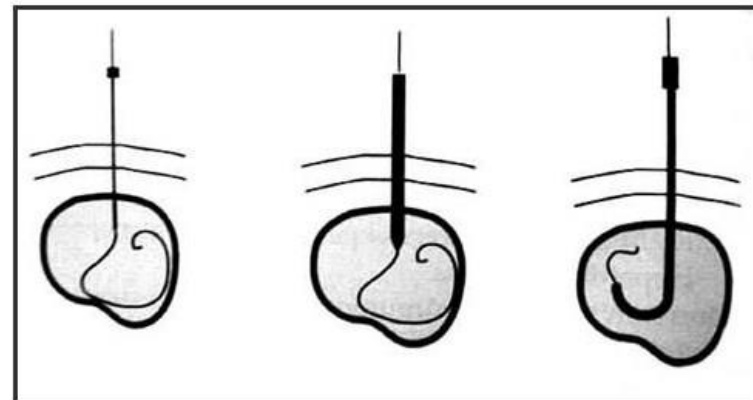
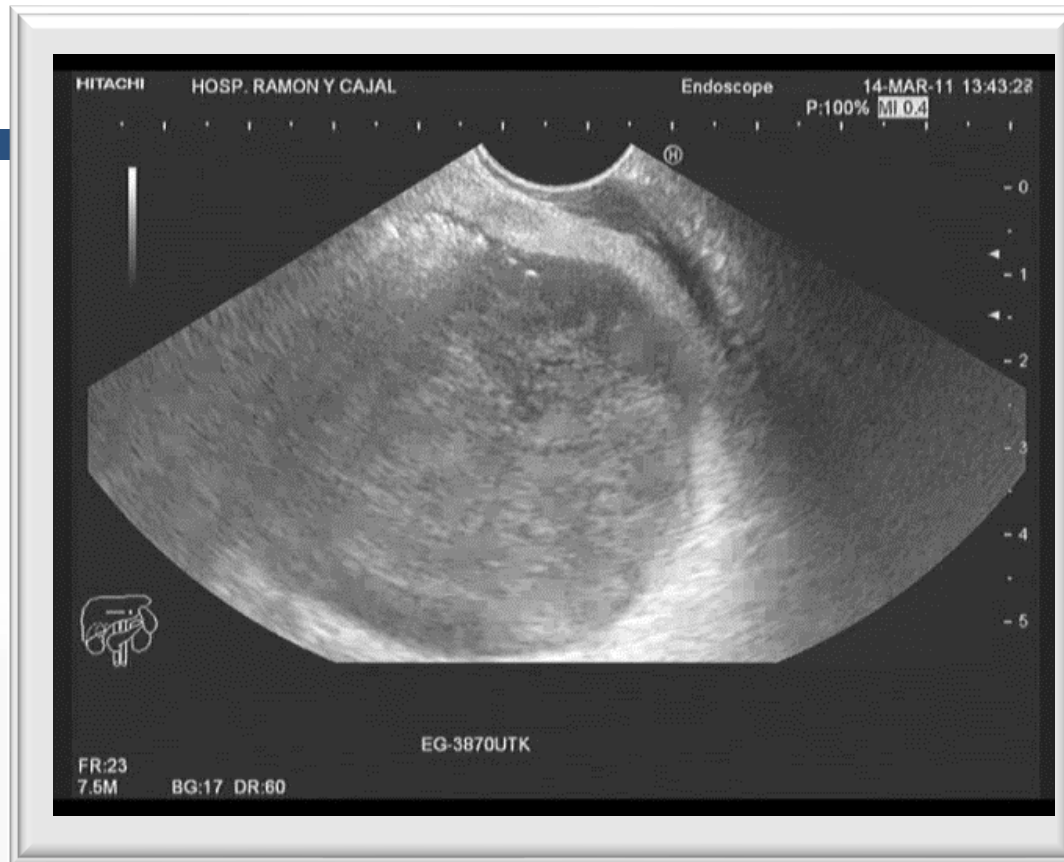
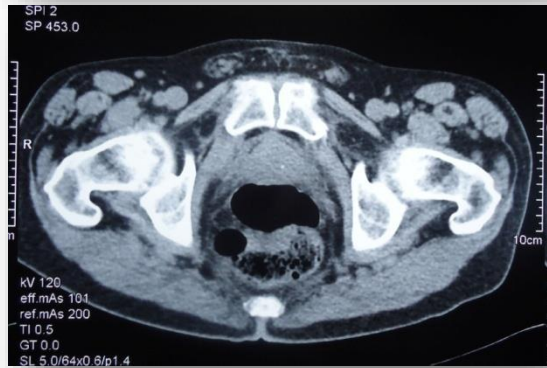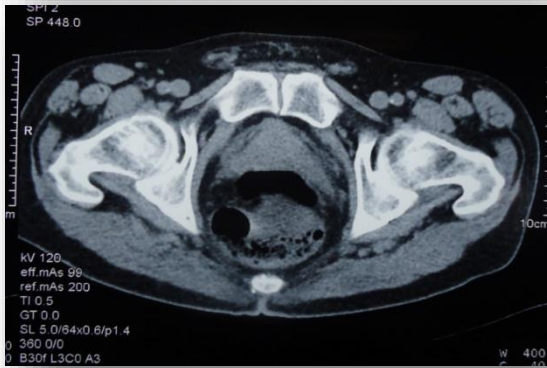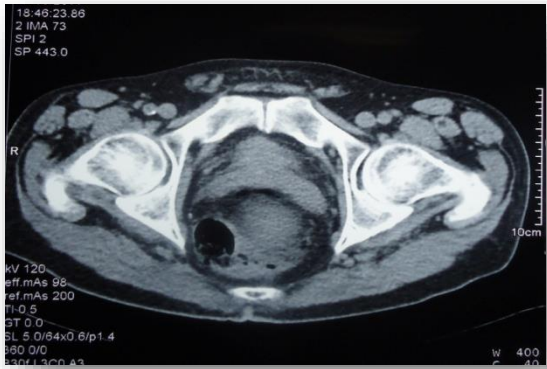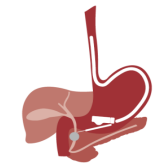- **PAAF (19G) y guía**

- **Formación de fístula**

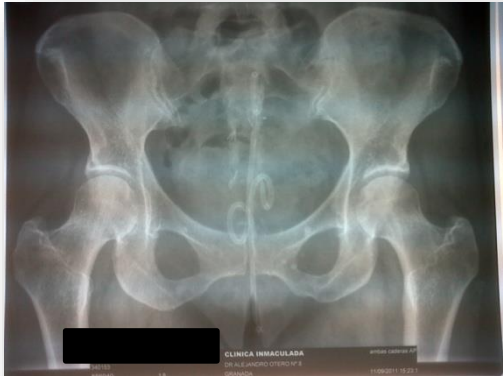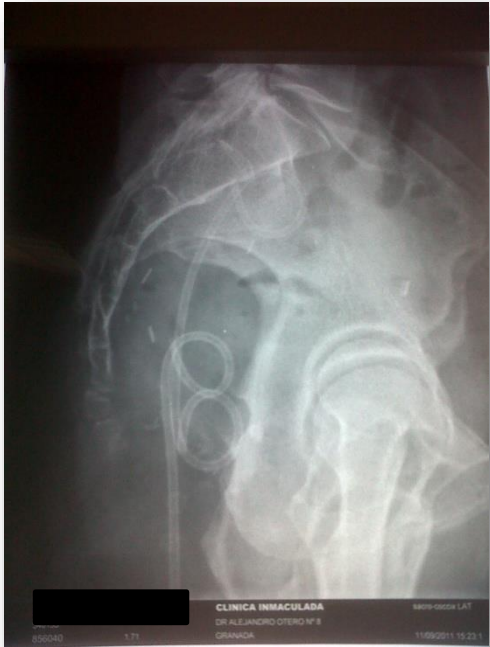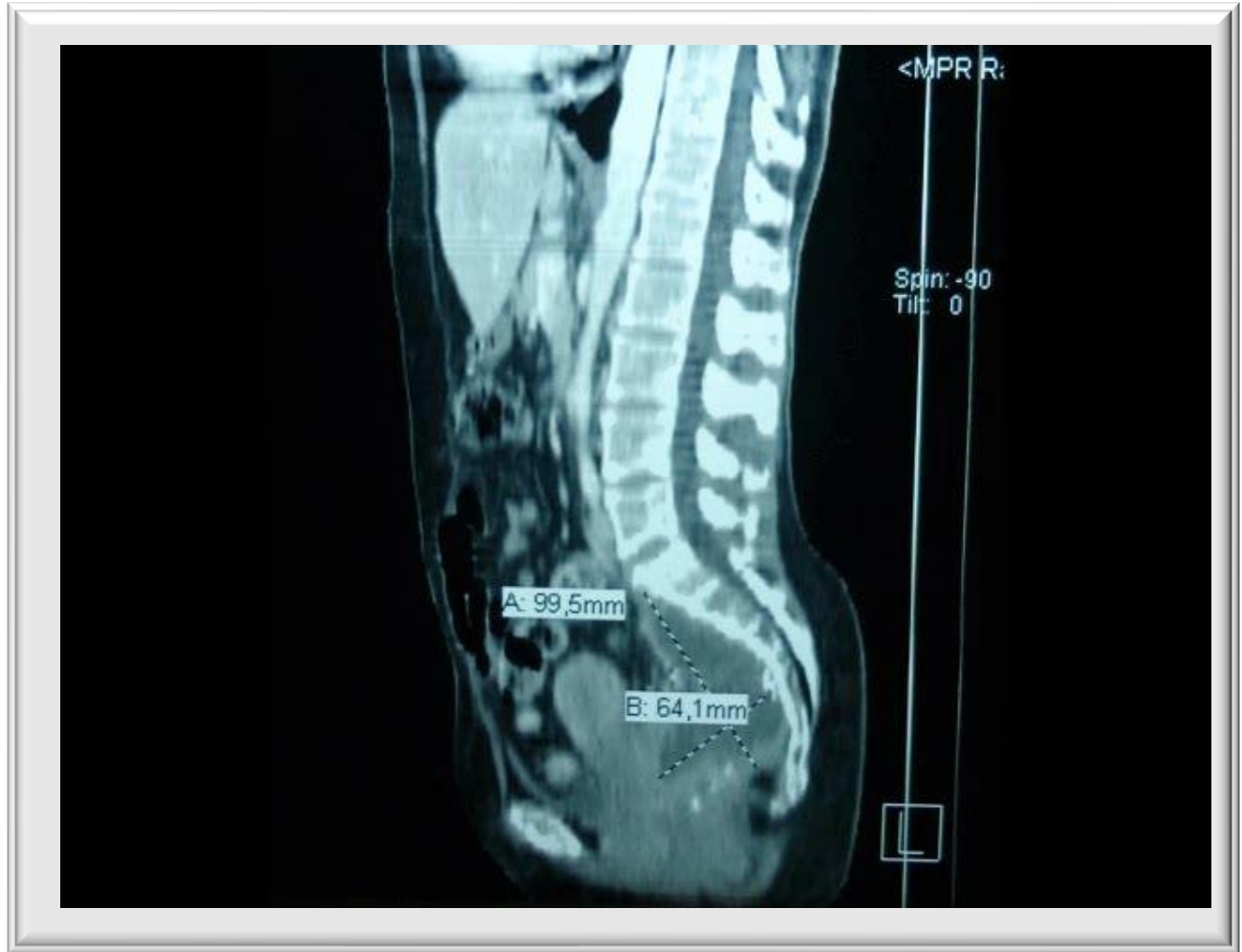- **Dilatación con balón 6-8 mm**

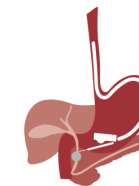- **Colocación de prótesis o catéter de drenaje**





Seldinger SI. Acta Radiologica 1953





Modified technique for EUS-guided drainage of pelvic abscess (with video)

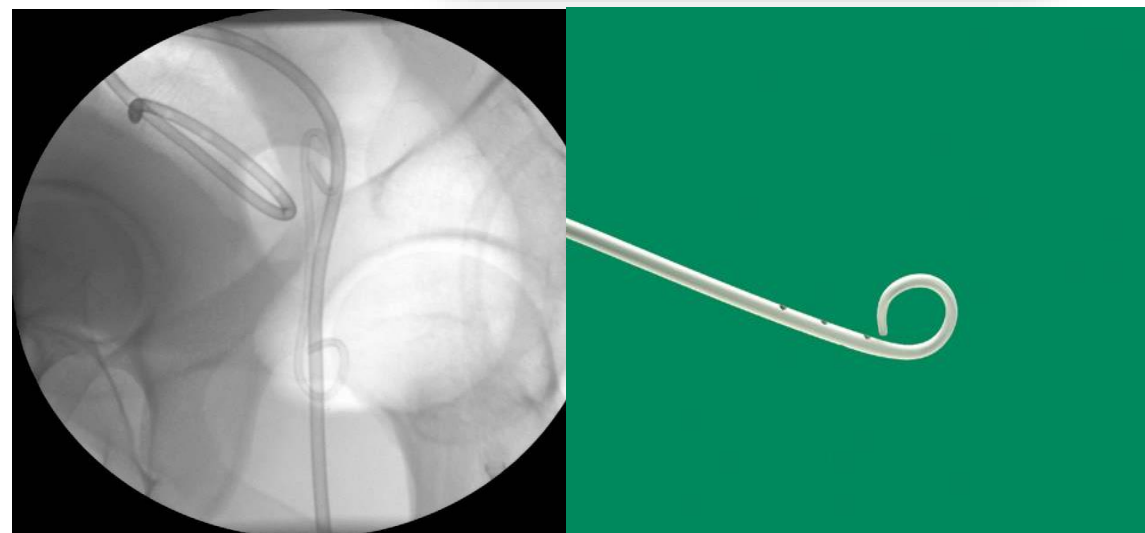
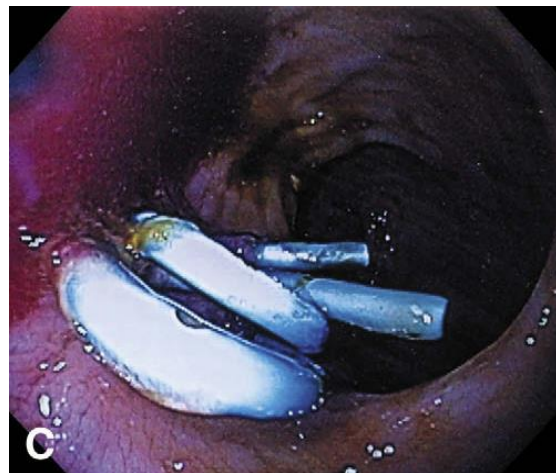
Jessica M. Trevino, MD, Ernesto R. Drelichman, MD, Shyam Varadarajulu, MD

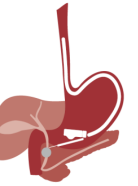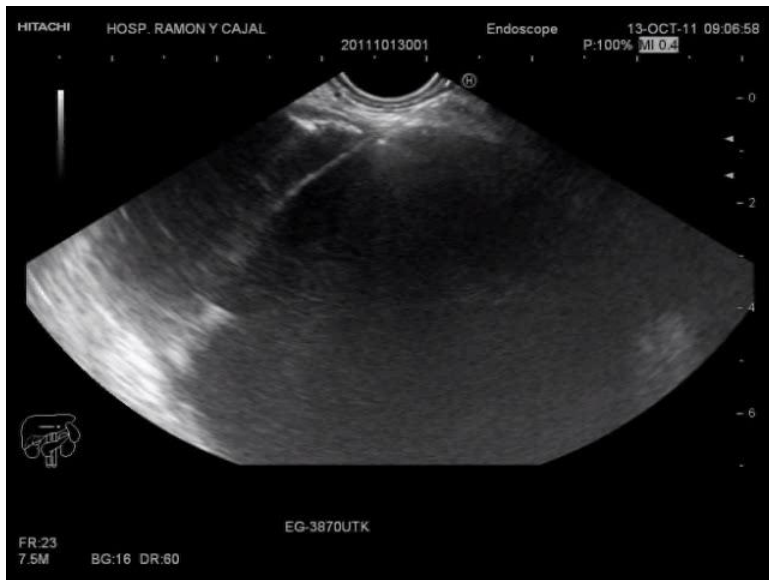
2008 GASTROINTESTINAL ENDOSCOPY

Effectiveness of EUS in drainage of pelvic abscesses in 25 consecutive patients (with video)

Shyam Varadarajulu, MD, Ernesto R. Drelichman, MD

2009 GASTROINTESTINAL ENDOSCOPY





sin fluoroscopia

Endoscopic ultrasound-guided pelvic and prostatic abscess drainage: Experience in 30 patients

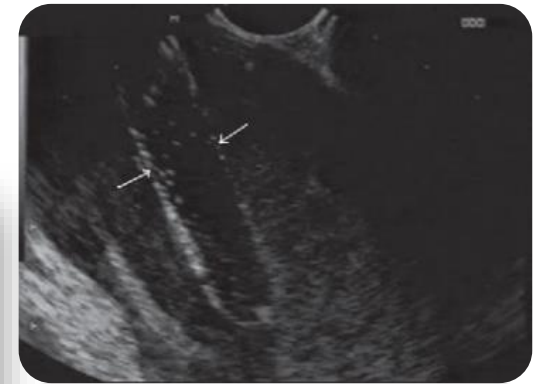
**Rajesh Puri • Narendra S. Choudhary • Hardik Kotecha • Saumin P. Shah •
Manish Paliwal • Smurti R. Misra • Suraj Bhagat • Kaushal Madan •
Neeraj Saraf • Randhir Sud**

Indian J Gastroenterol (September–October 2014) 33(5):410–413

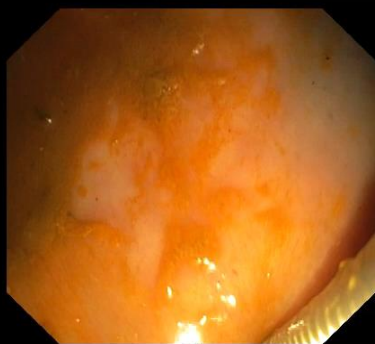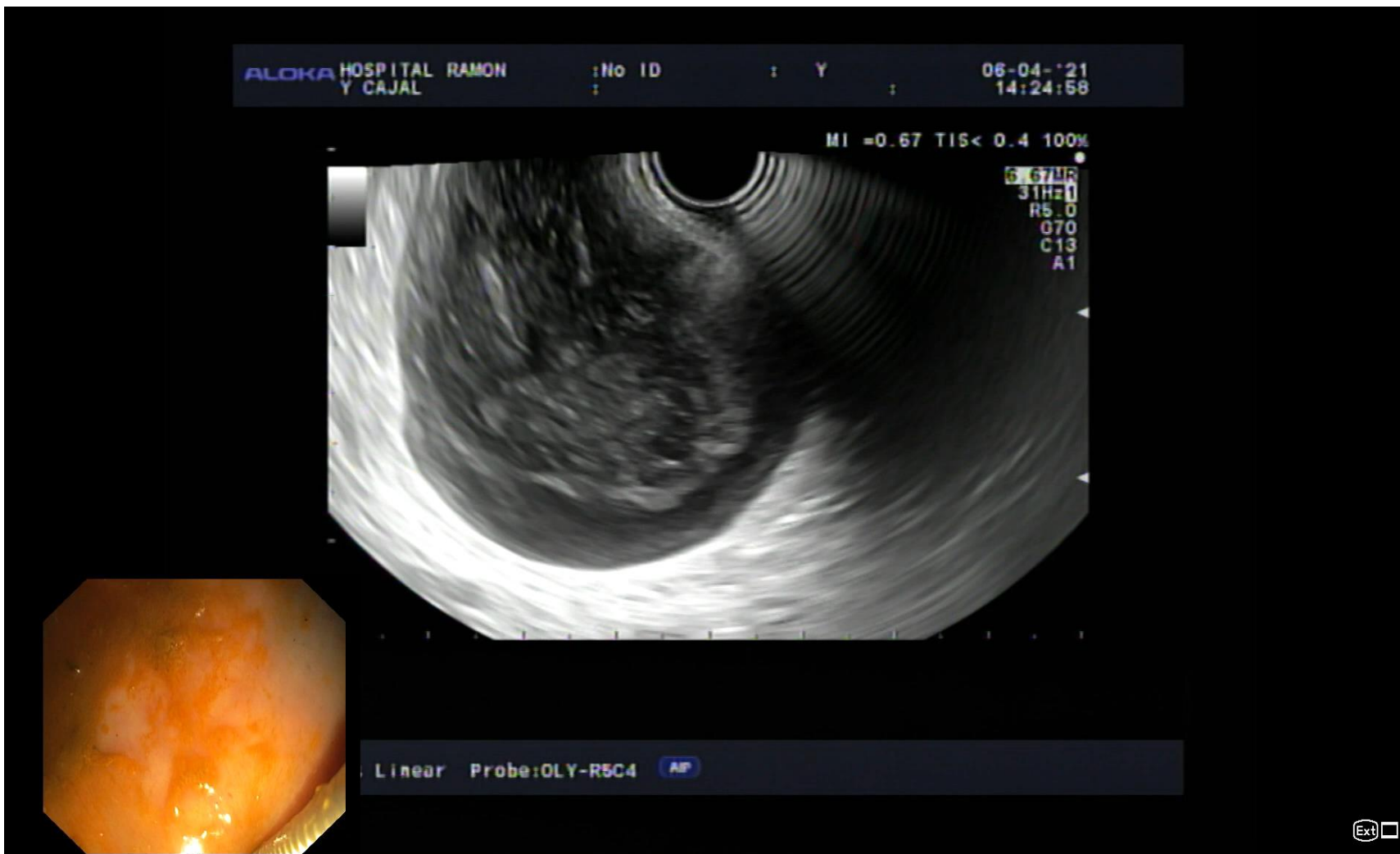
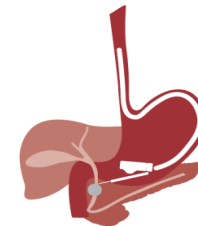
Endoscopic ultrasound-guided drainage of pelvic abscess: A case series of 8 patients

Muhammed Hadithi, Marco J Bruno

World J Gastrointest Endosc 2014

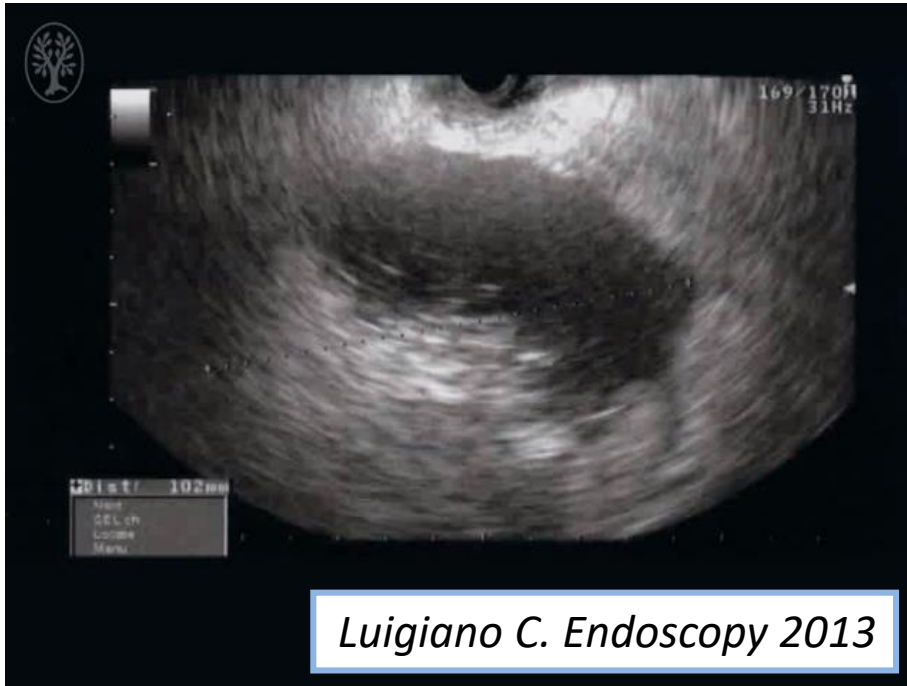


Prótesis de aposición luminal

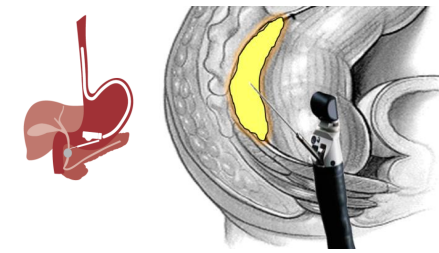


Prótesis metálicas

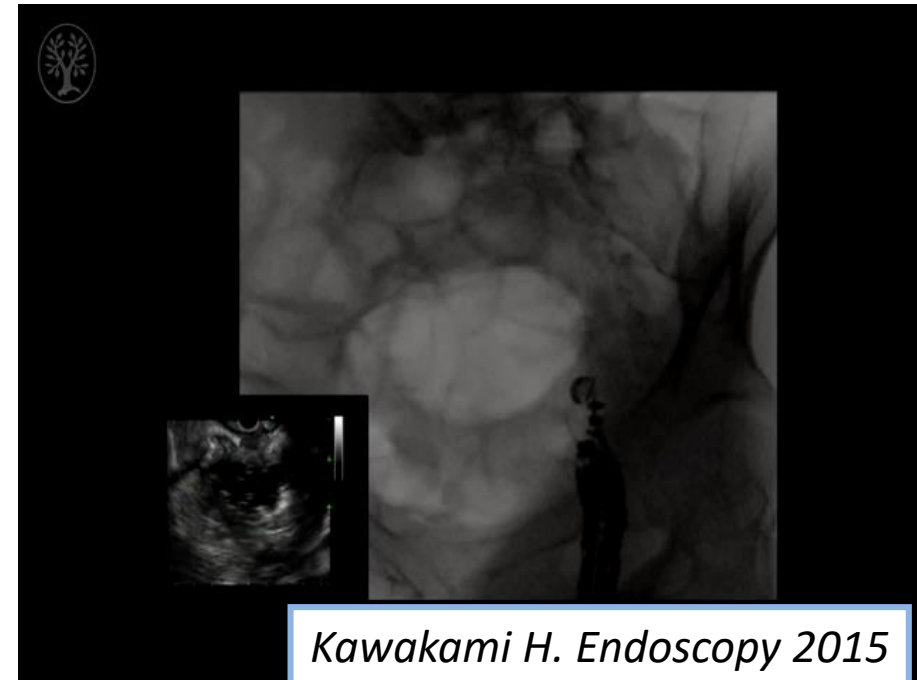
Transrectal endoscopic ultrasound-guided drainage of pelvic abscess with placement of a fully covered self-expandable metal stent



- Mayor diámetro
- Sistema antimigración
- Menos molestos en abscesos distales



Endoscopic ultrasound-guided pelvic abscess drainage using a dedicated, wide, flared-end, fully covered self-expandable metal stent



Endoscopic ultrasound-guided drainage of a pelvic abscess via a J-pouch

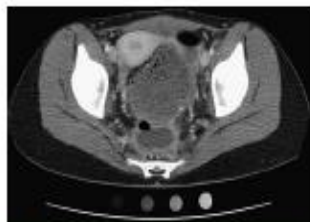


Fig. 1 Computed tomography (CT) of the pelvis, revealing a 5 × 3-cm pelvic abscess in a patient with J-pouch anatomy.

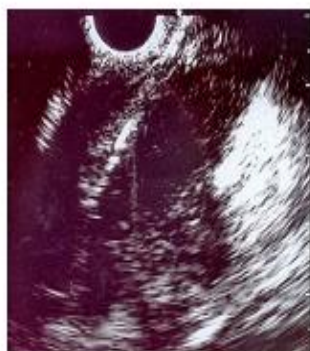

Fig. 2 Endoscopic ultrasound (EUS) image: the abscess cavity was punctured using a 19-gauge fine needle aspiration needle via the J-pouch under EUS guidance.

While prior reports have demonstrated the usefulness of endoscopic ultrasound (EUS) for transrectal drainage of pelvic abscesses, its utility for performing drainage via an ileoanal reservoir (J-pouch) has not been reported before.

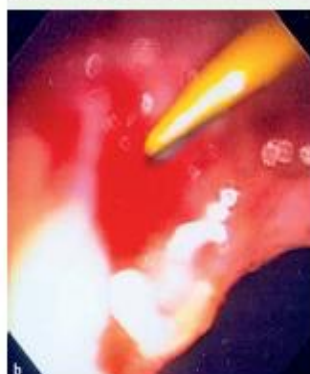
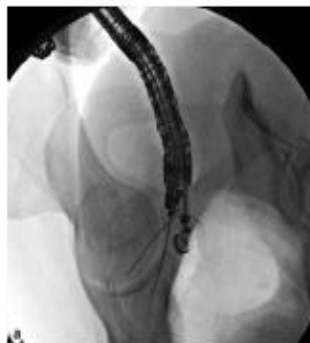

Fig. 3 a A 0.035-inch guidewire coiled within the abscess cavity under fluoroscopic guidance to facilitate sequential dilation. b Endoscopic view of the guidewire passed into the abscess cavity via the J-pouch.

dilated using a 5-Fr endoscopic retrograde cholangiopancreatography cannula and a 6-mm balloon dilator (Fig. 4). A 7-Fr

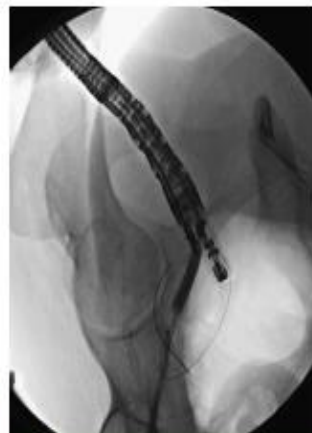

Fig. 4 Dilation of the transmural tract using a 6-mm over-the-wire balloon.

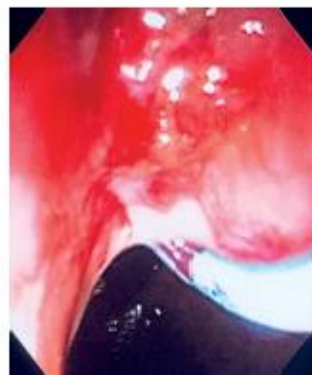


Fig. 5 Placement of a double pigtail stent into the abscess cavity via the J-pouch.

- Drenaje a través de reservorio

Transrectal ultrasound-guided endoscopic drainage and vacuum therapy of pelvic abscesses: an alternative to (computed tomography-guided) percutaneous drainage

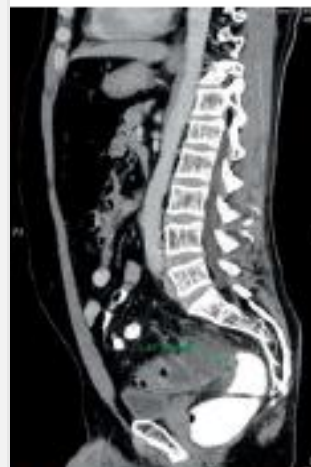

Fig. 1 Abdominal computed tomography (CT) scan in a 43-year-old man with abdominal pain but no fever showing a pelvic abscess measuring 4 × 4.5 × 6 cm (see measuring mark) due to complicated diverticulitis (Hartmann and Stapck 18). The sigmoid colon, filled with contrast media, can be seen posterior to the abscess.

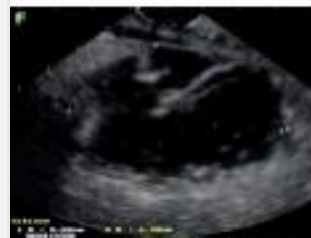

Fig. 2 Endosonographic view of the pelvic abscess for exact localization.

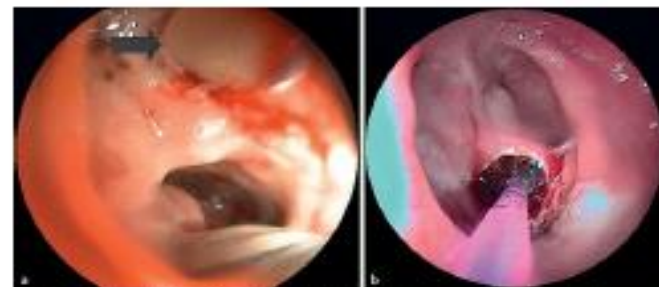


Fig. 3 a Pin (arrow) released into the sigmoid colon following puncture of the abscess. b The puncture site was dilated using a balloon.

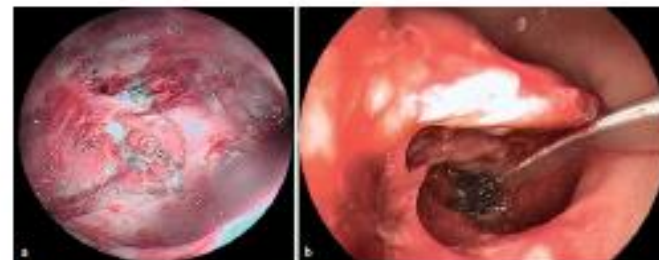
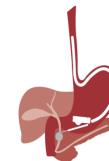
Fig. 4 a Endoscopic view of the flushed abscess cavity. b Insertion of a vacuum therapy sponge into the abscess cavity.

firmly the suspected diagnosis of diverticulitis and revealed a large pelvic abscess (Fig. 1). The intended CT-guided drainage [1] carried a high risk of injury to the iliac vessels in a translumbar approach and of damaging the sciatic nerve for access through the obturator foramen. The overlying small bowel forbade a ventral approach. The patient underwent transrectal endosonography (Fig. 2) for localization of the abscess. Using an endo-

sophageal approach, the abscess cavity was flushed and a vacuum therapy sponge (Endo-SPONGE, B. Braun, Melsungen, Germany) was inserted into it (Fig. 4). The patient received antibiotics and parenteral feed for the first week. No ostomy was placed. The vacuum therapy sponge was changed endoscopically on every third day until day 17, when the patient was discharged. Laparoscopic sigmoid resection was performed 1 month later without complica-

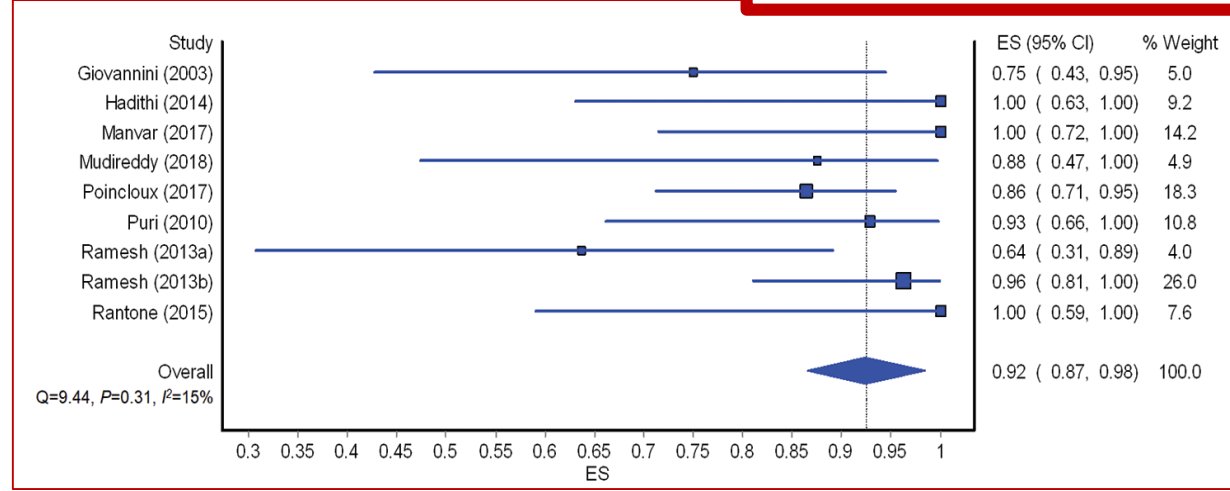
- Drenaje + Endosponge



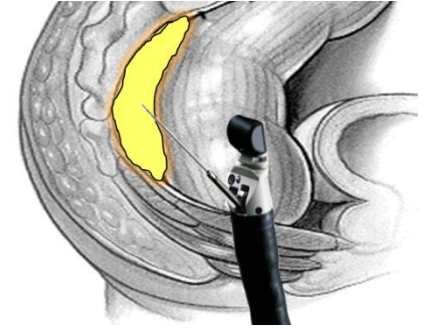
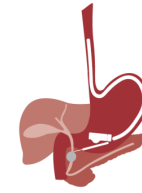EUS-guided pelvic drainage: A systematic review and meta-analysis

Study name	Year	Country	Type of study	Single/multicenter	Manuscript or abstract	Number of patients	Mean age	Male	Female
Giovannini <i>et al.</i> ^[8]	2003	France							
Hadithi and Bruno ^[13]	2014	The Netherl							
Mudireddy <i>et al.</i> ^[16]	2018	USA							
Poincloux <i>et al.</i> ^[15]	2017	France							
Puri <i>et al.</i> ^[11]	2010	India							
Ramesh-a <i>et al.</i> ^[12]	2013	USA							
Ramesh-b <i>et al.</i> ^[12]	2013	USA							
Ratone <i>et al.</i> ^[14]	2015	France							
Manvar <i>et al.</i> ^[22]	2017	USA							

- 135 pacientes (70% post-quirúrgicos)
- 55,9% varones
- Drenaje transrectal 83,7% / diámetro medio 63 mm
- Doble “pig-tail” (74%) / LAMS (17%) / Aspiración (9%)
- Éxito técnico **100%** / éxito clínico **92%**
- Efectos secundarios 9,4% / Recurrencia 4% (aspiración)



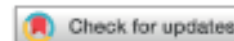Cuidados post-drenaje







- Lavados a través de catéter de drenaje
 - 25-50 ml de SSF cada 4-6 horas (36 h-4 días)
- Control radiológico (CT) en 48-72h
 - Retirar catéter de drenaje si reducción del absceso > 50%
- Retirar prótesis internas en 3-4 semanas tras comprobar resolución del absceso mediante TC
- Reintervención y ampliación de drenaje evolución desfavorable (10-16%)

Varadalajulu S. Gastrointest Endosc 2009
Holt B. J Hepatobiliary Patreat Sci 2015

ORIGINAL PAPER



Endoscopic ultrasound guided versus surgical transrectal drainage of pelvic abscesses

D. V. G. Meylemans^a , L. E. Oostenbrug^b , C. M. Bakker^b, M. N. Sosef^a , J. H. M. B. Stoot^a  and H. J. Belgers^a

^aDepartment of Surgery, Zuyderland Medisch Centrum, Heerlen, The Netherlands; ^bDepartment of Internal Medicine and Gastroenterology, Zuyderland Medisch Centrum, Heerlen, The Netherlands

ABSTRACT

Background: Pelvic abscesses are common but only small case series reporting outcome of either endoscopic ultrasound (EUS) guided or surgical transrectal drainage have been reported.

Methods: We performed a retrospective consecutive cohort study, assessing effectivity and safety of EUS guided or surgical transrectal drainage of previously untreated pelvic abscesses from all causes, diagnosed using CT scan between 09/2010 and 06/2014 in a Dutch teaching hospital.

Results: Forty-six patients with comparable demographics, apart from stoma presence ($p = .016$), were included. The success rate after a single intervention was 83% in the EUS guided compared to 48% in the surgical transrectal drainage group ($p = .013$). However, the mean duration of drainage was threefold in the EUS group [42 versus 13 days ($p = .001$)]. The length of stay in hospital was similar for both EUS and surgical group [24 versus 20 days ($p = .56$)] as was abscess resolution during follow-up [78% versus 74%]. We recorded a total of 12 anastomotic leaks [3 versus 9]. In the occurrence of leakage, only one stoma was finally closed in each group.

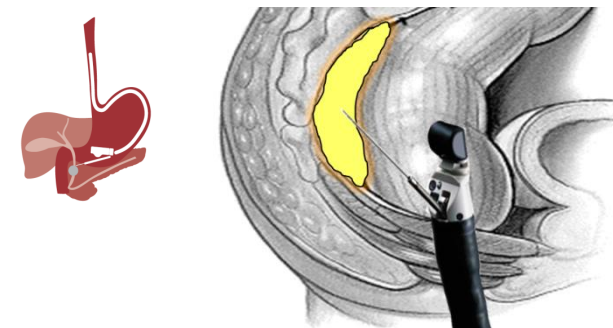
Conclusion: EUS guided and surgical transrectal drainage of pelvic abscesses from any cause are safe, nonetheless EUS guided drainage (if feasible) seems more effective after a single treatment, with high overall cure rates.

ARTICLE HISTORY

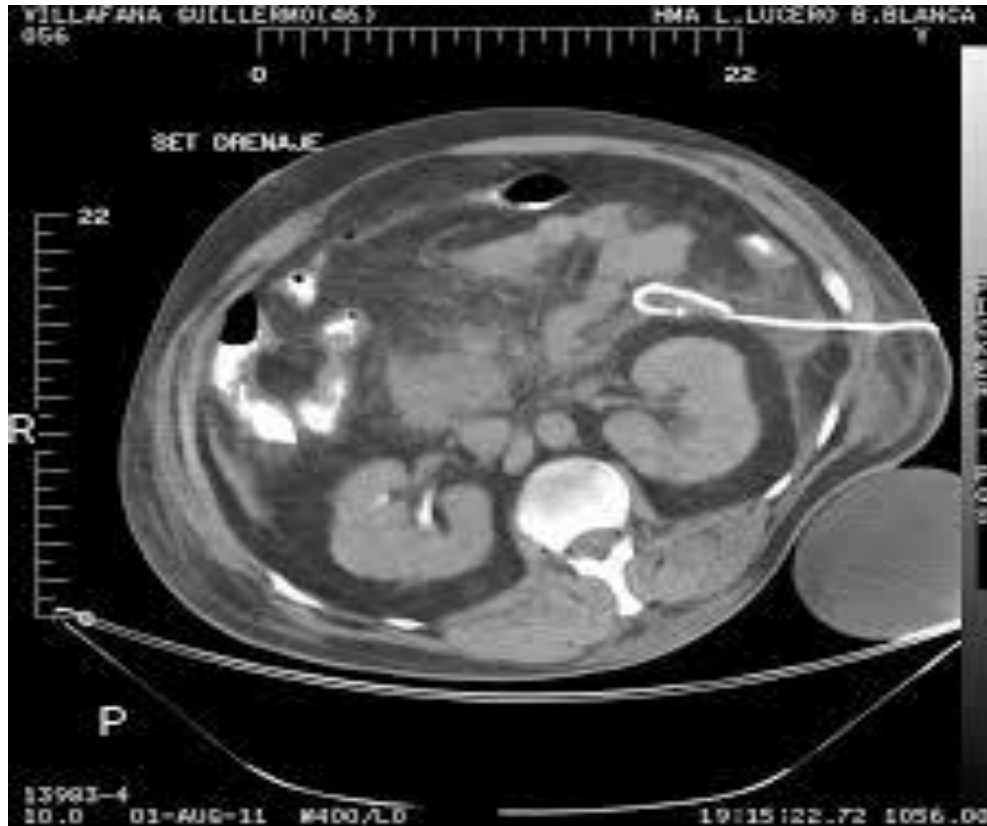
Received 12 February 2017
Accepted 25 November 2017

KEYWORDS

Pelvic abscess; endoscopic ultrasound; transrectal surgery; drainage

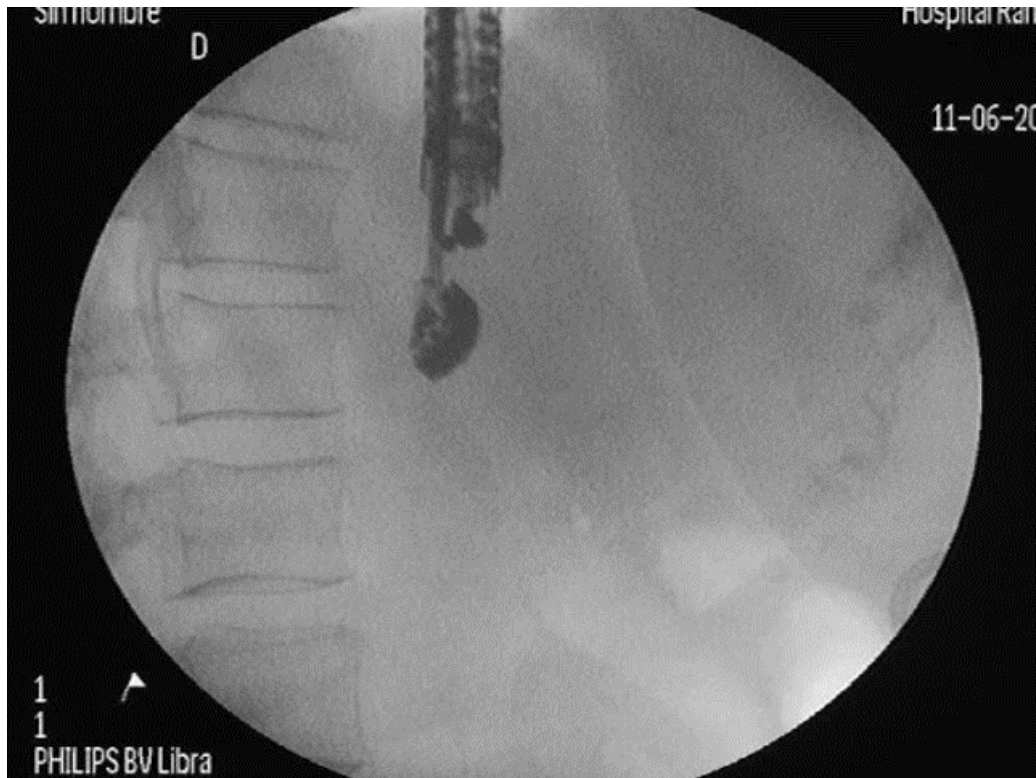


- Mortalidad sin drenaje 45-100%
- Drenaje percutáneo (TC o ecografía) de elección. Eficacia 80-100% -----> mortalidad 1,4-15%

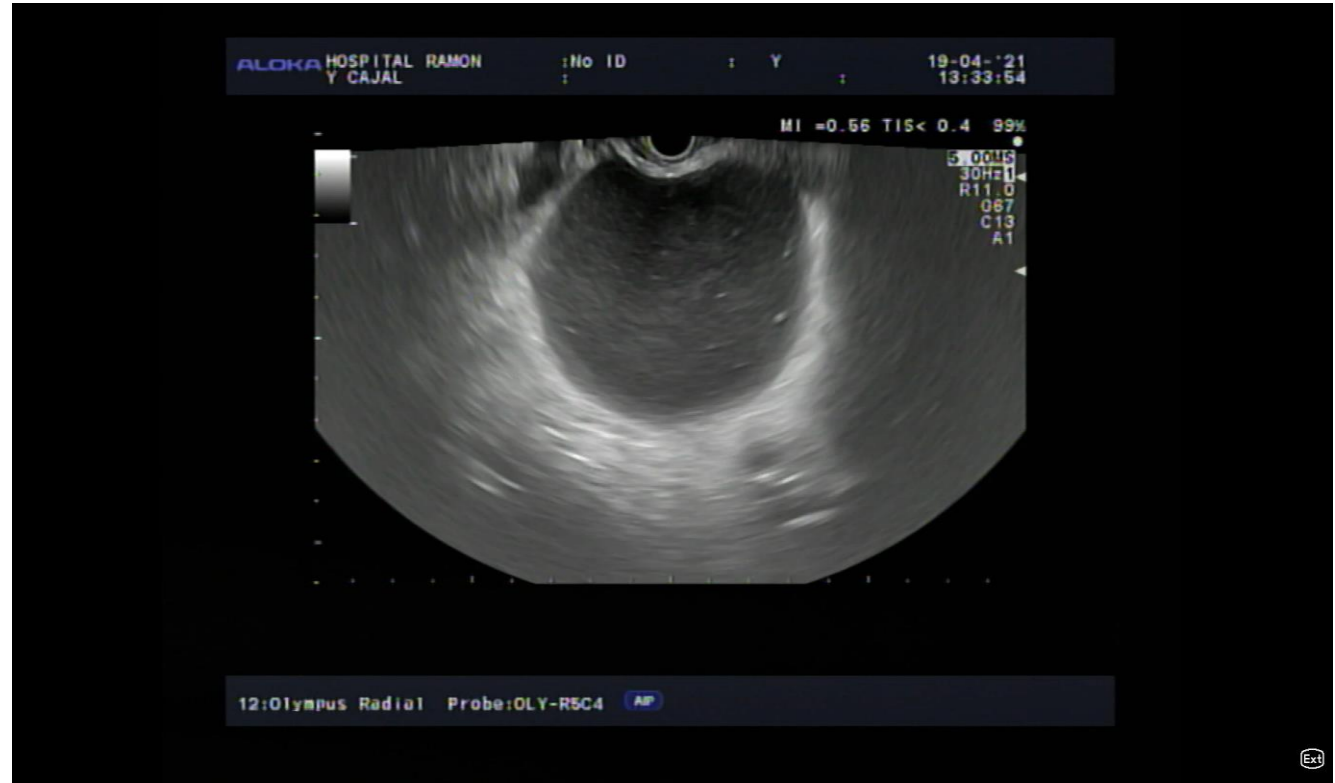


- Requieren cuidados de enfermería complejos
- Recolocación de catéteres
- Obstrucciones frecuentes
- Reducen la calidad de vida

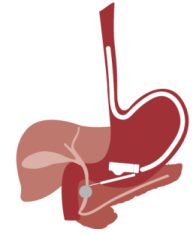
❑ Drenaje de bilioma



❑ Drenaje de colección post-esplenectomía



Postoperative abdominal collections drainage: Percutaneous versus guided by endoscopic ultrasound



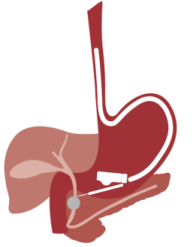
Félix Téllez-Ávila,^{1*} Guillermo Jesús Carmona-Aguilera,¹ Francisco Valdovinos-Andraca,¹ Luis Eduardo Casasola-Sánchez,¹ Adrian González-Aguirre,² Ivan Casanova-Sánchez,² Javier Elizondo-Rivera¹ and Miguel Ángel Ramírez-Luna¹

Departments of ¹Gastrointestinal Endoscopy and ²Imaging, National Institute of Medical Sciences and Nutrition Salvador Zubiran, Mexico City, Mexico

Characteristic	EUS-GD, n = 13 (%)	PD, n = 32 (%)	P-value
Male	6 (46.1)	20 (62.5)	0.25
Age, years [†]	41 (21–84)	52 (21–83)	0.19
No. procedures [†]	1 (1–3)	1 (1–4)	0.89
PFC size, cm [†]	6.5 (4–20.8)	7.6 (4–23)	0.92
Surgery type			0.50
Intestinal reconnection	3 (23.1)	8 (25.0)	
Distal pancreatectomy	3 (23.1)	2 (6.2)	
Biliary-digestive bypass	2 (15.3)	3 (9.4)	
Exploratory laparotomy	3 (23.1)	6 (18.8)	
Whipple	1 (7.7)	3 (9.4)	
Appendectomy	–	1 (3.1)	
Cholecystectomy	–	3 (9.4)	
Hepatectomy	–	1 (3.1)	
Splenectomy	–	2 (6.2)	
Gastric bypass	–	3 (9.4)	
OLT	1 (7.7)	–	

	EUS-GD, n = 13 (%)	PD, n = 32 (%)	P-value
Technical success	13 (100)	29 (90.6)	0.25
Clinical success	13 (100)	27 (84.4)	0.13
Recurrence	4 (30.7)	8 (25.0)	0.69
Hospital stay, days	22 (8–61)	27 (8–99)	0.35
Need for surgery	3 (23.1)	3 (9.4)	0.25
Costs, USD	8328 ± 1600	11 047 ± 1206	0.21
Complications	0 (0)	2 (6.2)	0.30
Mortality	1 (7.7)	2 (6.2)	0.90

EUS *versus* percutaneous management of postoperative pancreatic fluid collection: A systematic review and meta-analysis



10 estudios (n=239) drenaje **USE** vs 6 estudios (n=267) **Drenaje percutáneo**

	EUS	PCD	P
Technical success	97.3 (94.0-98.8, 0)	97.2 (93.9-98.7, 0)	0.93
Clinical success	93.2 (88.2-96.2, 0)	79.8 (70.0-87.0, 74)	0.002
Recurrence	9.4 (5.2-16.5, 39.7)	25.7 (14.3-41.7, 0)	0.02
Adverse events	9.3 (4.4-18.6, 33)	7.9 (3.6-16.6, 67.7)	0.77
Early adverse events	7.9 (4.5-13.2, 0)	NA	-
Delayed adverse events	6.3 (3.3-12.0, 0)	NA	-
Bleeding	6.1 (2.9-12.2, 0)	NA	-
Stent migration	6.5 (2.7-14.8, 0)	NA	-
Perforation	NA	3.3 (1.4-7.4, 0)	-

TABLE 3. Outcomes of technical and clinical success and adverse events

Outcome	Value
Overall technical success	44/47 (93.6%)
Site-specific technical success	
Transgastric	32/34 (94.1%)
Transduodenal	4/5 (80%)
Transrectal	8/8 (100%)
Overall clinical success	42/47 (89.3%)
Site-specific clinical success	
Transgastric	31/34 (91.2%)
Transduodenal	4/5 (80%)
Transrectal	7/8 (87.5%)
Adverse events	
Intraprocedural stent migration	2 (4.25%)
Postprocedural	3 (6.4%)
Stent migration	1 (2.1%)
Perforation	1 (2.1%)
Infection	1 (2.1%)

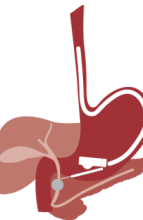
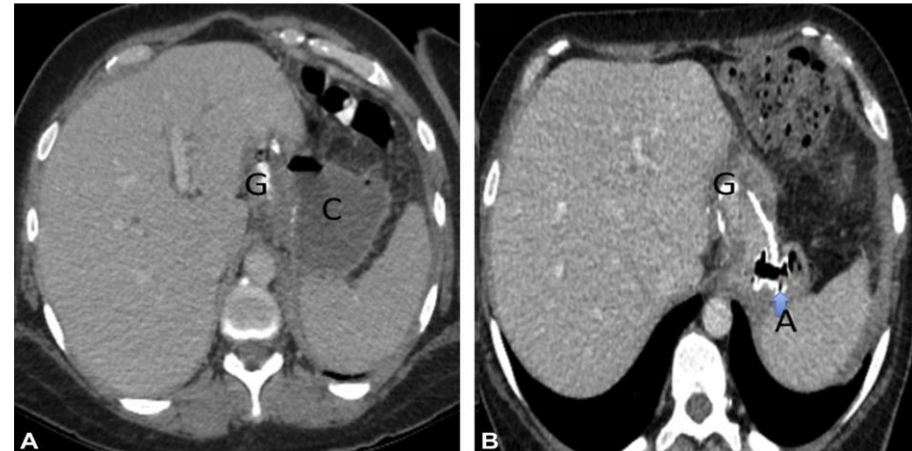
EUS-guided drainage of postsurgical fluid collections using lumen-apposing metal stents: a multicenter study



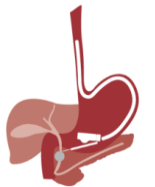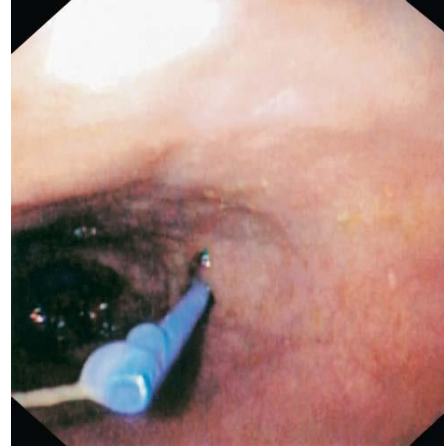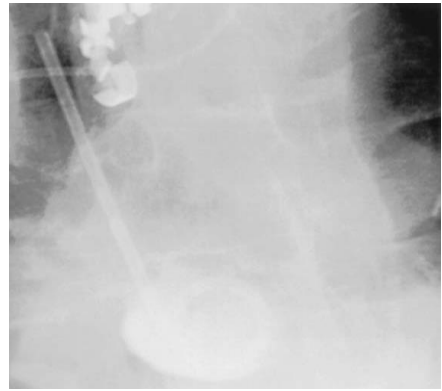
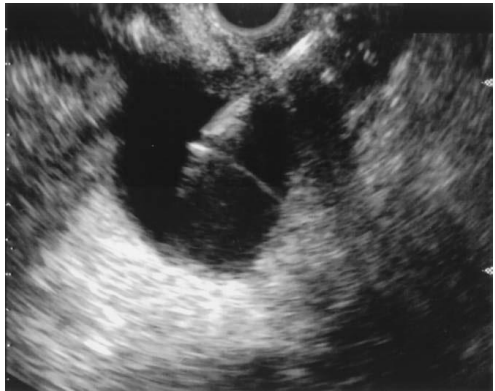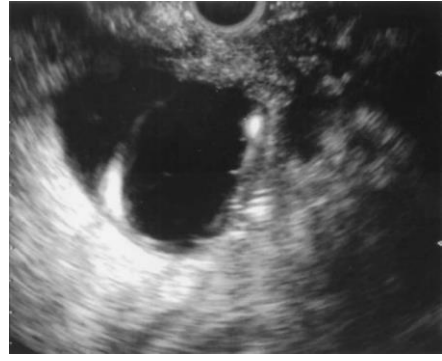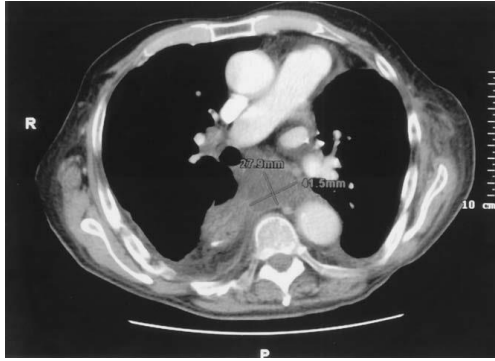Prashant R. Mudireddy, MD,¹ Amrita Sethi, MD,² Ali A. Siddiqui, MD,³ Douglas G. Adler, MD,⁴ Jose Nieto, DO,⁵ Harshit Khara, MD,¹ Arvind Trindade, MD,⁶ Sammy Ho, MD,⁷ Petros C. Benias, MD,⁶ Peter V. Draganov, MD,⁸ Dennis Yang, MD,⁸ Shaffer Mok, MD,¹ Bradley Confer, DO,¹ David L. Diehl, MD¹

Danville, Philadelphia, Pennsylvania; New York, New Hyde Park, Bronx, New York; Salt Lake City, Utah; Jacksonville, Gainesville, Florida, USA

- Multicéntrico (8 centros) retrospectivo (2012-2016)
- 47 pacientes / 26 cirugías pancreáticas



■ EUS drainage of **mediastinal abscess**. Kahaleh M, GIE 2004



DRENAJE DE ABSCESOS Y COLECCIONES MEDIASTÍNICAS

	N		Material	Tech, Clin S	Stent retrieval
Kahaleh GIE 2004	1	Ivor-Lewis	19G, 6-mm ballon, Single pigtail plastic stent, 7F x 4cm	Yes	3 months
Jonas Endoscopy 2005	1	Cystic metas	22G; Papilotom + 7F/4cm pigtail	Yes	6 weeks
Werhmann, GIE 2005	15	Post-Surgery Boerhave	19G,8-15-mm, 8Fr (x4) Mediastinal debridement	Yes (1 exitus/ embolism)	
Choi, Respiration 2012	1	lymphangioma	Single EBUS	Yes	NA
Saxena GIE 2014	1	Esophagectomy	19G, 4.4Fr catheter, double-lumen, balloon 10mm 2 double pigtails, 7F x 5cm	Yes	4 weeks
Gornals GIE 2015	1	Post-Surgery	19G, 8-mm balloon, LAMS 10-x10mm	Yes	7 days
Davarashilli Dig Endosc 2017	1	Bronc cyst	Single, EUS -FNA	Yes	NA

Endoscopic debridement of paraesophageal, mediastinal abscesses: a prospective case series

Till Wehrmann, MD, Nikos Stergiou, MD, Bernd Vogel, MD, Andrea Riphaut, MD,
Ferdinand Köckerling, MD, Markus B. Frenz, MD

Hannover, Germany

Background: Mediastinal abscesses after esophageal perforation or postoperative leakage nearly always require surgical intervention.

Methods: Patients with paraesophageal abscesses were treated with EUS-guided or endoscopic mediastinal puncture if the abscess was >2 cm and sepsis was present. Abscess cavities were entered with a 9.5-mm endoscope after balloon dilation to allow irrigation and drainage. Debris was removed with a Dormia basket. Concomitant pleural effusions were treated with transthoracic drains. Patients received intravenous antibiotics and enteral/parenteral nutrition.

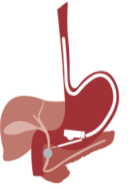
Results: Twenty patients fulfilled the entry criteria. Simple drainage was sufficient in 4 cases, and puncture was impossible in one case. Of the 15 treated patients (age 39-76 years, 5 women) the etiology of perforation was Boerhaave's syndrome (n = 8), anastomotic leak (n = 3), and iatrogenic perforation (n = 4). Debridement was successful in all cases and required a median of 5 daily sessions (range 3-10). All patients became afebrile, with a C-reactive protein < 5 mg/L within a median of 4 days (range 2-8 days). Esophageal defects were closed with endoclips (n = 7), fibrin glue (n = 4), metal stents (n = 1), or spontaneously healed (n = 3). One patient died from a massive pulmonary embolism one day after successful debridement (mortality 7%). No other complications were seen. Median follow-up was 12 months (range 3-40 months).

Conclusions: Nonoperative endoscopic transesophageal debridement of mediastinal abscesses appears safe and effective. (*Gastrointest Endosc* 2005;62:344-9.)

TABLE 2. Clinical course and outcome of 15 patients treated with transesophageal endoscopic debridement*

Mean no. performed endoscopic procedures	7.4 ± 3.0 (5-16)
Mean no. daily endoscopic debridements	5.0 ± 2.3 (3-10)
Mean time to normalization of temperature and C-reactive protein, d	4.5 ± 2.2 (2-8)
Mean days of inpatient stay	14.5 ± 5.6 (9-22)
Patients with resolution of abscess on CT, N	15/15
Procedure-related morbidity, N	0/15
Mortality, N	1/15 (6.7%)

DRENAJE de ABSCESOS MEDIASTÍNICOS por USE



- El manejo de colecciones y abscesos pélvicos e intrabdominales requiere un **enfoque multidisciplinar**
- El **drenaje por ecoendoscopia** es una alternativa terapéutica **segura y eficaz** al drenaje radiológico y quirúrgico (ausencia de ensayos clínicos comparativos de calidad)
- Experiencia positiva con **prótesis plásticas y prótesis metálicas**
- En abscesos pélvicos de más de 8 cm de diámetro el empleo de **catéteres de drenaje** para lavado puede resultar útil
- La **experiencia** en drenaje de **abscesos y colecciones mediastínicas** mediante ecoendoscopia es **limitada**, pero también **positiva** en los pocos casos descritos en la literatura

