

The best approach for sampling of pancreatic neuroendocrine tumors – EUS-FNA or EUS-FNB?



Author

Per Hedenström

Institution

Division of Medical Gastroenterology, Department of Internal Medicine, Sahlgrenska University Hospital, Gothenburg, Sweden

Bibliography

DOI <https://doi.org/10.1055/a-0959-6138> |
Endoscopy International Open 2019; 07: E1400–E1402
© Georg Thieme Verlag KG Stuttgart · New York
eISSN 2196-9736

Corresponding author

Dr Per Hedenström, Medicinmottagningen, Sahlgrenska Universitetssjukhuset, Blå Stråket 3, 413 35 Göteborg, Sweden
Fax: +46 31827458.
per.hedenstrom@vgregion.se

The limitations of transabdominal ultrasound in diagnosis of pancreatic diseases [1] were the driving force in developing endosonography (EUS) with the first echoendoscope being launched in 1980 [2]. The curvilinear array design of modern echoendoscope transducer heads enables EUS-guided sampling of lesions [3]. Traditionally, the principal sampling technique has been EUS-guided fine-needle aspiration (EUS-FNA) with open-tip needles designed for cytology [4].

Among all neoplasms originating from the pancreas, pancreatic neuroendocrine tumors (PanNETs) constitute a relatively rare entity. Incidence of PanNETs reportedly is increasing [5], and these tumors are challenging to diagnose with imaging alone [6], which implicates sampling of lesions suspected for PanNET. In addition, immunostaining for entity-specific tumor markers is required for reliable microscopic diagnosis [7].

Problematically, EUS-FNA is suboptimal in solid pancreatic lesions, with an 85% sensitivity for malignancy [8]. Furthermore, a majority of publications include mostly or exclusively pancreatic ductal adenocarcinomas [9, 10]. The few studies addressing PanNETs have shown varying diagnostic sensitivity for EUS-FNA, ranging from 47% [11] to 90% [12], (► **Fig. 1**).

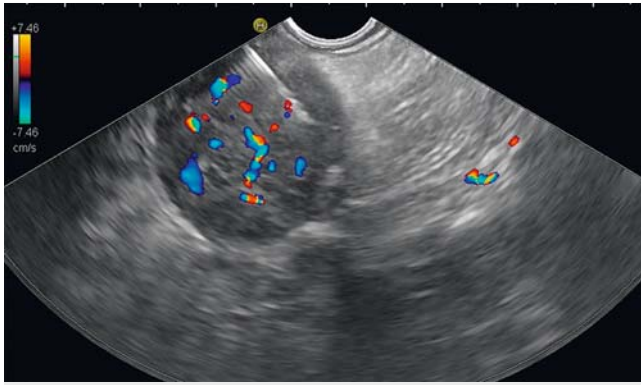
In recent years, a new generation of biopsy needles (EUS-FNB [fine-needle biopsy]) has been developed for acquisition of whole tissue samples [13–15]. At present, it is not known whether FNB needles and processing of histology specimens can improve diagnosis of suspected PanNETs and motivate a shift from EUS-FNA.

In this issue of Endoscopy International Open, Eusebi et al contribute new knowledge on this important topic by investigating the diagnostic yield and sensitivity of EUS-FNB. The study has a retrospective design and it was conducted in a two-center setting during a 13-year period (2004–2017). Ex-

clusively PanNETs were included and 102 EUS-guided sampling procedures were analyzed in 91 patients. Sampling was performed either by EUS-FNA (22/25-gauge needle), by EUS-FNB, or by both modalities. From 2004 to 2011, a 19-gauge Quick-Core FNB-needle (Cook Medical, Limerick, Ireland) was used while using a 22/25-gauge reverse bevel ProCore FNB-needle (Cook Medical) or a 22-gauge opposing bevel SharkCore FNB-needle (Medtronic, Minneapolis, Minnesota, United States) from 2011 to 2017.

The authors report that the diagnostic yield, i. e. the acquisition of a macroscopically adequate sample, was 85% (35/41) in EUS-FNB and 78% (69/89) in EUS-FNA. In an intention-to-diagnose analysis, the final diagnostic sensitivity of EUS-FNB and EUS-FNA was 80% (33/41) and 69% (61/89), respectively. In dual sampling procedures (n=28), the combination of EUS-FNB and EUS-FNA had a significantly higher diagnostic yield than EUS-FNA alone, 96% (27/28) vs 75% (21/28), $P=0.023$. Either of the two techniques was diagnostic for PanNET in all of the 27 adequate samples. Seven EUS-FNA samples were inadequate for a conclusive diagnosis and in six of seven of these cases (86%), the EUS-FNB sample was diagnostic. On the other hand, in six cases EUS-FNB was non-diagnostic and in all of these six cases, EUS-FNA was diagnostic. No noticeable difference in diagnostic performance was seen between the three FNB needles. No adverse events were recorded after EUS-FNB, which is a finding in line with the results of other studies [14, 16].

The study by Eusebi et al is important because a high number of patients were included and small PanNETs were not excluded. Moreover, few studies on EUS-FNB have been performed in cohorts containing exclusively PanNETs [17]. There are some weaknesses in the study discussed by the authors. As



► **Fig. 1** EUS-FNA of a hypoechoic, highly vascularized PanNET.

an example, different types of FNB needles were used, one of which – the Quick-Core needle – has been discarded by most endosonographers due to a high frequency of technical failures and a low diagnostic accuracy [18].

According to a recent study on solid pancreatic lesions [19], the accuracy of the reverse bevel FNB needle was found inferior (74%) to that of the opposing bevel FNB needle (92%). The number of cases sampled by EUS-FNB in the study by Eusebi and co-workers was not sufficient to determine which FNB needle is the superior one. Furthermore, there are yet other FNB needles available, such as the Franseen tip needle [20].

Importantly, the comparison of EUS-FNB and EUS-FNA is not exclusively a comparison between needles but rather a comparison between two different diagnostic approaches, which also include sampling maneuvers, sample preparation, and sample assessment by the (cyto)pathologist. Poor quality at any of these steps will result in a non-diagnostic work-up. This is a crucial aspect to keep in mind when interpreting studies investigating the accuracy of EUS-guided sampling.

Even though Eusebi and co-workers present valuable new data, it remains to be decided to what extent EUS-FNB may be superior to EUS-FNA in the work-up of suspected PanNETs. This study, like others [21], shows that EUS-FNB is a useful adjunct to EUS-FNA. Whether EUS-FNB should be used as the primary technique, or as a rescue technique after an unsuccessful EUS-FNA, warrants further investigation. Studies analyzing the benefit of combining a 25-gauge FNA needle and a 22-gauge reverse bevel FNB needle in the same solid pancreatic lesion have shown contradictory results [21, 22]. Moreover, such an approach implicates increased costs and a prolonged procedural time. Therefore, dual-modality sampling should be considered only in strictly selected cases. Future studies focusing on PanNETs should be designed as prospective, randomized trials using a predefined set of FNA and FNB needles with surgical specimens as the reference standard.

Competing interests

None

References

- [1] DiMagno EP, Malagelada JR, Taylor WF et al. A prospective comparison of current diagnostic tests for pancreatic cancer. *N Engl J Med* 1977; 297: 737–742
- [2] DiMagno EP, Buxton JL, Regan PT et al. Ultrasonic endoscope. *Lancet* 1980; 1: 629–631
- [3] Vilmann P, Khattar S, Hancke S. Endoscopic ultrasound examination of the upper gastrointestinal tract using a curved-array transducer. A preliminary report. *Surg Endosc* 1991; 5: 79–82
- [4] Vilmann P, Hancke S. A new biopsy handle instrument for endoscopic ultrasound-guided fine-needle aspiration biopsy. *Gastrointest Endosc* 1996; 43: 238–242
- [5] Yao JC, Hassan M, Phan A et al. One hundred years after “carcinoid”: epidemiology of and prognostic factors for neuroendocrine tumors in 35,825 cases in the United States. *J Clin Oncol* 2008; 26: 3063–3072
- [6] Delbeke D, Pinson CW. Pancreatic tumors: role of imaging in the diagnosis, staging, and treatment. *J Hepatobiliary Pancreat Surg* 2004; 11: 4–10
- [7] Falconi M, Bartsch DK, Eriksson B et al. ENETS Consensus Guidelines for the management of patients with digestive neuroendocrine neoplasms of the digestive system: well-differentiated pancreatic non-functioning tumors. *Neuroendocrinology* 2012; 95: 120–134
- [8] Hewitt MJ, McPhail MJ, Possamai L et al. EUS-guided FNA for diagnosis of solid pancreatic neoplasms: a meta-analysis. *Gastrointest Endosc* 2012; 75: 319–331
- [9] Alatawi A, Beuvon F, Grabar S et al. Comparison of 22G reverse-beveled versus standard needle for endoscopic ultrasound-guided sampling of solid pancreatic lesions. *United Eur Gastroenterol J* 2015; 3: 343–352
- [10] Hebert-Magee S, Bae S, Varadarajulu S et al. The presence of a cytopathologist increases the diagnostic accuracy of endoscopic ultrasound-guided fine needle aspiration cytology for pancreatic adenocarcinoma: a meta-analysis. *Cytopathology* 2013; 24: 159–171
- [11] Voss M, Hammel P, Molas G et al. Value of endoscopic ultrasound guided fine needle aspiration biopsy in the diagnosis of solid pancreatic masses. *Gut* 2000; 46: 244–249
- [12] Atiq M, Bhutani MS, Bektas M et al. EUS-FNA for pancreatic neuroendocrine tumors: a tertiary cancer center experience. *Dig Dis Sci* 2012; 57: 791–800
- [13] Bang JY, Hebert-Magee S, Navaneethan U et al. EUS-guided fine needle biopsy of pancreatic masses can yield true histology: results of a randomised trial. *Gut* 2018; 67: 2081–2084
- [14] Iglesias-Garcia J, Poley JW, Larghi A et al. Feasibility and yield of a new EUS histology needle: results from a multicenter, pooled, cohort study. *Gastrointest Endosc* 2011; 73: 1189–1196
- [15] Jovani M, Abidi WM, Lee LS. Novel fork-tip needles versus standard needles for EUS-guided tissue acquisition from solid masses of the upper GI tract: a matched cohort study. *Scand J Gastroenterol* 2017; 52: 784–787
- [16] Bang JY, Hebert-Magee S, Trevino J et al. Randomized trial comparing the 22-gauge aspiration and 22-gauge biopsy needles for EUS-guided sampling of solid pancreatic mass lesions. *Gastrointest Endosc* 2012; 76: 321–327
- [17] Witt BL, Factor RE, Chadwick BE et al. Evaluation of the SharkCore((R)) needle for EUS-guided core biopsy of pancreatic neuroendocrine tumors. *Endoscopic ultrasound* 2018; 7: 323–328
- [18] Fernandez-Esparrach G, Sendino O, Sole M et al. Endoscopic ultrasound-guided fine-needle aspiration and trucut biopsy in the diagnosis of gastric stromal tumors: a randomized crossover study. *Endoscopy* 2010; 42: 292–299

- [19] Nayar MK, Paranandi B, Dawwas MF et al. Comparison of the diagnostic performance of 2 core biopsy needles for EUS-guided tissue acquisition from solid pancreatic lesions. *Gastrointest Endosc* 2017; 85: 1017–1024
- [20] Mitri RD, Rimbasi M, Attili F et al. Performance of a new needle for endoscopic ultrasound-guided fine-needle biopsy in patients with pancreatic solid lesions: A retrospective multicenter study. *Endosc Ultrasound* 2018; 7: 329–334
- [21] Hedenstrom P, Demir A, Khodakaram K et al. EUS-guided reverse bevel fine-needle biopsy sampling and open tip fine-needle aspiration in solid pancreatic lesions - a prospective, comparative study. *Scand J Gastroenterol* 2018; 53: 231–237
- [22] Berzosa M, Villa N, El-Serag HB et al. Comparison of endoscopic ultrasound guided 22-gauge core needle with standard 25-gauge fine-needle aspiration for diagnosing solid pancreatic lesions. *Endosc Ultrasound* 2015; 4: 28–33