

Role of EUS for the evaluation of mediastinal adenopathy

This is one of a series of statements discussing the use of GI endoscopy in common clinical situations. The Standards of Practice Committee of the American Society for Gastrointestinal Endoscopy prepared this text. In preparing this guideline, a search of the medical literature was performed using PubMed. Additional references were obtained from the bibliographies of the identified articles and from recommendations of expert consultants. When few or no data exist from well-designed prospective trials, emphasis is placed on results from large series and reports from recognized experts. Guidelines for appropriate use of endoscopy are based on a critical review of the available data and expert consensus at the time that the guidelines are drafted. Further controlled clinical studies may be needed to clarify aspects of this guideline. This guideline may be revised as necessary to account for changes in technology, new data, or other aspects of clinical practice. The recommendations were based on reviewed studies and were graded on the strength of the supporting evidence (Table 1).¹ The strength of individual recommendations is based on both the aggregate evidence quality and an assessment of the anticipated benefits and harms. Weaker recommendations are indicated by phrases such as “we suggest,” whereas stronger recommendations are typically stated as “we recommend.”

This guideline is intended to be an educational device to provide information that may assist endoscopists in providing care to patients. This guideline is not a rule and should not be construed as establishing a legal standard of care or as encouraging, advocating, requiring, or discouraging any particular treatment. Clinical decisions in any particular case involve a complex analysis of the patient's condition and available courses of action. Therefore, clinical considerations may lead an endoscopist to take a course of action that varies from these guidelines.

Mediastinal lymphadenopathy may be detected by radiographic imaging (eg, chest radiograph, CT, or positron emission tomography [PET]) or by the presence of extrinsic compression of the esophagus detected during upper endoscopy (EGD). Malignant (eg, metastatic cancer, lymphoma), infectious (eg, tuberculosis, histoplasmosis), and systemic processes (eg, sarcoidosis) can cause mediastinal adenopathy. EUS can both identify and guide FNA of

nodes. In the posterior and inferior mediastinum, EUS visualizes and directs transesophageal FNA of adenopathy. In the anterior mediastinum, endobronchial US (EBUS) visualizes and directs transbronchial FNA of mediastinal adenopathy. This guideline is an update of a previous ASGE document² and discusses the role of EUS and EBUS in the evaluation of mediastinal adenopathy. The role of EUS in the evaluation of esophageal cancer is discussed in a separate guideline.³

IMAGING OF MEDIASTINAL ADENOPATHY BY EUS AND EBUS

EUS

Radial EUS performed within the esophagus provides an image of the mediastinum similar to an axial view on a CT scan. FNA cannot be performed with the radial EUS endoscope. The linear EUS endoscope produces an approximately 180-degree image relative to the endoscope tip and allows FNA. EUS can identify lymph nodes in the posterior and inferior mediastinum. Stations 8 and 9 are accessible, as are posterior nodes at station 7 (Fig. 1). If enlarged, station 5 nodes may be accessible.⁴⁻⁷ Nodes within the anterior upper mediastinum are inaccessible to EUS because air within the trachea interferes with US imaging.⁸ Paratracheal nodes at station 4L are closer to the esophagus and accessible, but 4R nodes are usually not, unless enlarged.⁸ Intrapulmonary nodes lie within the visceral pleura and are inaccessible by EUS.

EBUS

EBUS can identify lymph nodes in the anterior and superior mediastinum (stations 1, 2, 4, and anterior nodes of station 7) as well as intrapulmonary nodes (stations 10, 11, and 12).⁹ Inferior mediastinal nodes are not in close proximity to the trachea or bronchi and are inaccessible by EBUS.

OBTAINING TISSUE FROM MEDIASTINAL ADENOPATHY

CT and PET scans can detect abnormal mediastinal lymphadenopathy, but are usually inadequate for diagnosis and locoregional staging of malignancy.¹⁰⁻¹⁶ Thus, tissue sampling is often required.¹³ Mediastinal tissue can be obtained by needle techniques or surgical biopsy. Needle techniques include transthoracic needle aspirate (TTNA), transbronchial needle aspirate (TBNA), EBUS-FNA, EUS-

TABLE 1. GRADE system for rating the quality of evidence for guidelines

Quality of evidence	Definition	Symbol
High quality	Further research is very unlikely to change our confidence in the estimate of effect.	⊕⊕⊕⊕
Moderate quality	Further research is likely to have an important impact on our confidence in the estimate of effect and may change the estimate.	⊕⊕⊕○
Low quality	Further research is very likely to have an important impact on our confidence in the estimate of effect and is likely to change the estimate.	⊕⊕○○
Very low quality	Any estimate of effect is very uncertain.	⊕○○○

Adapted from Guyatt et al.¹

FNA, and EUS needle core biopsy. Surgical biopsy techniques include cervical mediastinoscopy, extended cervical mediastinoscopy, anterior mediastinoscopy, and video-assisted thoracoscopy (VATS).

Needle techniques

TTNA. TTNA can be performed by guidance of a needle by CT scan or fluoroscopy and has a sensitivity of 90% for malignancy when performed in patients with extensive adenopathy.^{13,17-22} With TTNA of the mediastinum, pneumothorax requiring treatment has been reported in 10% of patients.¹³

TBNA. TBNA of mediastinal adenopathy involves the passage of a needle transbronchially during bronchoscopy. Enlarged subcarinal lymph nodes (station 7) are readily sampled by TBNA. Paratracheal nodes can be sampled as well, with highest success when extensive mediastinal adenopathy is present.^{13,23-27} With TBNA, pneumothorax has been reported in 0.4% to 5.5% of cases.^{22,28,29}

EBUS with FNA. EBUS is capable of imaging anterior and superior mediastinal lymph nodes and directing real-time transbronchial needle aspiration of these nodes. Hilar nodes can also be sampled. EBUS can detect and guide needle aspiration of lymph nodes as small as 5 mm.⁹ Systematic reviews of EBUS report major complication rates as high as 0.05%,^{30,31} including pneumothorax and respiratory failure requiring ventilation.

EUS with FNA. Linear EUS is capable of imaging and directing real-time FNA of nodes as small as 5 mm.³² EUS-FNA of lymph nodes in the mediastinum performed in patients with suspected lung cancer has a complication rate of 0.2%.¹³

Surgical techniques

Cervical mediastinoscopy. Cervical mediastinoscopy is a surgical approach for sampling of superior and anterior mediastinal adenopathy. With the patient under general anesthesia, biopsies of nodal stations 1, 2, 3, 4, and anterior nodes of 7 can be performed.¹³ Complete lymph node excision can also be performed.³³ This typically outpatient surgical procedure³⁴⁻³⁶ has a morbidity rate of 1% to 2% and a mortality rate of 0.05% to 0.08%.^{13,37}

Anterior mediastinoscopy and extended cervical mediastinoscopy. Anterior mediastinoscopy is performed to obtain biopsy samples of enlarged station 5 nodes.¹³ A complication rate of 6.8%, including transient ischemia, pneumothorax, bleeding, and nerve injury, has been reported.^{38,39}

Extended cervical mediastinoscopy has been less commonly performed than anterior mediastinoscopy and is another means by which station 5 nodes can undergo biopsy.^{13,40-42} Extended cervical mediastinoscopy has a complication rate of 2%,⁴³ including stroke and aortic injury.^{13,43-45}

VATS. VATS is performed with the patient under general anesthesia to perform a biopsy of, and sometimes excise, lymph nodes. Collapse of 1 lung is usually necessary; therefore, the procedure typically evaluates either the right or left mediastinum. When the left mediastinum is studied, thoracoscopy can readily access nodal stations 5 and 6. VATS readily accesses the right paratracheal nodes (stations 2 and 4), subcarinal nodes (station 7), and inferior mediastinal nodes (stations 8 and 9).¹³ The morbidity of VATS is approximately 2%.¹³

EUS FOR THE EVALUATION OF MALIGNANT ADENOPATHY

Lung cancer

Lung cancer is the most frequent cause of cancer death in the United States⁴⁶ and in the world.⁴⁷ Staging and treatment of lung cancer are determined by radiologic imaging and tissue diagnosis. The American Joint Committee on Cancer stages nodal metastases with lung cancer anatomically.⁴⁸

A CT scan of the chest with imaging of the liver and adrenal glands should be performed in patients with suspected or known lung cancer who may undergo treatment.¹² Mediastinal lymph nodes with a short-axis diameter of 1 cm or larger are considered abnormal and should raise suspicion of nodal metastases.¹³ A PET scan or a combined CT/PET scan may be helpful in detecting local or distant metastases.¹²

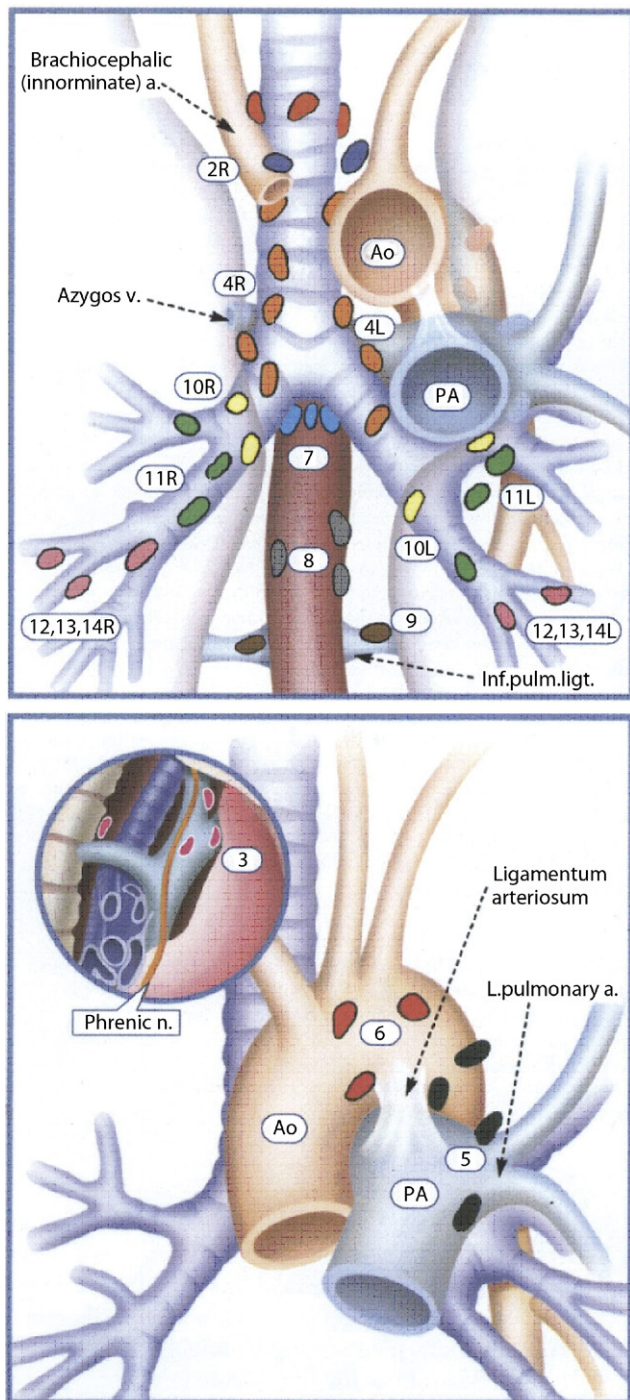


Figure 1. Mediastinal adenopathy. EUS-FNA can access stations 2, 4, 5, 7, 8, and 9 (2, 4R, and 5 access is variable). EBUS-FNA can access stations 1, 2, 4, 7, 10, 11, and 12. Ao, aorta; PA, pulmonary artery. (Reprinted from Mountain and Dresler,¹⁰⁴ with permission.)

N1 disease is defined as tumor spread to peribronchial, hilar, and intrapulmonary nodes on the same side of the primary lesion. N2 disease involves ipsilateral mediastinal and/or subcarinal lymph nodes. N3 disease involves contralateral nodal spread. In general, patients with mediastinal nodal metastases (ie, N2 or N3) are unlikely to benefit

from surgical resection.⁴⁹ However, neither CT nor PET scans are sensitive or specific enough for clinical staging of lung cancer, and diagnosis of tumor tissue or sampling of mediastinal nodes is frequently required to guide treatment.¹³ Centrally located malignancies may involve the esophageal wall, which can be evaluated with EUS. A full discussion of the staging of lung cancer is beyond the scope of this document. However, EUS and EBUS have a role in assisting in the staging of patients with lung cancer.

EUS in the evaluation of lung cancer

EUS-FNA of adenopathy. In patients with lung cancer, mediastinal lymph nodes with a round shape, sharp margins, and a short axis greater than 8.3 mm are more likely to be malignant. When all 3 features are present, the probability of a malignant node is 63%.⁵⁰ However, because all features are present in only a minority of cases and image interpretation alone cannot distinguish benign from malignant nodes, FNA of nodes is recommended.⁵¹

When performing EUS-FNA of mediastinal adenopathy, tissue should be first obtained from sites that would provide the highest stage. Most studies of EUS-FNA of nodes in patients with suspected lung cancer were performed when imaging showed mediastinal nodes 1 cm or larger the in short-axis diameter at locations amenable to sampling by EUS.^{5,8,13,52-59} In these studies, the sensitivity of EUS-FNA was approximately 90%.¹³ Specificity in nearly all the studies was 100%, but these studies considered positive FNA an end point and did not verify the result. One study verified positive EUS-FNA by surgical excision of nodes. In this study, EUS-FNA had a false-positive rate of 2%.⁵³

EUS with FNA is not highly accurate for staging station 5 nodes,⁵⁹ with an accuracy of only 66% in 1 retrospective series.⁴ EUS-FNA of station 6 has been described, but the approach requires transaortic passage of the needle, and further study of the safety of this approach is required.⁶⁰

EUS-FNA of distant metastases. With lung cancer, the liver and adrenal glands are common sites of distant metastasis.⁶¹ EUS-FNA can be performed for suspected metastases of the liver,⁶² and occasionally EUS will detect metastases not identified by previous imaging.⁶³ EUS with FNA of the left and occasionally the right adrenal gland^{64,65} can be performed when malignant metastasis is suspected. EUS-FNA of the left adrenal gland in a few small series was performed without complication,⁶⁶⁻⁶⁸ although 1 episode of hemorrhage without serious complication was reported.⁶⁹

EUS-FNA after neoadjuvant therapy. Neoadjuvant therapy followed by surgery in patients with confirmed N2 disease and stage III non-small cell lung cancer has not shown survival benefit.⁴⁹ EUS after neoadjuvant treatment in 1 small series had a negative predictive value of 67%,⁷⁰ whereas another small series had a negative predictive value of 91%.⁷¹ In the studies, EUS-FNA was performed in all patients, regardless of whether imaging suggested response to treatment.

EBUS in the evaluation of lung cancer

EBUS-FNA of adenopathy. In patients with lung cancer, lymph nodes imaged by EBUS that have central necrosis, heterogeneous echogenicity, round shape with distinct margin, and a short-axis diameter greater than 1 cm are more likely to be malignant⁷²; the presence of 1 or more of these features may guide FNA in the mediastinum. EBUS assesses and potentially samples the same nodal stations as cervical mediastinoscopy. Studies have reported wide-ranging sensitivity (79%-95%)¹³ with specificity frequently reported as 100%, but the studies do not verify positive FNA results. However, the false-negative rate of EBUS is 24%, whereas mediastinoscopy has a false-negative rate of approximately 10%.¹³ Therefore, it has been recommended that negative findings on EBUS should be followed with mediastinoscopy or other surgical evaluation of nodal stations before proceeding with resection of lung cancer.¹³

Combined EUS and EBUS of the mediastinum in patients with lung cancer

Combined EUS and EBUS have been performed to evaluate the entire mediastinum without a surgical procedure. In patients with known or suspected lung cancer and an enlarged mediastinal lymph node (≥ 1 cm) on CT, EUS and EBUS were performed with a sensitivity of 96% and negative predictive value of 96%.⁷³ In this study, the prevalence of malignant mediastinal metastases was 52%.

In patients who appear to have resectable lung cancer (ie, no mediastinal adenopathy) on CT and/or PET, the prevalence of mediastinal metastases is still 20% to 25%.¹² These patients may benefit from combined EUS and EBUS. In a study in which CT showed no evidence of enlarged mediastinal nodes in patients with suspected lung cancer, EUS followed by EBUS performed in 1 setting had a positive predictive value of 91% and a negative predictive value of 91%.⁷⁴ The prevalence of malignant mediastinal metastases in this study was 22%. Another study performed EUS and EBUS in patients with suspected lung cancer who underwent CT and PET.⁷⁵ In patients in whom CT and/or PET showed mediastinal nodes (≥ 1 cm), the negative predictive value of combined EUS and EBUS was 100%. When CT and PET showed no mediastinal adenopathy, combined EUS and EBUS had a negative predictive value of 94%. The prevalence of malignancy was 20% in the subgroup with negative findings on CT and PET, as determined by cytology diagnosis and surgical confirmation. Patients who were not surgical candidates were followed for at least 1 year.

Cost analyses of EUS-FNA and EBUS-FNA with lung cancer

Cost analyses compared EUS-FNA, EBUS-FNA, and combined EUS/EBUS-FNA with mediastinoscopy in the evaluation of mediastinal adenopathy with suspected lung cancer.⁷⁶⁻⁷⁸ One study suggested that EUS-FNA is more

cost-effective than mediastinoscopy, provided that the location of potential mediastinal metastases is in station 5, 6, or 7.⁷⁶ A second study determined that EUS-FNA was more cost-effective than mediastinoscopy, but assumes that EUS-FNA always successfully detects and samples the abnormal node on CT scan and that 50% of mediastinoscopies are performed on an inpatient basis.⁷⁷ A third study determined that EUS-FNA is most cost-effective if the probability of lymph node metastases is less than 32%; above this, combined EUS and EBUS are preferred.⁷⁸ However, the study also assumes that 50% of mediastinoscopies are performed on an inpatient basis.

Systemic and infectious diseases

Lymphoma. Lymphoma may present with diffuse mediastinal adenopathy. EUS-FNA or EBUS-FNA of mediastinal adenopathy may be helpful in diagnosing lymphoma, particularly in patients with a previous diagnosis in whom recurrence is suspected.⁷⁹⁻⁸⁴ Tissue samples should be sent for immunophenotyping by flow cytometry, which requires special tissue media.

Although EUS-FNA and EBUS-FNA may be helpful in diagnosing mediastinal lymphoma, the sensitivity is reported at 73% to 80%.^{80-82,85} Given the limited sensitivity of these modalities, excisional biopsy should be considered when FNA is negative.^{84,86} In addition, prognostic information for certain subtypes of lymphoma requires tissue architecture, which cytology is unable to provide. For example, Hodgkin's lymphoma and T-cell lymphoma are difficult to diagnosis by cytology alone.^{81,87} A 19-gauge needle designed to obtain core biopsy samples by EUS may provide a histologic tissue sample for pathology review.^{81,88,89} Further study is necessary to determine the yield and the role of EUS-FNA and EBUS-FNA in the evaluation mediastinal adenopathy attributed to suspected lymphoma.

Sarcoidosis. Sarcoidosis is a systemic inflammatory process of unclear etiology that causes noncaseating granulomatous disease. Bihilar mediastinal adenopathy can be found incidentally with indolent disease, and active disease symptoms include coughing, shortness of breath, fever, weight loss, and fatigue. Sarcoidosis is a clinical diagnosis made with supporting radiologic, laboratory, and, sometimes, histopathologic studies. Because nodal tissue does not provide a specific diagnosis for sarcoidosis, the role of EUS and EBUS in the diagnosis of sarcoidosis is not defined. In many cases, EUS-FNA and EBUS-FNA are performed in cases of suspected sarcoidosis to exclude malignancy.⁹⁰⁻⁹⁸ Noncaseating granulomas are difficult to identify from cytopathology taken by FNA, although multiple passes taken for cell block may be helpful.⁹¹ EUS with a large-bore needle to obtain histology has been described.⁹⁹

Infection. Tuberculosis and other infections can cause systemic illness with mediastinal adenopathy. Diagnosis of infection by EUS-FNA and EBUS-FNA has been described.¹⁰⁰⁻¹⁰² When systemic infection is a possible etiology of diffuse adenopathy, specimens obtained by EUS-

FNA or EBUS-FNA should be sent for acid-fast stain and culture as well as for fungal culture. The yield of these cultures from samples taken by EUS or EBUS has not been well studied. Needle core biopsy has been described as identifying granulomas from mediastinal tissue with tuberculosis.⁸⁹ Mediastinal-esophageal fistulae after EUS-FNA of tuberculosis of the mediastinum have been reported.¹⁰³

RECOMMENDATIONS

1. In patients with known or suspected potentially resectable lung cancer whose imaging reveals mediastinal adenopathy, we suggest that EUS-FNA be performed in patients with paraesophageal, posterior, and inferior mediastinal adenopathy, if the expertise is available. ⊕⊕○○ Similarly, we suggest that EBUS-FNA be performed in patients with paratracheal mediastinal adenopathy if this information adds to the staging of the lung cancer. ⊕⊕○○ EUS-FNA and EBUS-FNA have been shown to be safe, and potentially cost-effective compared with mediastinoscopy, although individually each has a high false-negative rate that warrants surgical confirmation before proceeding with resection.
2. In patients with known or suspected potentially resectable lung cancer whose imaging shows no evidence of mediastinal adenopathy, we suggest combined EUS-FNA/EBUS-FNA for staging. ⊕⊕○○ Combined EUS-FNA/EBUS-FNA has been shown to have a negative predictive value comparable to that of mediastinoscopy. However, expertise in both modalities is not readily available at most institutions.
3. In patients who require evaluation of station 5 nodes, we suggest EUS-FNA as a safe and cost-effective first-line approach. ⊕⊕○○
4. When EUS-FNA is performed for suspected lymphoma, we suggest that specimens be sent for flow cytometry and, if technically possible, that EUS core biopsy specimens be obtained because immunophenotyping and histology are often required for diagnosis and subtyping of lymphoma. ⊕⊕○○
5. When EUS-FNA of mediastinal adenopathy is performed in patients with suspected infected nodes, we recommend that aspirate be sent for special stain and culture (eg, acid-fast stain, fungal culture). ⊕○○○

DISCLOSURE

The following authors disclosed financial relationships relevant to this publication: Dr Decker: consultant to Facet Biotechnology; Dr Fanelli: honoraria from Ethicon, consultant to RTI; owner/governor: New Wave Surgical Corp; Dr Jain: research support from Barrx; Dr Evans: consultant to Cook Medical. The other authors disclosed no financial relationships relevant to this publication.

REFERENCES

1. Guyatt GH, Oxman AD, Vist GE, et al. GRADE: an emerging consensus on rating quality of evidence and strength of recommendations. *BMJ* 2008;336:924-6.
2. Jacobson BC, Hirota WK, Goldstein JL, et al. The role of EUS for evaluation of mediastinal adenopathy. *Gastrointest Endosc* 2003;58:819-21.
3. Jacobson BC, Hirota WK, Baron TH, et al. The role of endoscopy in the assessment and treatment of esophageal cancer. *Gastrointest Endosc* 2003;57:817-22.
4. Cerfolio RJ, Bryant AS, Eloubeidi MA. Accessing the aortopulmonary window (#5) and the paraaortic (#6) lymph nodes in patients with non-small cell lung cancer. *Ann Thorac Surg* 2007;84:940-5.
5. Silvestri GA, Hoffman BJ, Bhutani MS, et al. Endoscopic ultrasound with fine-needle aspiration in the diagnosis and staging of lung cancer. *Ann Thorac Surg* 1996;61:1441-5; discussion 5-6.
6. Eloubeidi MA, Cerfolio RJ, Chen VK, et al. Endoscopic ultrasound-guided fine needle aspiration of mediastinal lymph node in patients with suspected lung cancer after positron emission tomography and computed tomography scans. *Ann Thorac Surg* 2005;79:263-8.
7. Wallace MB, Ravenel J, Block MI, et al. Endoscopic ultrasound in lung cancer patients with a normal mediastinum on computed tomography. *Ann Thorac Surg* 2004;77:1763-8.
8. Annema JT, Hoekstra OS, Smit EF, et al. Towards a minimally invasive staging strategy in NSCLC: analysis of PET positive mediastinal lesions by EUS-FNA. *Lung Cancer* 2004;44:53-60.
9. Herth FJ, Eberhardt R, Vilmann P, et al. Real-time endobronchial ultrasound guided transbronchial needle aspiration for sampling mediastinal lymph nodes. *Thorax* 2006;61:795-8.
10. Steinert HC, Hauser M, Allemann F, et al. Non-small cell lung cancer: nodal staging with FDG PET versus CT with correlative lymph node mapping and sampling. *Radiology* 1997;202:441-6.
11. Graeber GM, Gupta NC, Murray GF. Positron emission tomographic imaging with fluorodeoxyglucose isofiscious in evaluating malignant pulmonary disease. *J Thorac Cardiovasc Surg* 1999;117:719-27.
12. Silvestri GA, Gould MK, Margolis ML, et al. Noninvasive staging of non-small cell lung cancer: ACCP evidenced-based clinical practice guidelines (2nd edition). *Chest* 2007;132:1785-2015.
13. Detterbeck FC, Jantz MA, Wallace M, et al. Invasive mediastinal staging of lung cancer: ACCP evidence-based clinical practice guidelines (2nd edition). *Chest* 2007;132:2025-205.
14. Gupta NC, Graeber GM, Bishop HA. Comparative efficacy of positron emission tomography with fluorodeoxyglucose in evaluation of small (<1 cm), intermediate (1 to 3 cm), and large (>3 cm) lymph node lesions. *Chest* 2000;117:773-8.
15. Izbicki JR, Thetter O, Karg O, et al. Accuracy of computed tomographic scan and surgical assessment for staging of bronchial carcinoma. A prospective study. *J Thorac Cardiovasc Surg* 1992;104:413-20.
16. Yasukawa T, Yoshikawa K, Aoyagi H, et al. Usefulness of PET with 11C-methionine for the detection of hilar and mediastinal lymph node metastasis in lung cancer. *J Nucl Med* 2000;41:283-90.
17. Bocking A, Klose KC, Kyll HJ, et al. Cytologic versus histologic evaluation of needle biopsy of the lung, hilum and mediastinum. Sensitivity, specificity and typing accuracy. *Acta Cytol* 1995;39:463-71.
18. Westcott JL. Percutaneous needle aspiration of hilar and mediastinal masses. *Radiology* 1981;141:323-9.
19. de Gregorio Ariza MA, Alfonso Aguiran ER, Villavieja Atance JL, et al. Transthoracic aspiration biopsy of pulmonary and mediastinal lesions. *Eur J Radiol* 1991;12:98-103.
20. Moinuddin SM, Lee LH, Montgomery JH. Mediastinal needle biopsy. *AJR Am J Roentgenol* 1984;143:531-2.
21. Protopapas Z, Westcott JL. Transthoracic needle biopsy of mediastinal lymph nodes for staging lung and other cancers. *Radiology* 1996;199:489-96.
22. Savage C, Zwischenberger JB. Image-guided fine needle aspirate strategies for staging of lung cancer. *Clin Lung Cancer* 2000;2:101-10; discussion 11-2.

23. Schenk DA, Chambers SL, Derdak S, et al. Comparison of the Wang 19-gauge and 22-gauge needles in the mediastinal staging of lung cancer. *Am Rev Respir Dis* 1993;147:1251-8.
24. Patelli M, Lazzari Agli L, Poletti V, et al. Role of fiberoptic transbronchial needle aspiration in the staging of N2 disease due to non-small cell lung cancer. *Ann Thorac Surg* 2002;73:407-11.
25. Wang KP, Brower R, Haponik EF, et al. Flexible transbronchial needle aspiration for staging of bronchogenic carcinoma. *Chest* 1983;84:571-6.
26. Schenk DA, Strollo PJ, Pickard JS, et al. Utility of the Wang 18-gauge transbronchial histology needle in the staging of bronchogenic carcinoma. *Chest* 1989;96:272-4.
27. Selcuk ZT, Firat P. The diagnostic yield of transbronchial needle aspiration in superior vena cava syndrome. *Lung Cancer* 2003;42:183-8.
28. Milman N, Faurouchou P, Munch EP, et al. Transbronchial lung biopsy through the fibre optic bronchoscope. Results and complications in 452 examinations. *Respir Med* 1994;88:749-53.
29. Pereira W Jr, Kovnat DM, Snider GL. A prospective cooperative study of complications following flexible fiberoptic bronchoscopy. *Chest* 1978;73:813-6.
30. Varela-Lema L, Fernandez-Villara A, Ruano-Ravina A. Effectiveness and safety of endobronchial ultrasound-transbronchial needle aspiration: a systematic review. *Eur Respir J* 2009;33:1156-64.
31. Michaud G, Kull D, Ankrom A, et al. Endobronchial ultrasound using the linear EBUS bronchoscope for evaluation of mediastinal and hilar lymphadenopathy: a systemic review. *Am J Respir Crit Care Med* 2010;181:A5139.
32. Vilmann P. Endoscopic ultrasonography-guided fine-needle aspiration biopsy of lymph nodes. *Gastrointest Endosc* 1996;43:S24-9.
33. Leschber G, Holinka G, Linder A. Video-assisted mediastinoscopic lymphadenectomy (VAMLA)—a method for systematic mediastinal lymphnode dissection. *Eur J Cardiothorac Surg* 2003;24:192-5.
34. Cybulsky IJ, Bennett WF. Mediastinoscopy as a routine outpatient procedure. *Ann Thorac Surg* 1994;176-8.
35. Vallieres E, Page A, Verdant A. Ambulatory mediastinoscopy and anterior mediastinotomy. *Ann Thorac Surg* 1991;1122-6.
36. Bonadies J, D'Agostino RS, Ruskis AF, et al. Outpatient mediastinoscopy. *J Thorac Cardiovasc Surg* 1993;106:686-8.
37. Lemaire A, Nikolic I, Petersen T, et al. Nine-year single center experience with cervical mediastinoscopy: complications and false negative rate. *Ann Thorac Surg* 2006;82:1185-9; discussion 9-90.
38. Nechala P, Graham AJ, McFadden SD, et al. Retrospective analysis of the clinical performance of anterior mediastinotomy. *Ann Thorac Surg* 2006;82:2004-9.
39. Toloza EM, Harpole L, Detterbeck F, et al. Invasive staging of non-small cell lung cancer: a review of the current evidence. *Chest* 2003;123:1575-66S.
40. Freixinet Gilart J, Garcia PG, de Castro FR, et al. Extended cervical mediastinoscopy in the staging of bronchogenic carcinoma. *Ann Thorac Surg* 2000;70:1641-3.
41. Ginsberg RJ, Rice TW, Goldberg M. Extended cervical mediastinoscopy. A single staging procedure for bronchogenic carcinoma of the left upper lobe. *J Thorac Cardiovasc Surg* 1987;94:673-8.
42. Ginsberg RJ. Extended cervical mediastinoscopy. *Chest Surg Clin N Am* 1996;6:21-30.
43. Call S, Rami-Porta R, Serra-Mitjans M, et al. Extended cervical mediastinoscopy in the staging of bronchogenic carcinoma of the left lung. *Eur J Cardiothorac Surg* 2008;34:1081-4.
44. Urschel JD, Vretenar DF, Dickout WJ, et al. Cerebrovascular accident complicating extended cervical mediastinoscopy. *Ann Thorac Surg* 1994;57:740-1.
45. Lopez L, Varela A, Freixinet J, et al. Extended cervical mediastinoscopy: prospective study of fifty cases. *Ann Thorac Surg* 1994;57:555-7; discussion 7-8.
46. United States Cancer Statistics. 1999-2006 Incidence and Mortality Web-based Report. Atlanta.
47. Cancer Key Facts. World Health Organization; 2009.
48. AJCC cancer staging manual. 7th ed. New York (NY): Springer-Verlag; 2010.
49. Robinson LA, Ruckdeschel JC, Wagner H, Jr., et al. Treatment of non-small cell lung cancer-stage IIIA: ACCP evidence-based clinical practice guidelines (2nd edition). *Chest* 2007;132:243S-65S.
50. Gill KR, Ghabril MS, Jamil LH, et al. Endosonographic features predictive of malignancy in mediastinal lymph nodes in patients with lung cancer. *Gastrointest Endosc* 2010;72:265-71.
51. Chen VK, Eloubeidi MA. Endoscopic ultrasound-guided fine needle aspiration is superior to lymph node echofeatures: a prospective evaluation of mediastinal and peri-intestinal lymphadenopathy. *Am J Gastroenterol* 2004;99:628-33.
52. Fritscher-Ravens A, Davidson BL, Hauber HP, et al. Endoscopic ultrasound, positron emission tomography, and computerized tomography for lung cancer. *Am J Respir Crit Care Med* 2003;168:1293-7.
53. Annema JT, Versteegh MI, Veselic M, et al. Endoscopic ultrasound added to mediastinoscopy for preoperative staging of patients with lung cancer. *JAMA* 2005;294:931-6.
54. Larsen SS, Vilmann P, Krasnik M, et al. Endoscopic ultrasound guided biopsy versus mediastinoscopy for analysis of paratracheal and subcarinal lymph nodes in lung cancer staging. *Lung Cancer* 2005;48:85-92.
55. Gress FG, Savides TJ, Sandler A, et al. Endoscopic ultrasonography, fine-needle aspiration biopsy guided by endoscopic ultrasonography, and computed tomography in the preoperative staging of non-small-cell lung cancer: a comparison study. *Ann Intern Med* 1997;127:604-12.
56. Fritscher-Ravens A, Soehendra N, Schirrow L, et al. Role of transesophageal endosonography-guided fine-needle aspiration in the diagnosis of lung cancer. *Chest* 2000;117:339-45.
57. Wiersema MJ, Vazquez-Sequeiros E, Wiersema LM. Evaluation of mediastinal lymphadenopathy with endoscopic US-guided fine-needle aspiration biopsy. *Radiology* 2001;219:252-7.
58. Kramer H, van Putten JW, Post WJ, et al. Oesophageal endoscopic ultrasound with fine needle aspiration improves and simplifies the staging of lung cancer. *Thorax* 2004;59:596-601.
59. Wallace MB, Silvestri GA, Sahai AV, et al. Endoscopic ultrasound-guided fine needle aspiration for staging patients with carcinoma of the lung. *Ann Thorac Surg* 2001;72:1861-7.
60. von Bartheld MB, Rabe KF, Annema JT. Transaortic EUS-guided FNA in the diagnosis of lung tumors and lymph nodes. *Gastrointest Endosc* 2009;69:345-9.
61. DeWitt JM. Endoscopic ultrasound-guided fine-needle aspiration of right adrenal masses: report of 2 cases. *J Ultrasound Med* 2008;27:261-7.
62. DeWitt J, LeBlanc J, McHenry L, et al. Endoscopic ultrasound-guided fine needle aspiration cytology of solid liver lesions: a large single-center experience. *Am J Gastroenterol* 2003;98:1976-81.
63. Prasad P, Schmulewitz N, Patel A, et al. Detection of occult liver metastases during EUS for staging of malignancies. *Gastrointest Endosc* 2004;59:49-53.
64. Eloubeidi MA, Black KR, Tamhane A, et al. A large single-center experience of EUS-guided FNA of the left and right adrenal glands: diagnostic utility and impact on patient management. *Gastrointest Endosc* 2010;71:745-53.
65. Eloubeidi MA, Morgan DE, Cerfolio RJ, et al. Transduodenal EUS-guided FNA of the right adrenal gland. *Gastrointest Endosc* 2008;67:522-7.
66. Eloubeidi MA, Seewald S, Tamhane A, et al. EUS-guided FNA of the left adrenal gland in patients with thoracic or GI malignancies. *Gastrointest Endosc* 2004;59:627-33.
67. Jhala NC, Jhala D, Eloubeidi MA, et al. Endoscopic ultrasound-guided fine-needle aspiration biopsy of the adrenal glands: analysis of 24 patients. *Cancer* 2004;102:308-14.
68. DeWitt J, Alsatie M, LeBlanc J, et al. Endoscopic ultrasound-guided fine-needle aspiration of left adrenal gland masses. *Endoscopy* 2007;39:65-71.
69. Haseganu LE, Diehl DL. Left adrenal gland hemorrhage as a complication of EUS-FNA. *Gastrointest Endosc* 2009;69:e51-2.
70. Annema JT, Veselic M, Versteegh MI, et al. Mediastinal restaging: EUS-FNA offers a new perspective. *Lung Cancer* 2003;42:311-8.
71. Stigt JA, Oostdijk AH, Timmer PR, et al. Comparison of EUS-guided fine needle aspiration and integrated PET-CT in restaging after treatment for

- locally advanced non-small cell lung cancer. *Lung Cancer* 2009;66:198-204.
72. Fujiwara T, Yasufuku K, Nakajima T, et al. The utility of sonographic features during endobronchial ultrasound-guided transbronchial needle aspiration for lymph node staging in patients with lung cancer: a standard endobronchial ultrasound image classification system. *Chest* 2010;138:641-7.
 73. Herth FJ, Krasnik M, Kahn N, et al. Combined endoesophageal-endobronchial ultrasound-guided fine-needle aspiration of mediastinal lymph nodes through a single bronchoscope in 150 patients with suspected lung cancer. *Chest* 2010;138:790-4.
 74. Szlubowski A, Zielinski M, Soja J, et al. A combined approach of endobronchial and endoscopic ultrasound-guided needle aspiration in the radiologically normal mediastinum in non-small-cell lung cancer staging—a prospective trial. *Eur J Cardiothorac Surg* 2010;37:1175-9.
 75. Wallace MB, Pascual JM, Raimondo M, et al. Minimally invasive endoscopic staging of suspected lung cancer. *JAMA* 2008;299:540-6.
 76. Aabakken L, Silvestri GA, Hawes R, et al. Cost-efficacy of endoscopic ultrasonography with fine-needle aspiration vs. mediastinoscopy in patients with lung cancer and suspected mediastinal adenopathy. *Endoscopy* 1999;31:707-11.
 77. Harewood GC, Wiersema MJ, Edell ES, et al. Cost-minimization analysis of alternative diagnostic approaches in a modeled patient with non-small cell lung cancer and subcarinal lymphadenopathy. *Mayo Clin Proc* 2002;77:155-64.
 78. Harewood GC, Pascual J, Raimondo M, et al. Economic analysis of combined endoscopic and endobronchial ultrasound in the evaluation of patients with suspected non-small cell lung cancer. *Lung Cancer* 2010;67:355-71.
 79. Kennedy MP, Jimenez CA, Bruzzi JF, et al. Endobronchial ultrasound-guided transbronchial needle aspiration in the diagnosis of lymphoma. *Thorax* 2008;63:360-5.
 80. Ribeiro A, Vazquez-Sequeiros E, Wiersema LM, et al. EUS-guided fine-needle aspiration combined with flow cytometry and immunocytochemistry in the diagnosis of lymphoma. *Gastrointest Endosc* 2001;53:485-91.
 81. Ribeiro A, Pereira D, Escalon MP, et al. EUS-guided biopsy for the diagnosis and classification of lymphoma. *Gastrointest Endosc* 2010;71:851-5.
 82. Mehra M, Tamhane A, Eloubeidi MA. EUS-guided FNA combined with flow cytometry in the diagnoses of suspected or recurrent intrathoracic or retroperitoneal lymphoma. *Gastrointest Endosc* 2005;62:508-13.
 83. Yasuda I, Tsurumi H, Omar S, et al. Endoscopic ultrasound-guided fine-needle aspiration biopsy for lymphadenopathy of unknown origin. *Endoscopy* 2006;38:919-24.
 84. Steinfurt DP, Conron M, Tsui A, et al. Endobronchial ultrasound-guided transbronchial needle aspiration for the evaluation of suspected lymphoma. *J Thorac Oncol* 2010;5:804-9.
 85. Al-Haddad M, Savabi MS, Sherman S, et al. Role of endoscopic ultrasound-guided fine-needle aspiration with flow cytometry to diagnose lymphoma: a single center experience. *J Gastroenterol Hepatol* 2009;24:1826-33.
 86. Hehn ST, Grogan TM, Miller TP. Utility of fine-needle aspiration as a diagnostic technique in lymphoma. *J Clin Oncol* 2004;22:3046-52.
 87. Young NA, Al-Saleem TI, Ehya H, et al. Utilization of fine-needle aspiration cytology and flow cytometry in the diagnosis and subclassification of primary and recurrent lymphoma. *Cancer* 1998;84:252-61.
 88. Eloubeidi MA, Mehra M, Bean SM. EUS-guided 19-gauge trucut needle biopsy for diagnosis of lymphoma missed by EUS-guided FNA. *Gastrointest Endosc* 2007;65:937-9.
 89. Berger LP, Scheffer RC, Weusten BL, et al. The additional value of EUS-guided Tru-cut biopsy to EUS-guided FNA in patients with mediastinal lesions. *Gastrointest Endosc* 2009;69:1045-51.
 90. Tournoy KG, Praet MM, Van Maele G, et al. Esophageal endoscopic ultrasound with fine-needle aspiration with an on-site cytopathologist: high accuracy for the diagnosis of mediastinal lymphadenopathy. *Chest* 2005;128:3004-9.
 91. von Bartheld MB, Veselic-Charvat M, Rabe KF, et al. Endoscopic ultrasound-guided fine-needle aspiration for the diagnosis of sarcoidosis. *Endoscopy* 2010;42:213-7.
 92. Michael H, Ho S, Pollack B, et al. Diagnosis of intra-abdominal and mediastinal sarcoidosis with EUS-guided FNA. *Gastrointest Endosc* 2008;67:28-34.
 93. Wildi SM, Judson MA, Fraig M, et al. Is endosonography guided fine needle aspiration (EUS-FNA) for sarcoidosis as good as we think? *Thorax* 2004;59:794-9.
 94. Fritscher-Ravens A, Sriram PV, Topalidis T, et al. Diagnosing sarcoidosis using endosonography-guided fine-needle aspiration. *Chest* 2000;118:928-35.
 95. Tremblay A, Stather DR, Maceachern P, et al. A randomized controlled trial of standard vs endobronchial ultrasonography-guided transbronchial needle aspiration in patients with suspected sarcoidosis. *Chest* 2009;136:340-6.
 96. Oki M, Saka H, Kitagawa C, et al. Real-time endobronchial ultrasound-guided transbronchial needle aspiration is useful for diagnosing sarcoidosis. *Respirology* 2007;12:863-8.
 97. Garwood S, Judson MA, Silvestri G, et al. Endobronchial ultrasound for the diagnosis of pulmonary sarcoidosis. *Chest* 2007;132:1298-304.
 98. Nakajima T, Yasufuku K, Kurosu K, et al. The role of EBUS-TBNA for the diagnosis of sarcoidosis—comparisons with other bronchoscopic diagnostic modalities. *Respir Med* 2009;103:1796-800.
 99. Iwashita T, Yasuda I, Doi S, et al. The yield of endoscopic ultrasound-guided fine needle aspiration for histological diagnosis in patients suspected of stage I sarcoidosis. *Endoscopy* 2008;40:400-5.
 100. Puri R, Vilmann P, Sud R, et al. Endoscopic ultrasound-guided fine-needle aspiration cytology in the evaluation of suspected tuberculosis in patients with isolated mediastinal lymphadenopathy. *Endoscopy* 2010;42:462-7.
 101. Berzosa M, Tsukayama DT, Davies SF, et al. Endoscopic ultrasound-guided fine-needle aspiration for the diagnosis of extra-pulmonary tuberculosis. *Int J Tuberc Lung Dis* 2010;14:578-84.
 102. Sendino O, Pellise M, Ghita G, et al. Aspergillus mediastinitis diagnosed by EUS-guided FNA. *Gastrointest Endosc* 2008;67:153; commentary 4.
 103. von Bartheld MB, van Kralingen KW, Veenendaal RA, et al. Mediastinal-esophageal fistulae after EUS-FNA of tuberculosis of the mediastinum. *Gastrointest Endosc* 2010;71:210-2.
 104. Mountain CF, Dresler CM. Regional lymph node classification for lung cancer staging. *Chest* 1997;111:1718-23.

Prepared by:
 ASGE STANDARDS OF PRACTICE COMMITTEE
 Terry L. Jue, MD
 Ravi N. Sharaf, MD
 Vasundhara Appalaneni, MD
 Michelle A. Anderson, MD
 Tamir Ben-Menachem, MD
 G. Anton Decker, MD
 Robert D. Fanelli, MD SAGES Representative
 Norio Fukami, MD
 Steven O. Ikenberry, MD
 Rajeev Jain, MD
 Khalid M. Khan, MD NASPHAGAN Representative
 Mary L. Krinsky, DO
 Phyllis M. Malpas, RN SGNA Representative
 John T. Maple, DO
 Deborah Fisher, MD
 Joo Ha Hwang, MD
 Dayna Early, MD
 John A. Evans, MD
 Jason A. Dominitz, MD, MHS (Committee Chair)
