

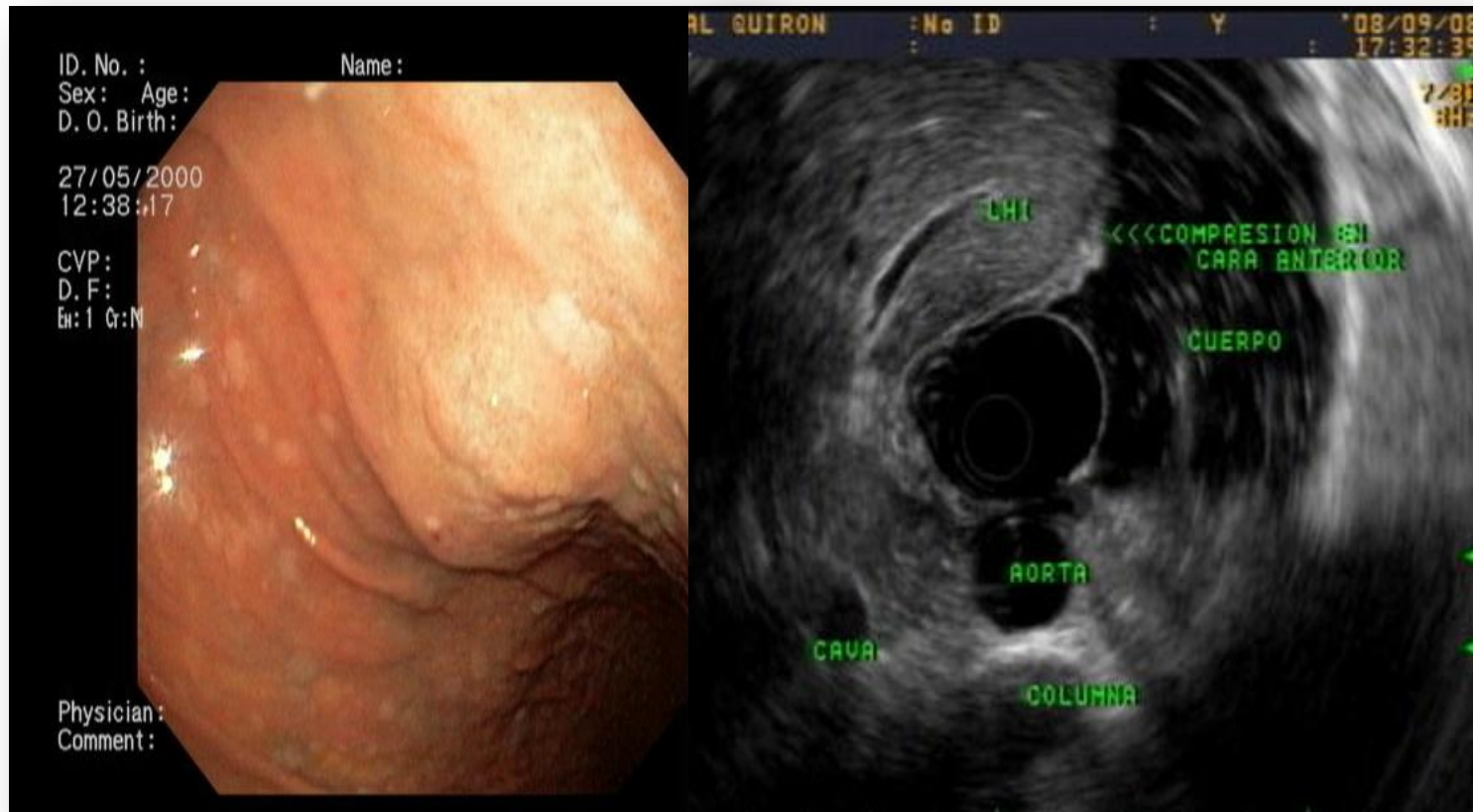
**Especialización en
Ultrasonografía
Endoscópica Avanzada**



GALERÍA IMÁGENES ECOENDOSCOPIA LESIONES SUBEPITELIALES

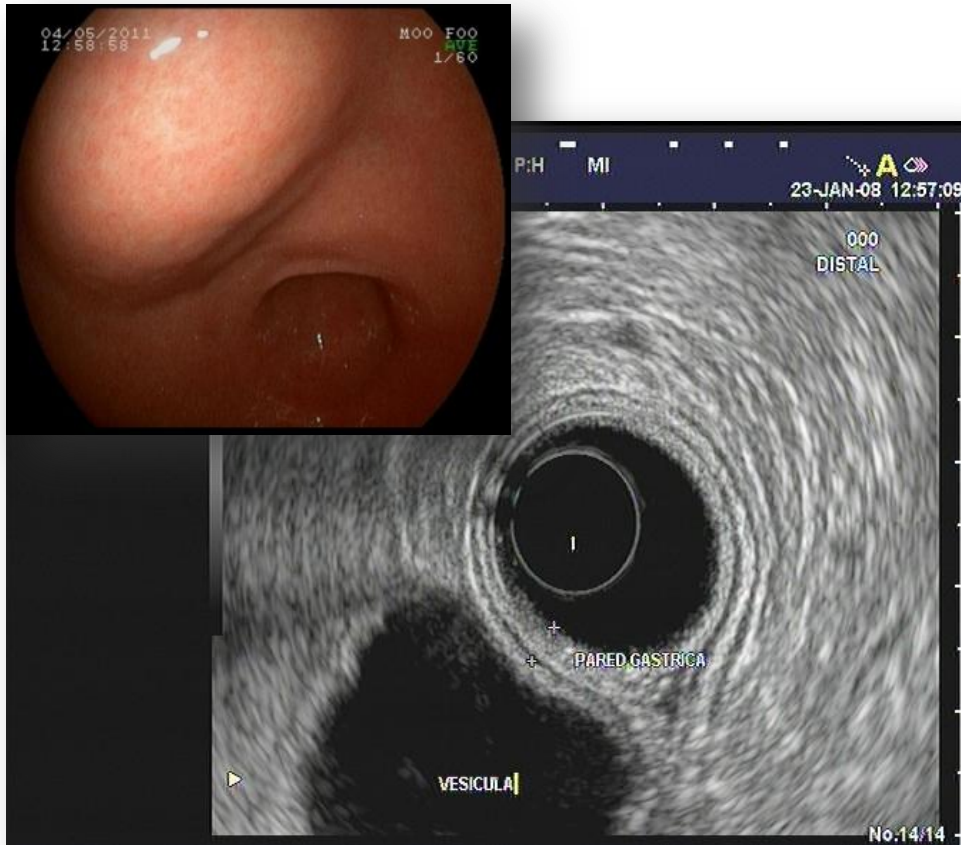
Servicio de Gastroenterología y Hepatología
Hospital Universitario Ramón y Cajal

COMPRESIÓN EXTRÍNSECA LHI

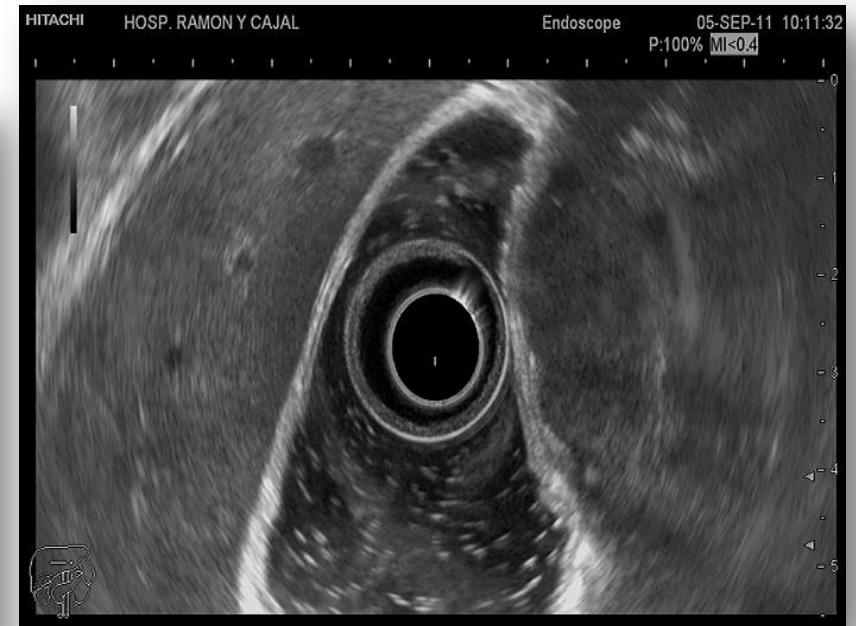

COMPRESIÓN EXTRÍNSECA

VESÍCULA

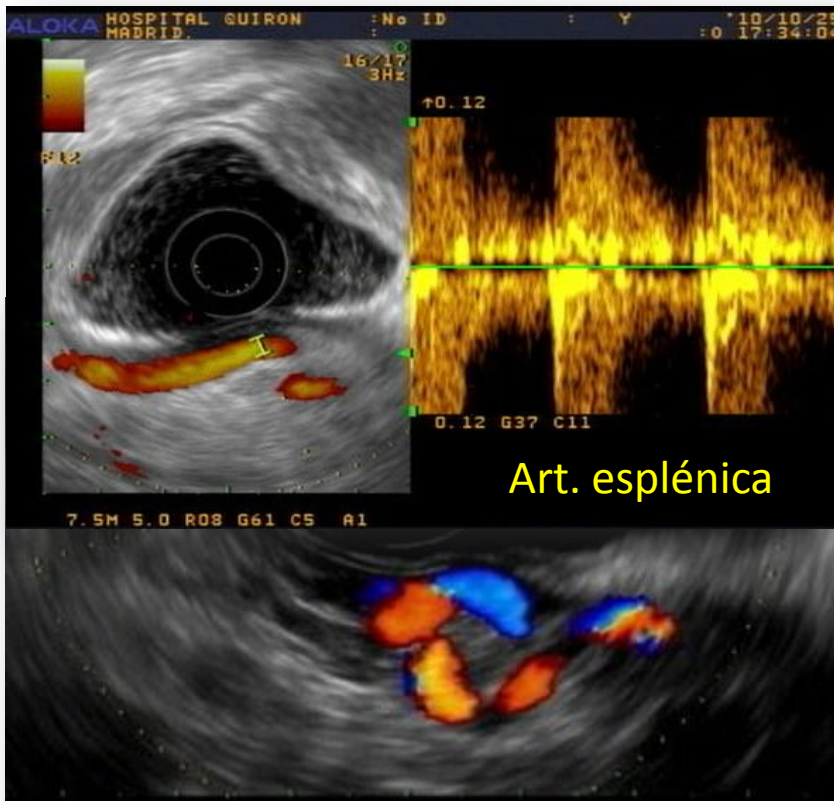


BAZO

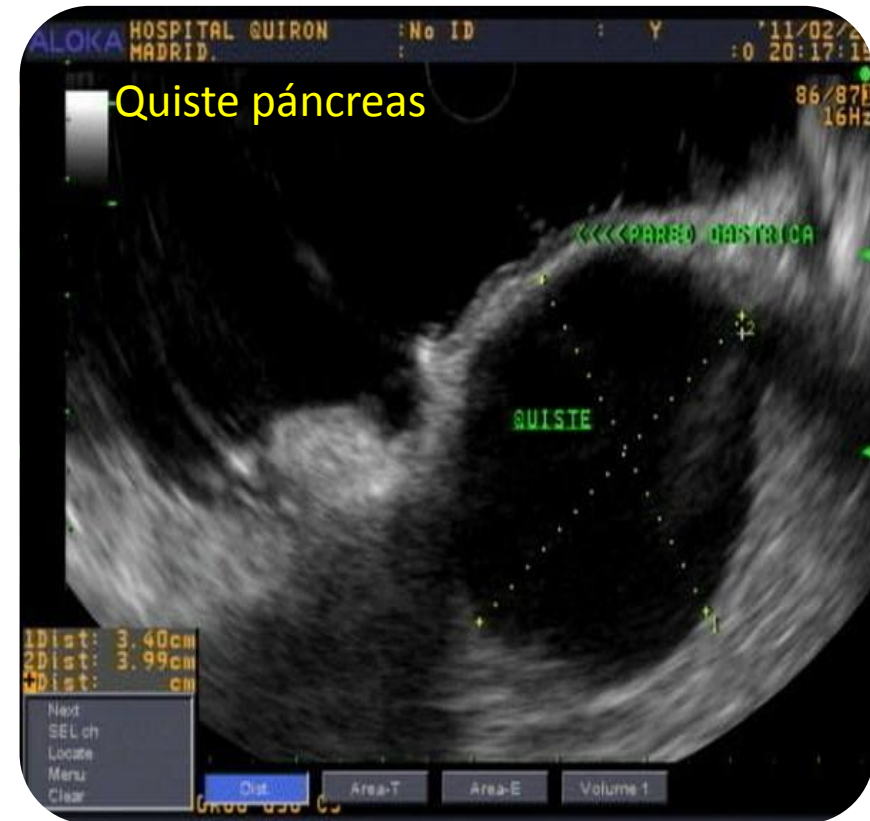

COMPRESIÓN EXTRÍNSECA

ARTERIA ESPLÉNICA



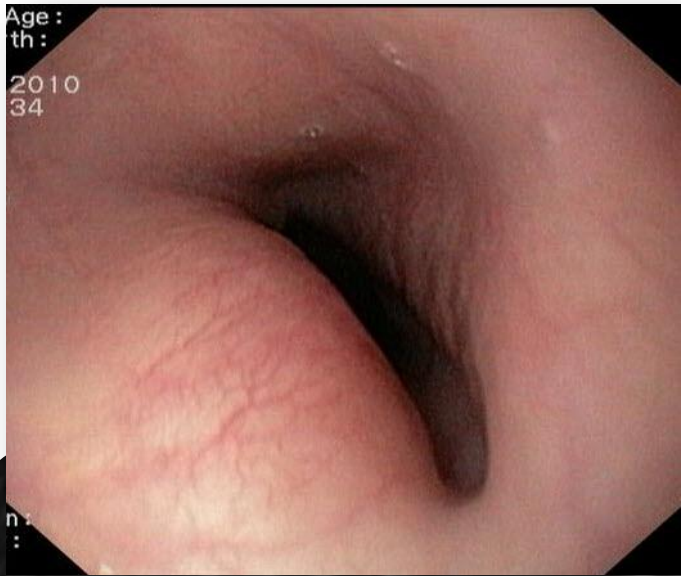QUISTE PANCREÁTICO



COMPRESIÓN EXTRÍNSECA

ARTERIA

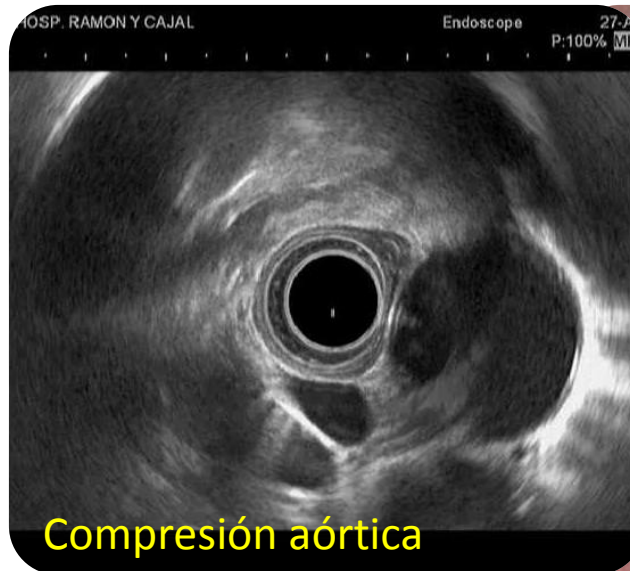
SUBCLAVIA ABERRANTE



Aorta

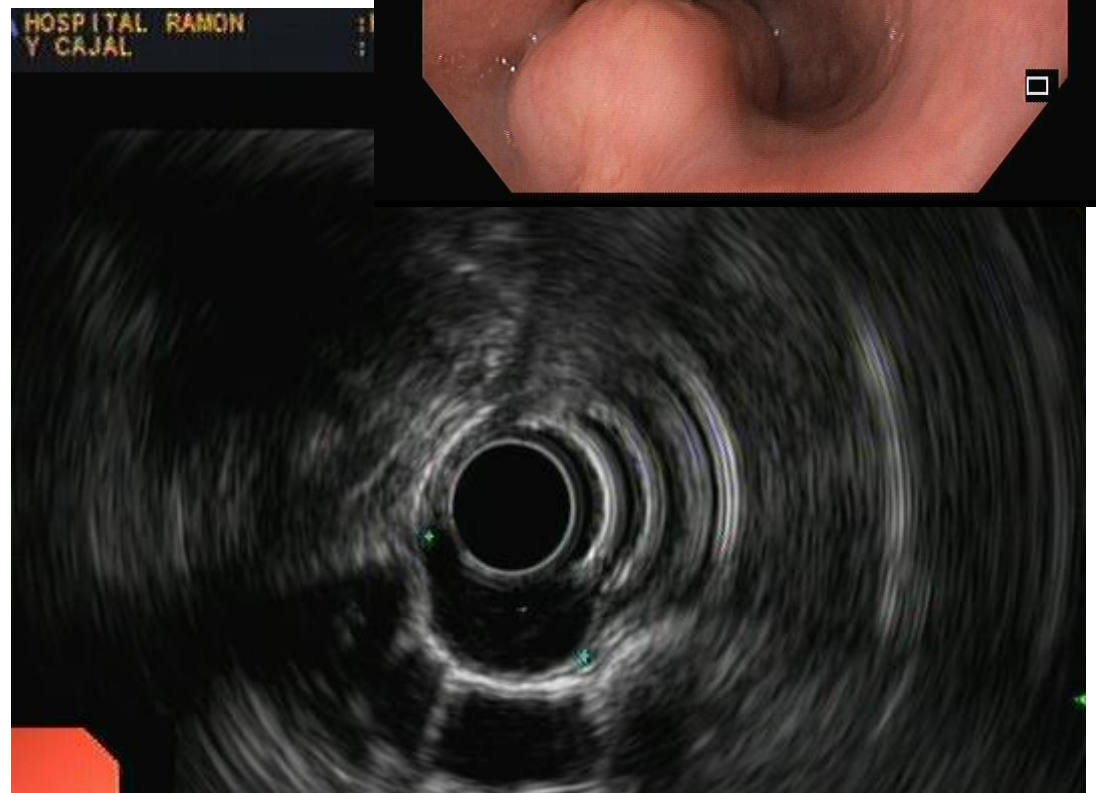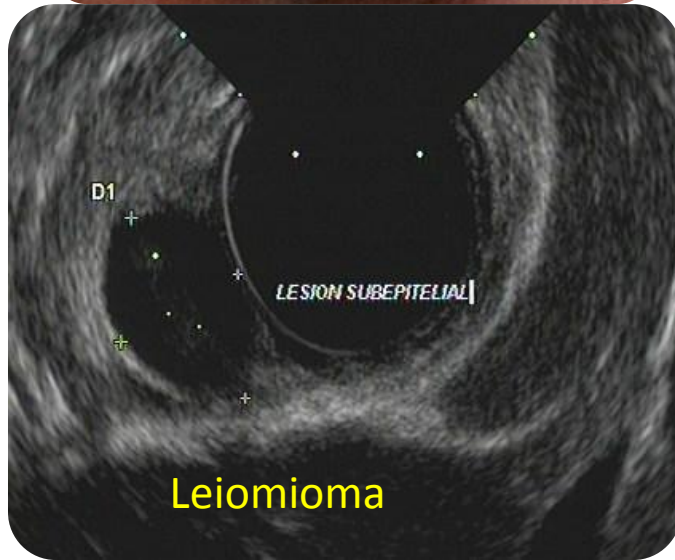
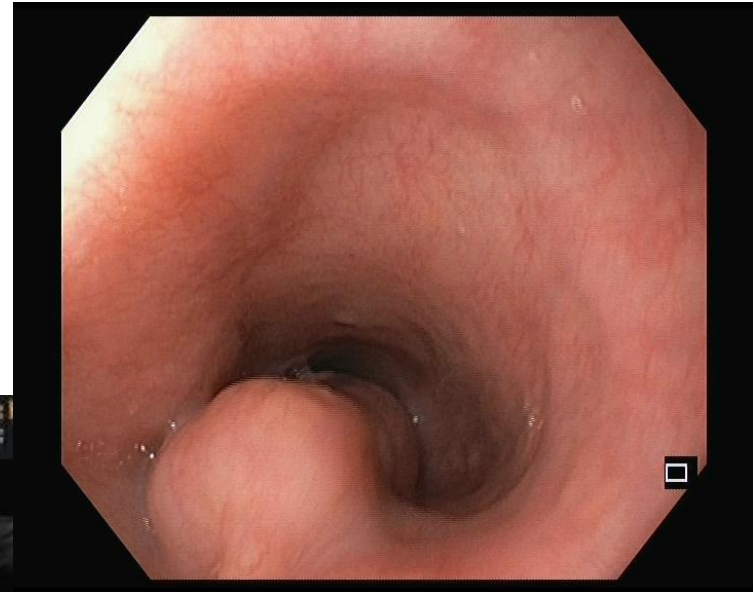
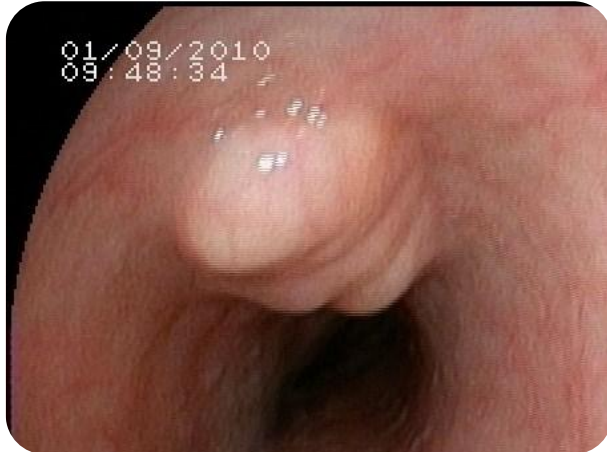Subclavia aberrante

ARORTA

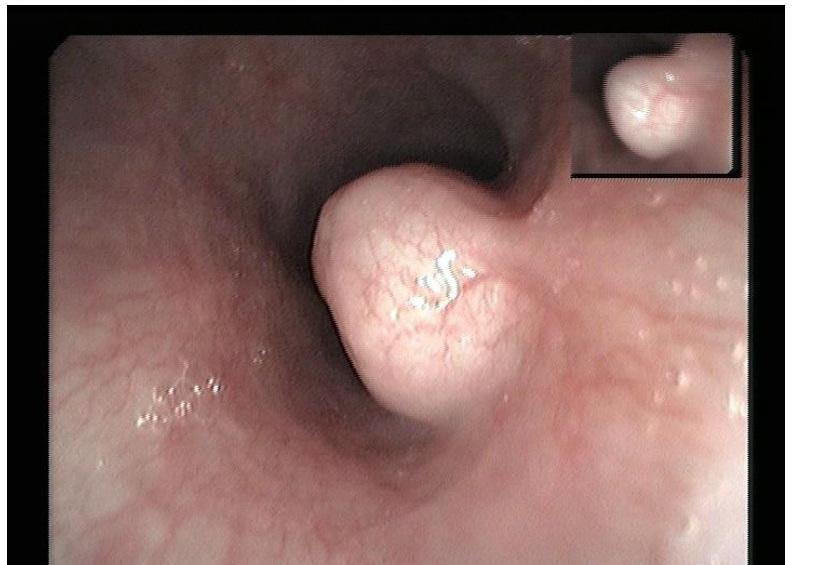


Compresión aórtica

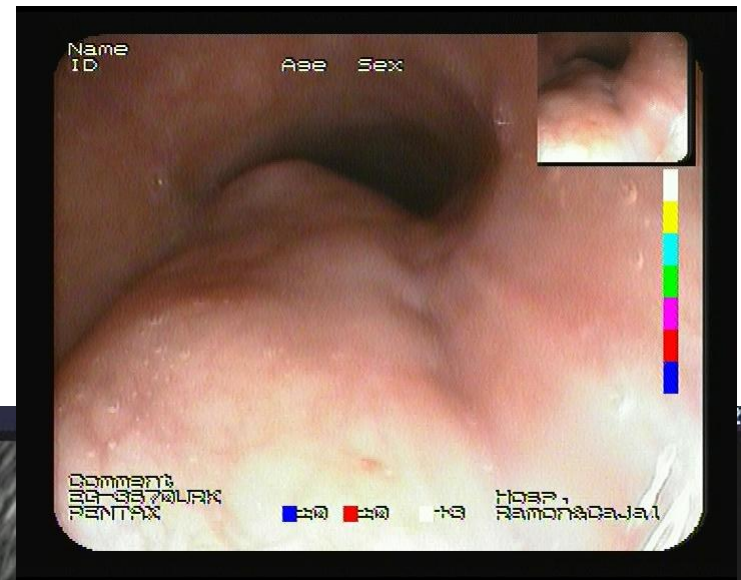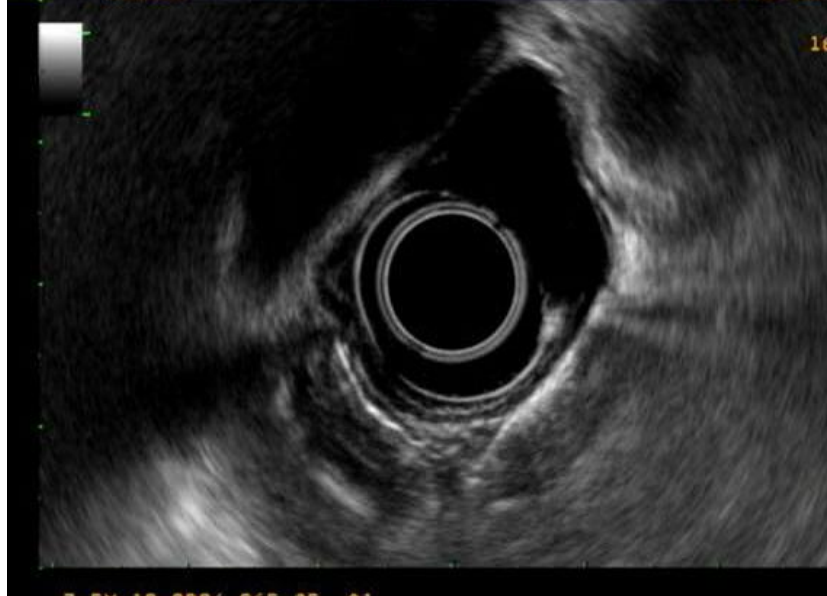
LEIOMIOMA ESOFÁGICO



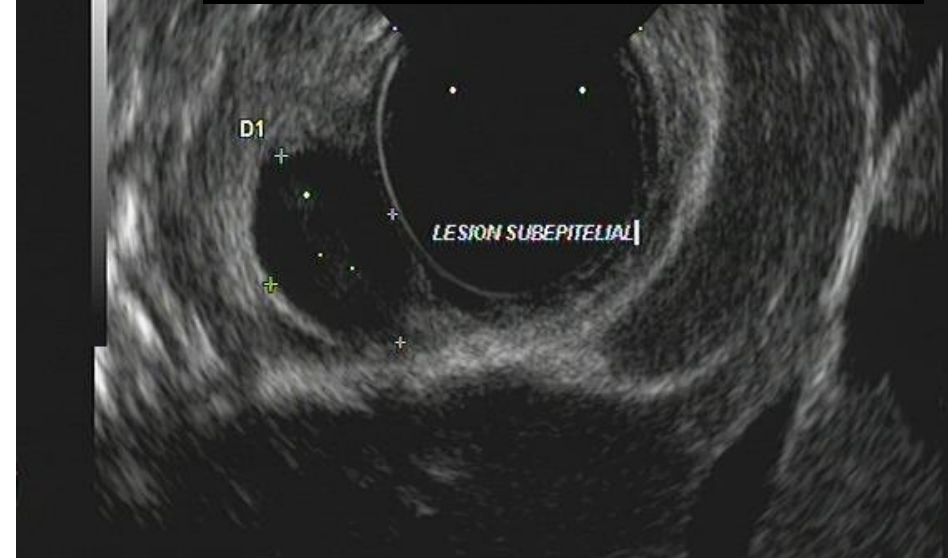LEIOMIOMA ESOFÁGICO



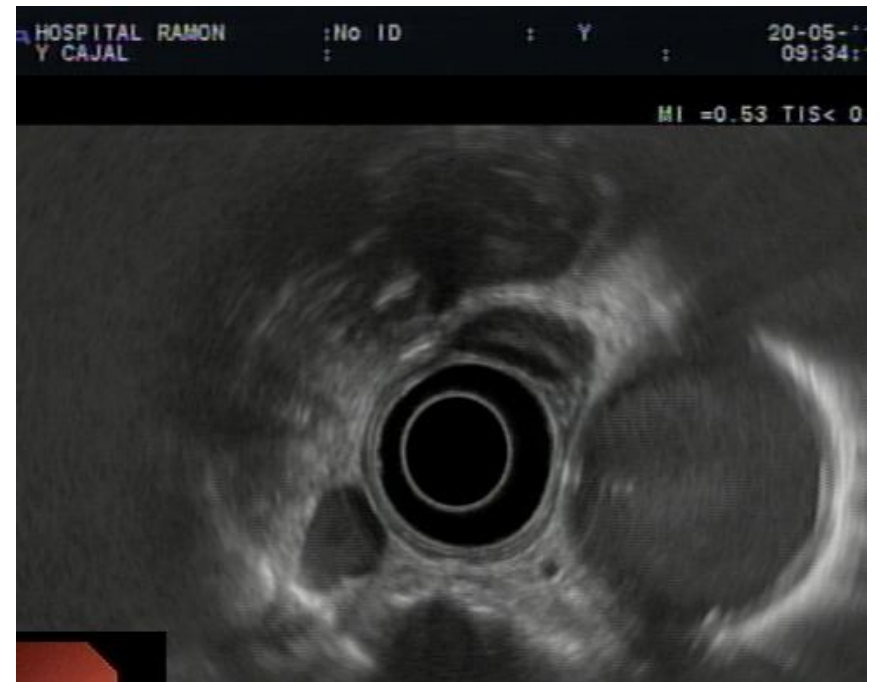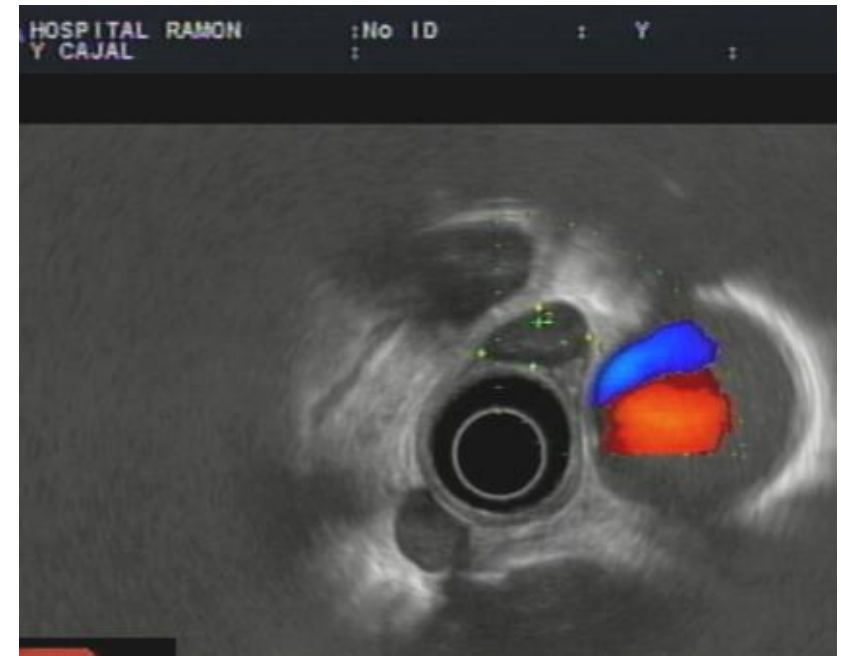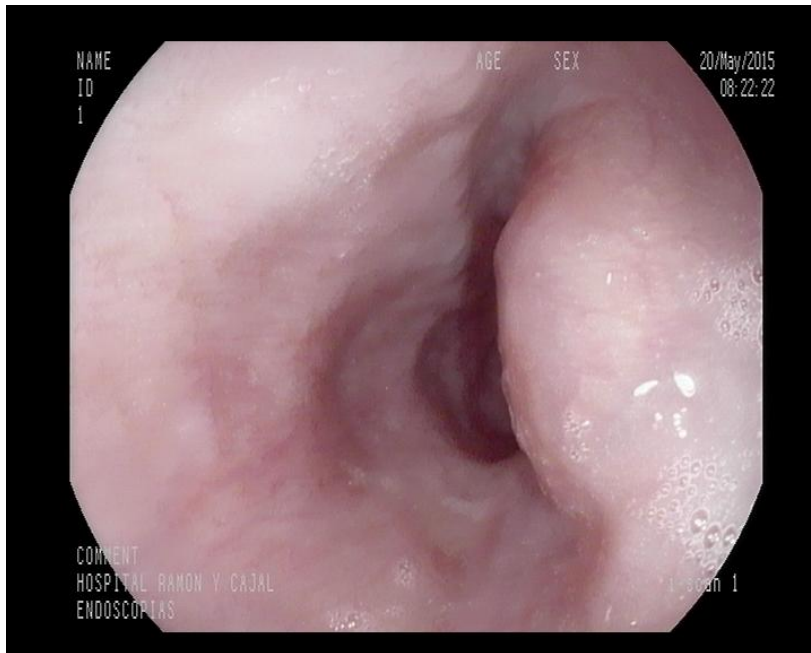
ALOKA HOSPITAL QUIRON MADRID. No ID Y 10/10 :0 16:21



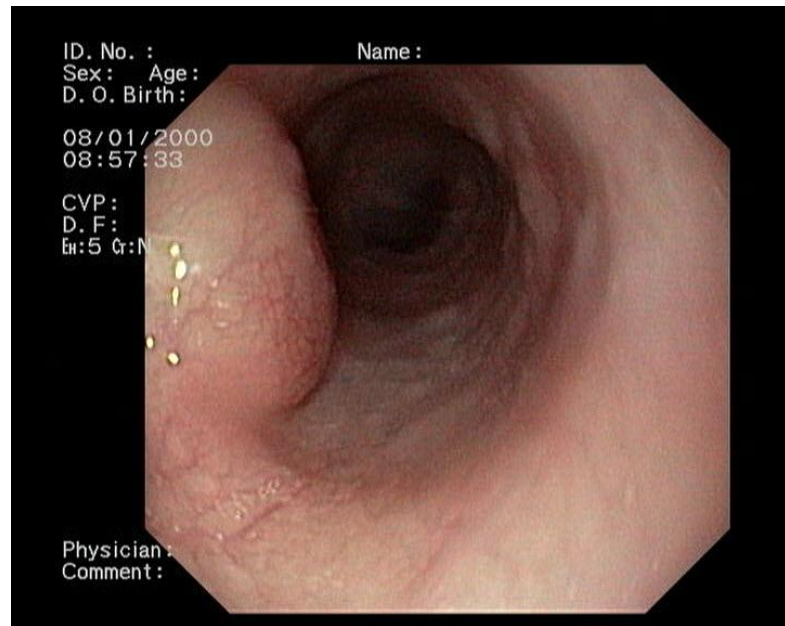
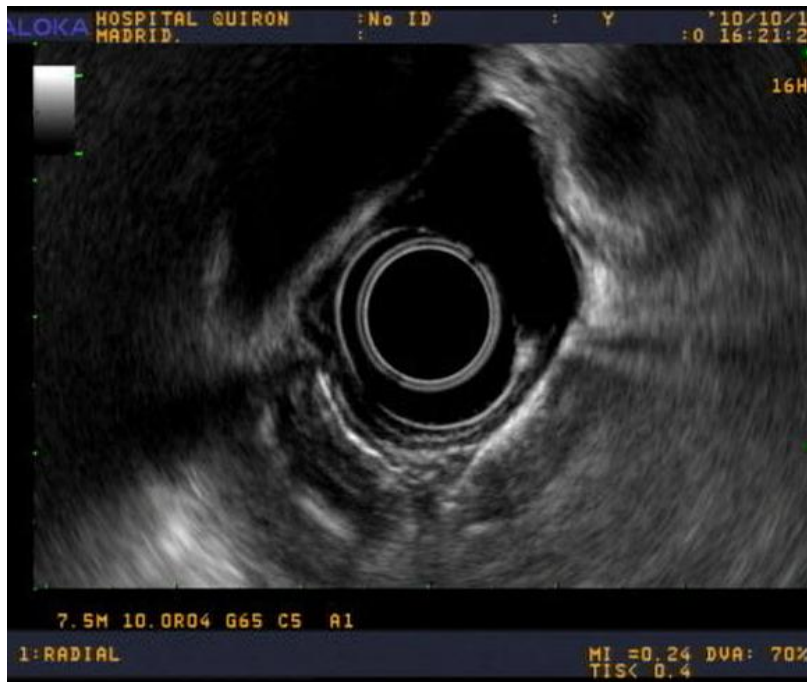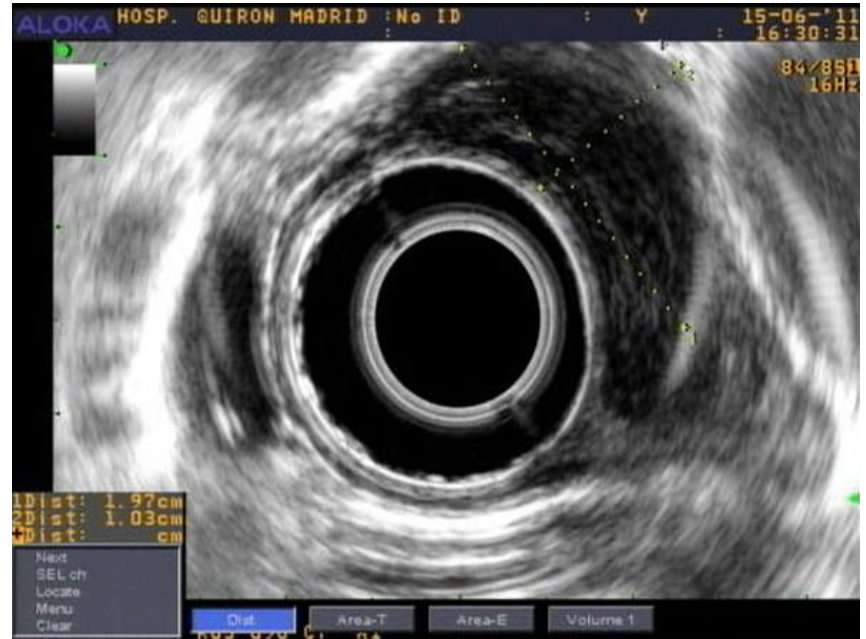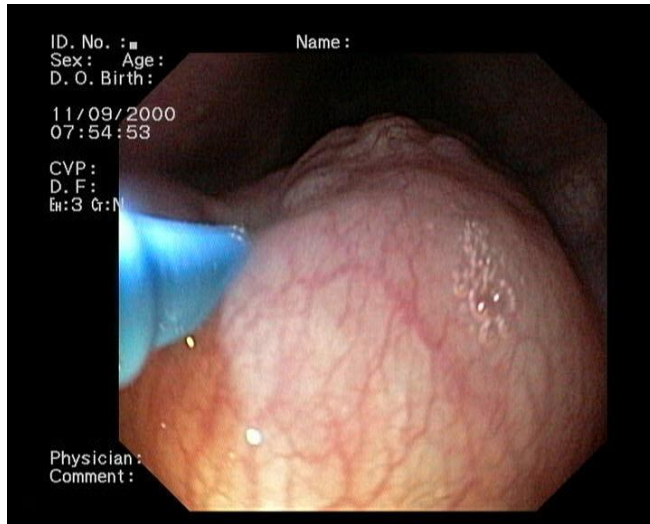
2.8 mm
3.5 mm



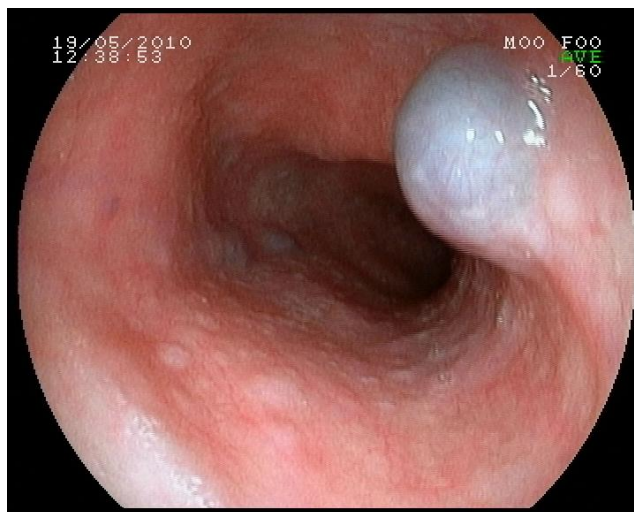
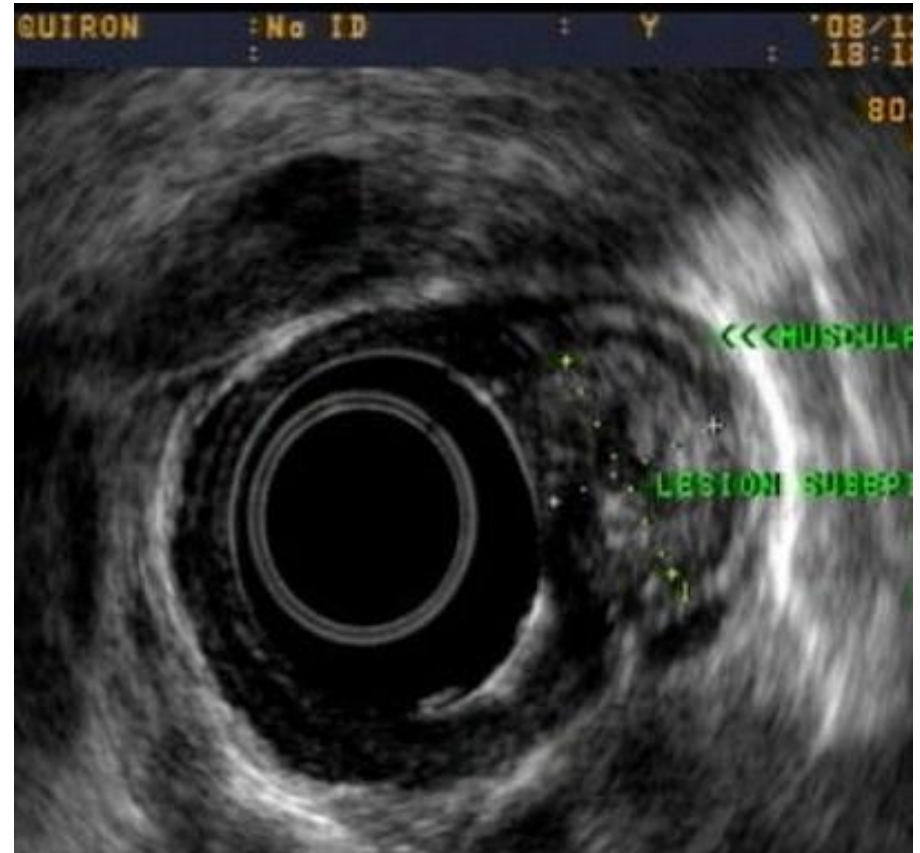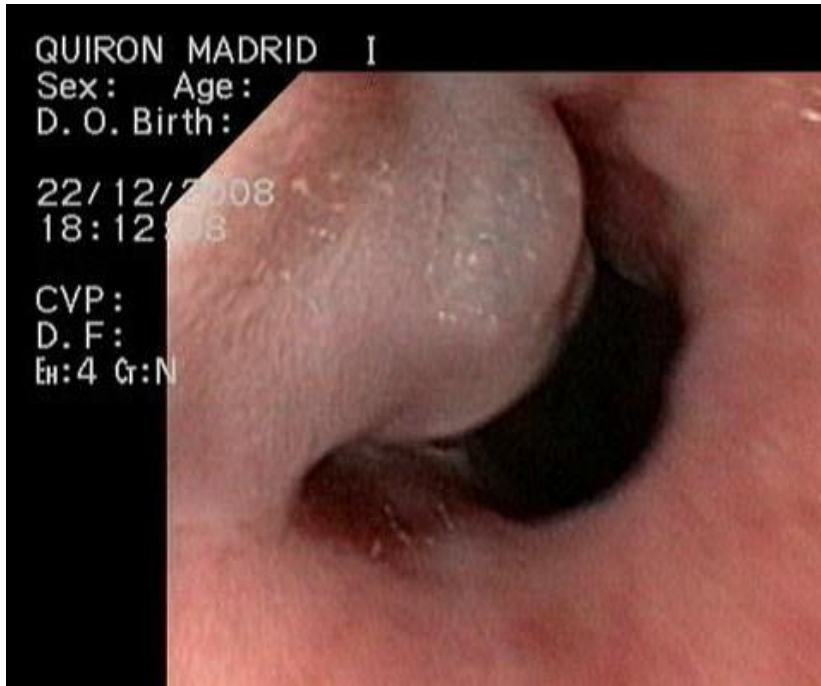LEIOMIOMA ESOFÁGICO



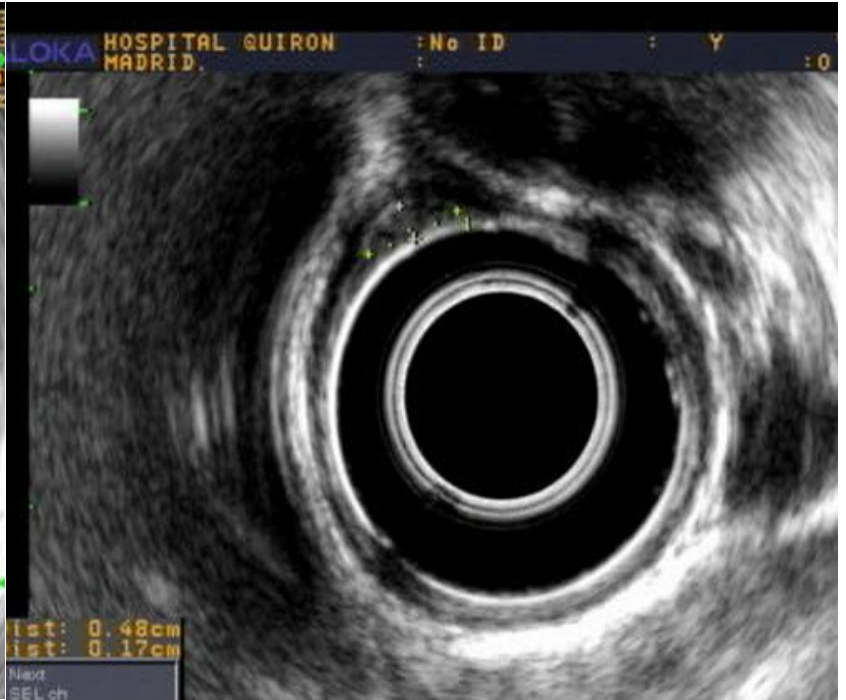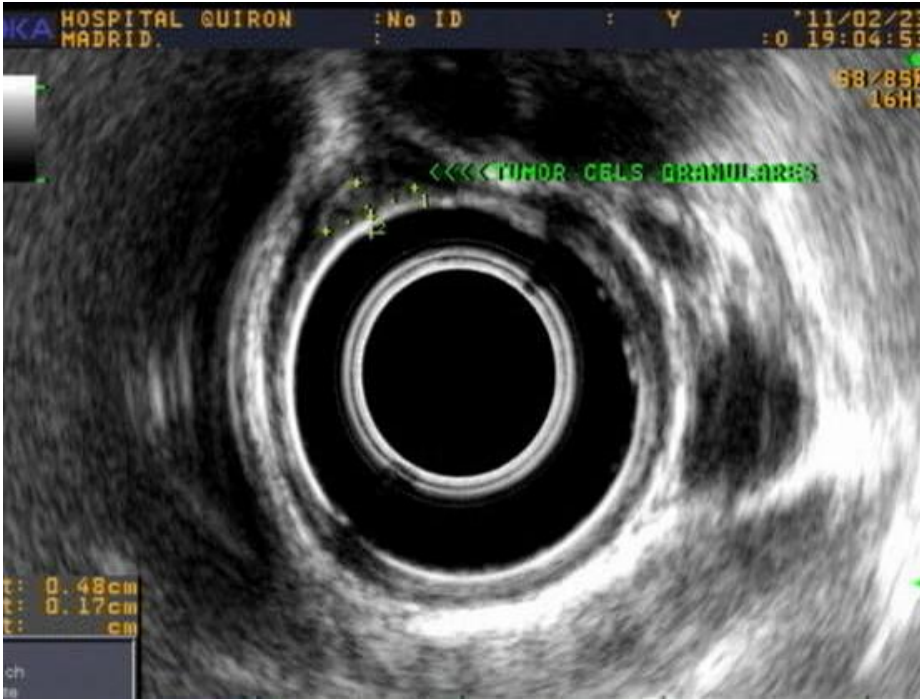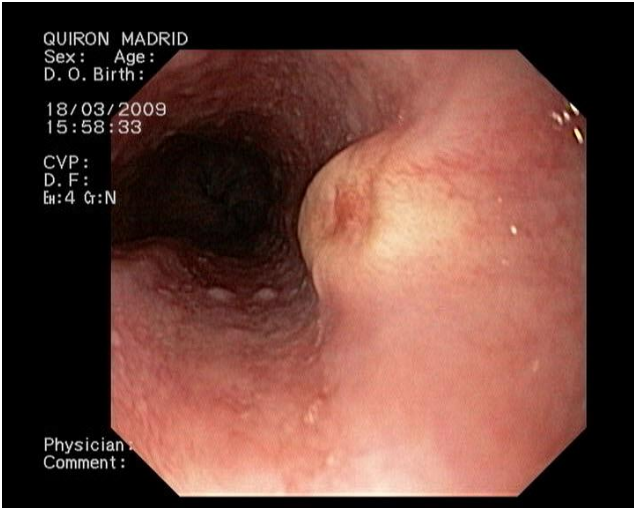
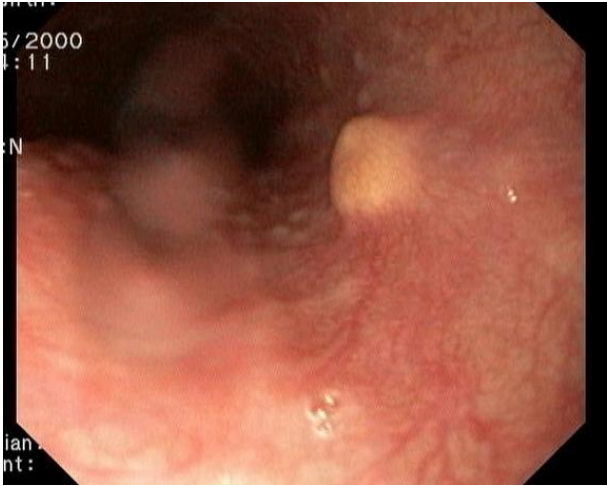
LEIOMIOMA ESOFÁGICO



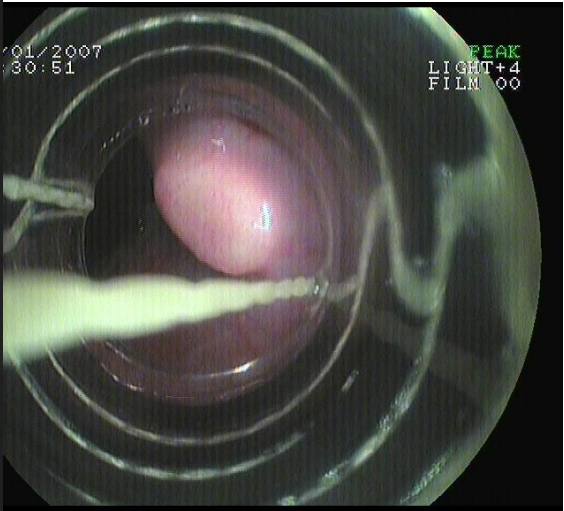
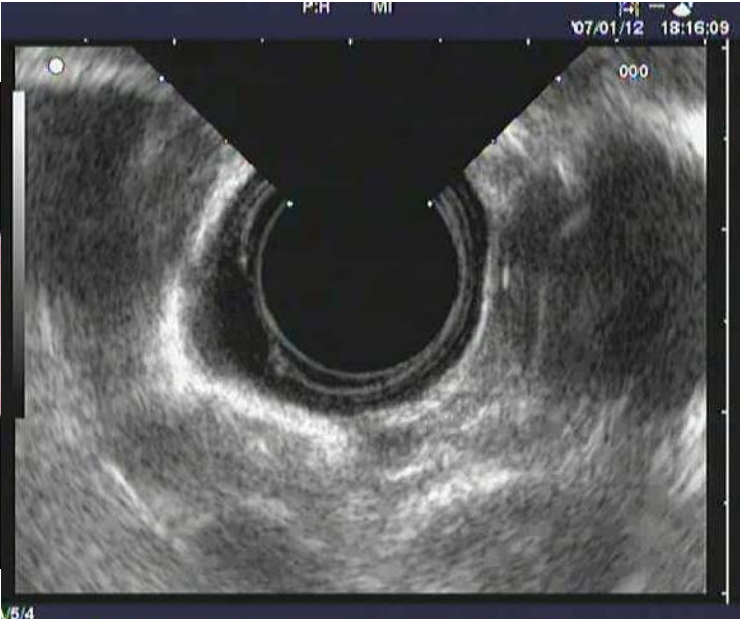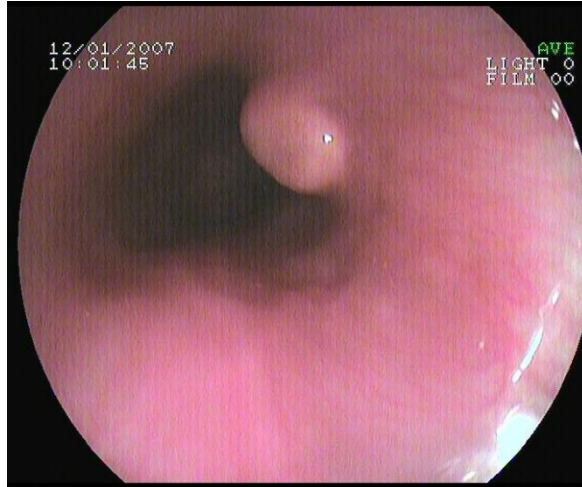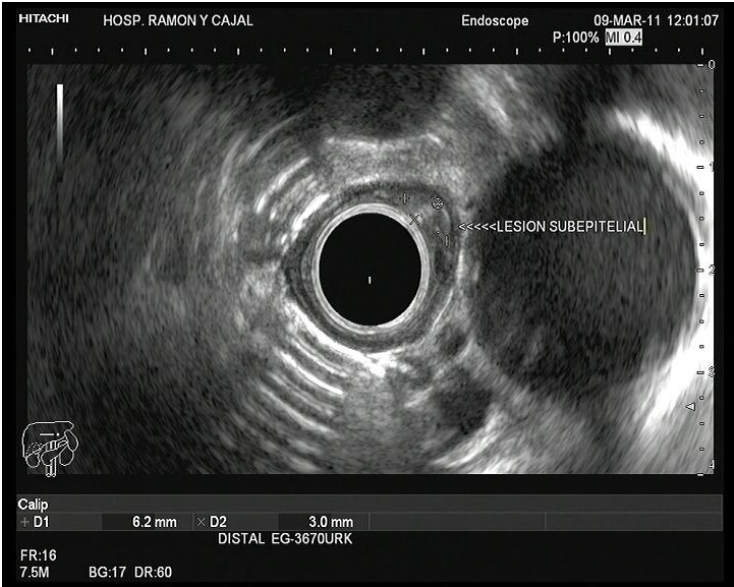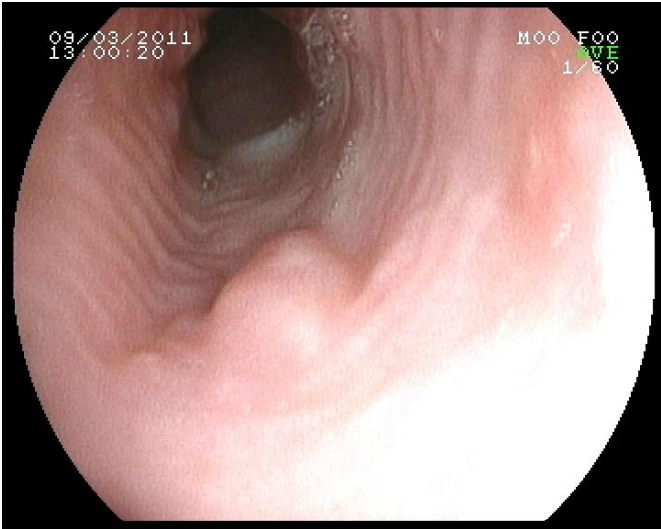
HEMAGIOMA ESOFÁGICO



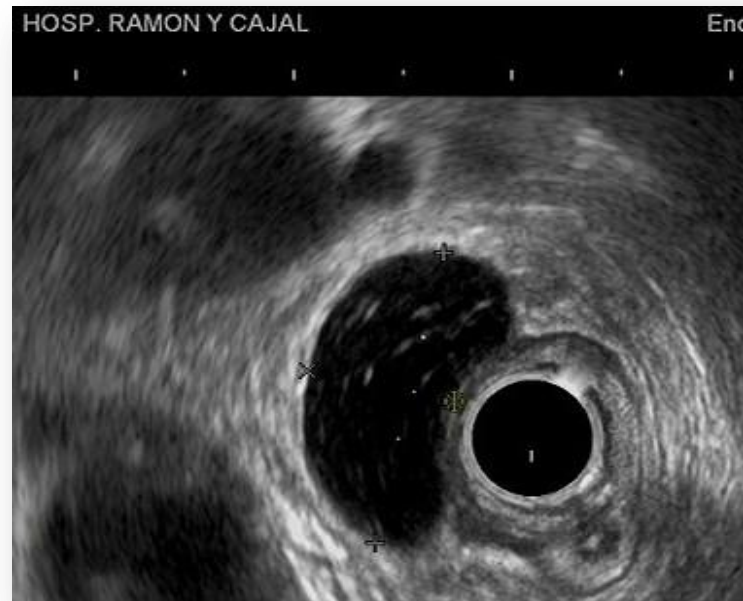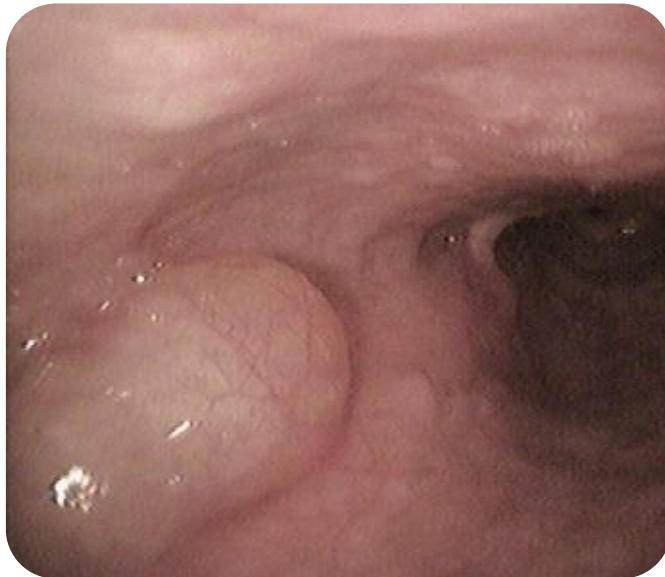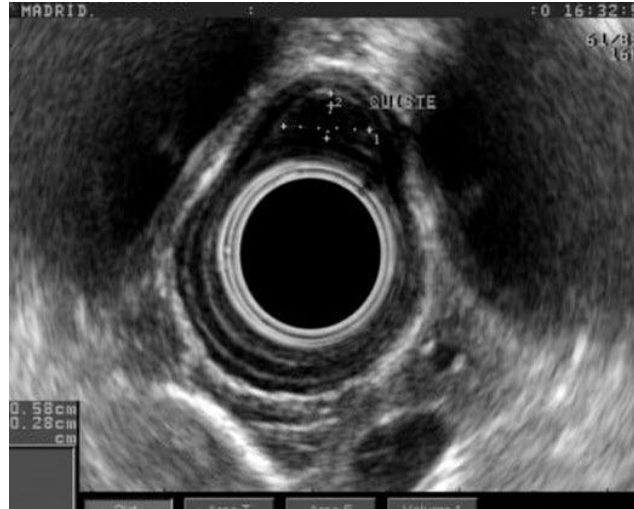
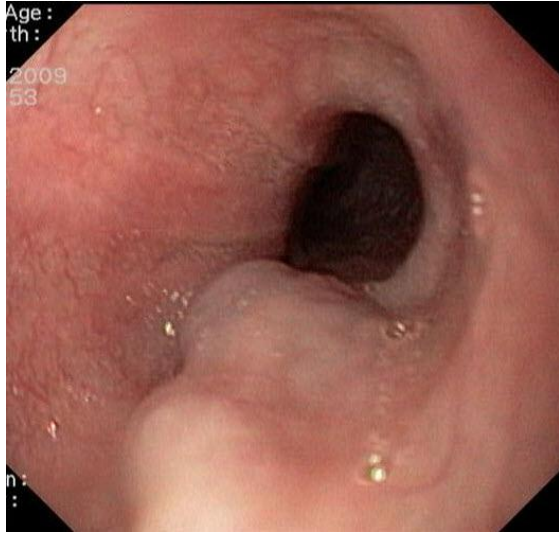
TUMOR CÉLULAS GRANULARES (ABRIKOSOFF)



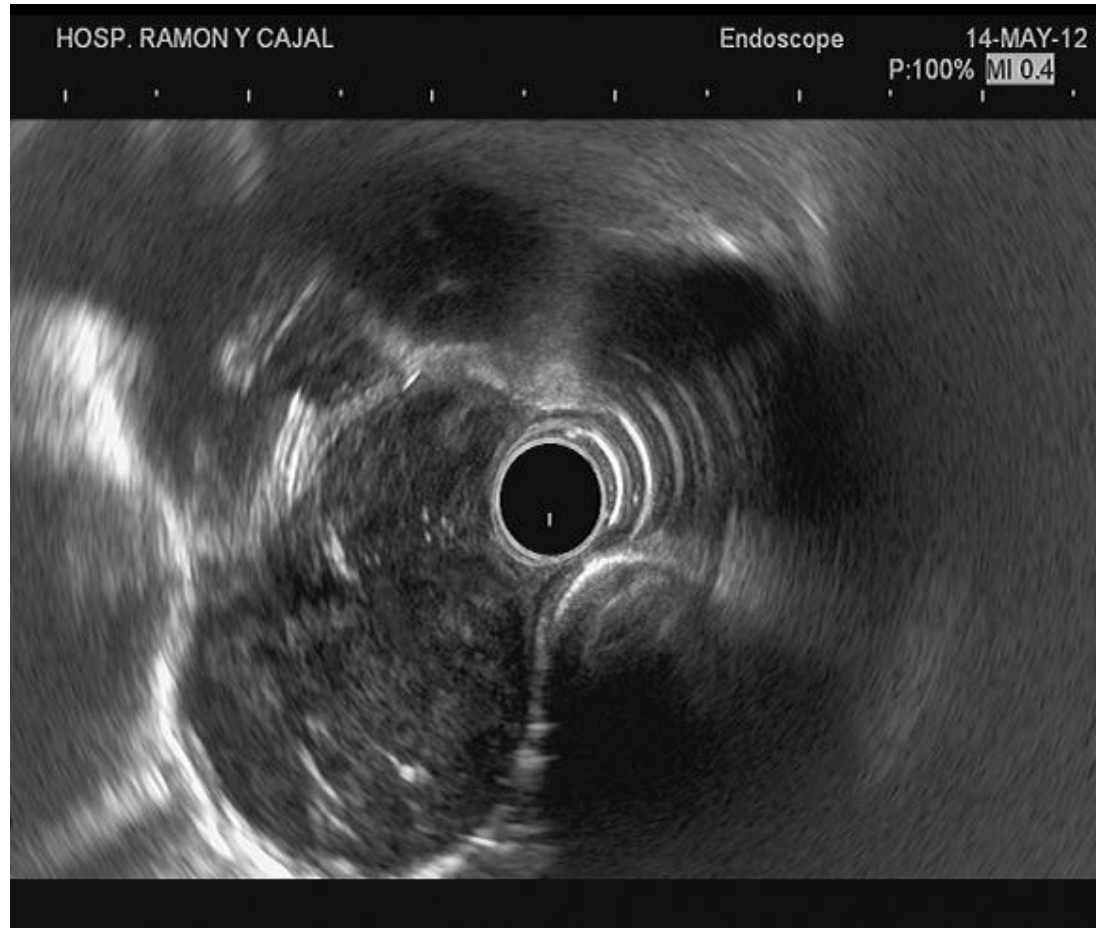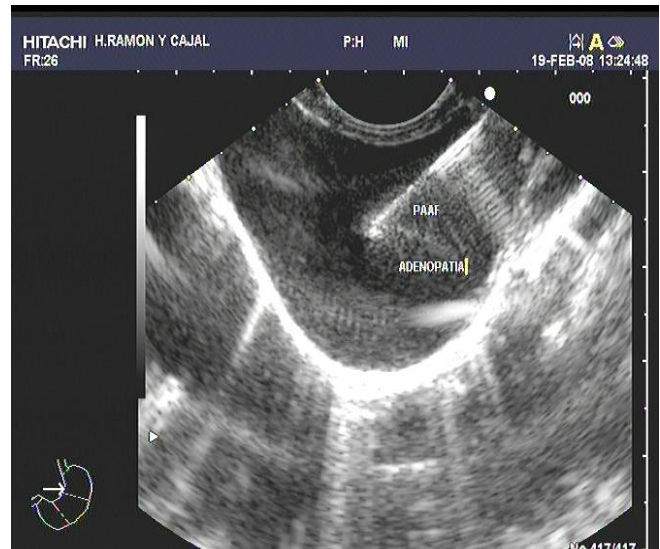
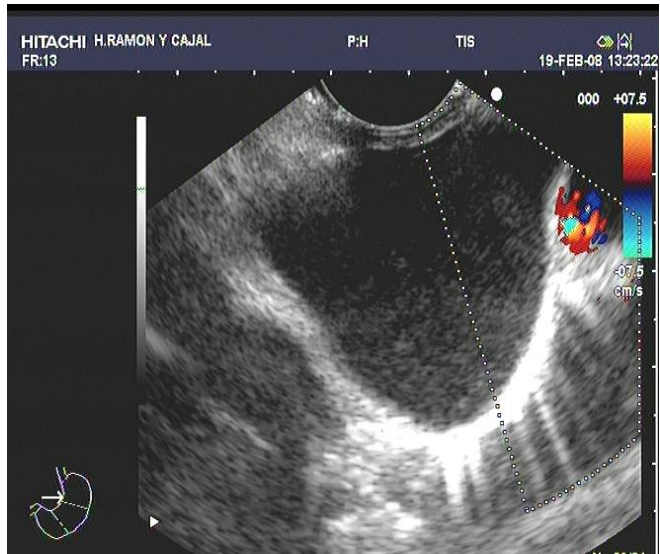
TUMOR CÉLULAS GRANULARES (ABRIKOSOFF)



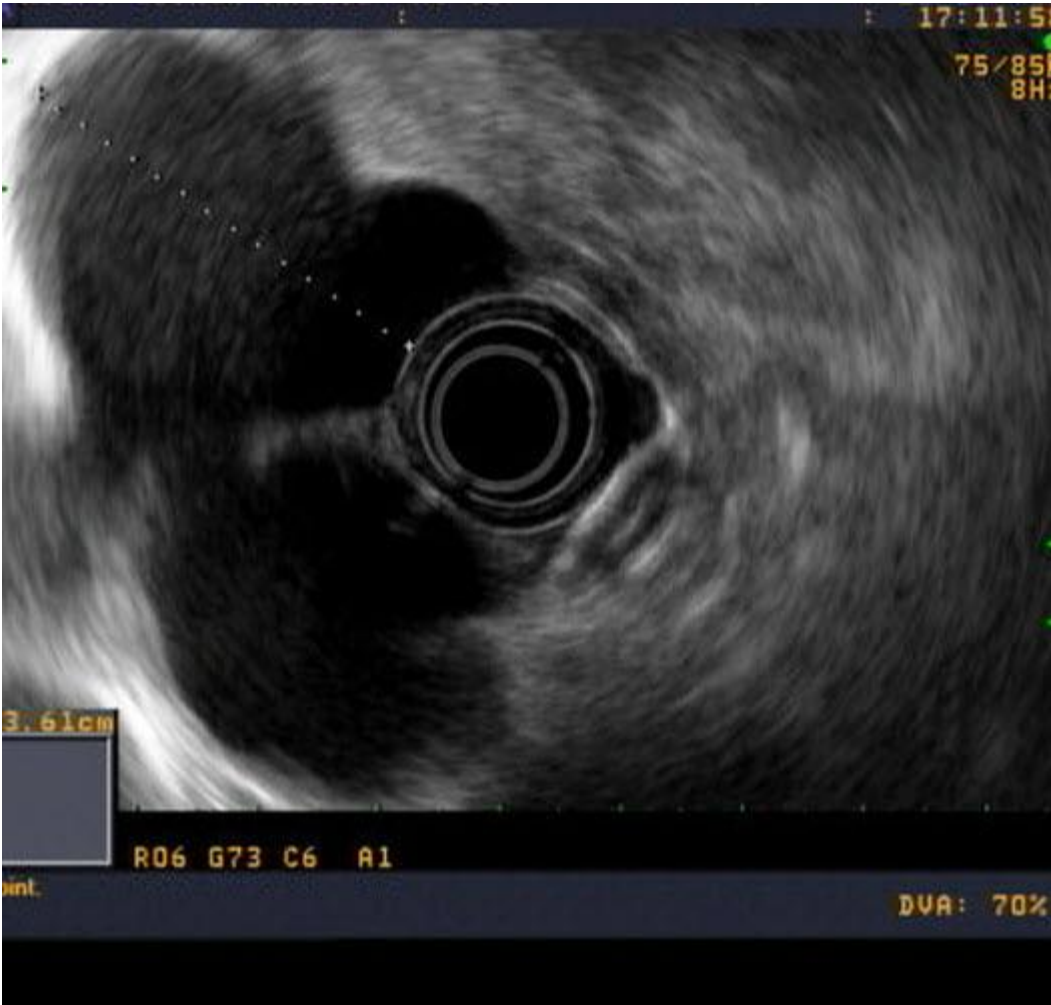QUISTE DUPLICACIÓN ESOFÁGICO



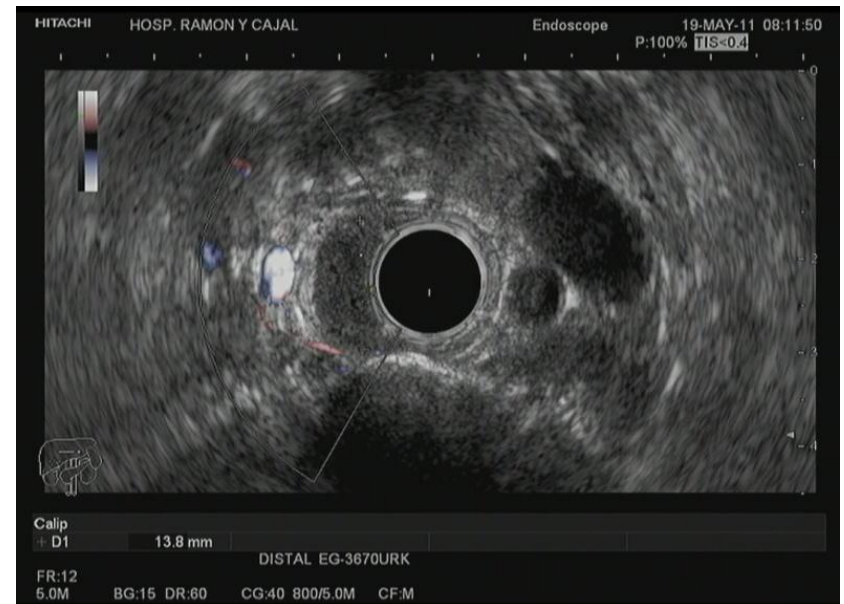
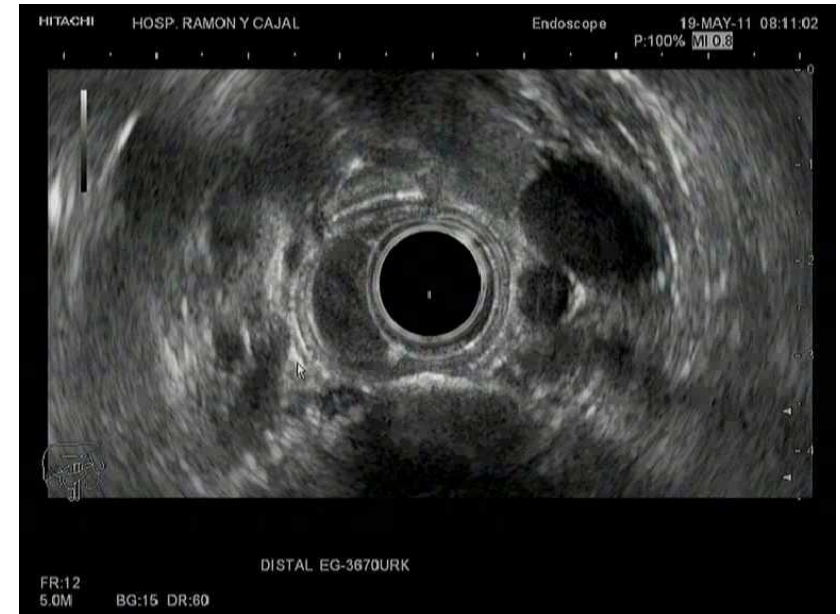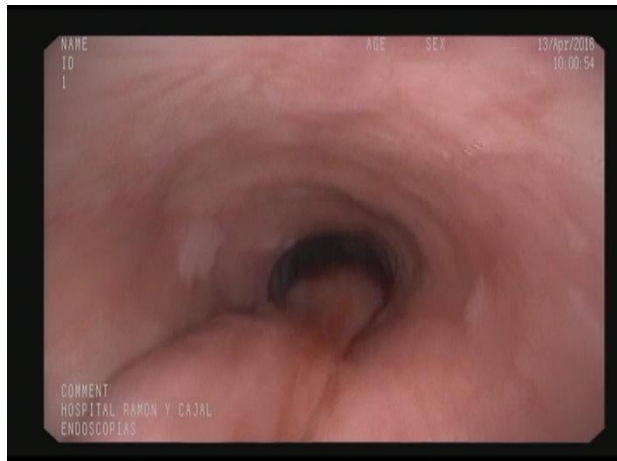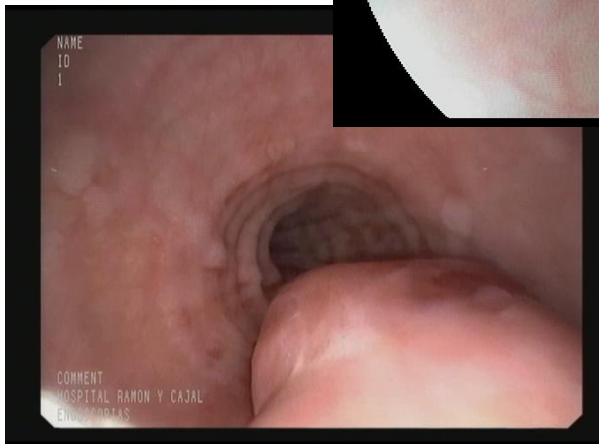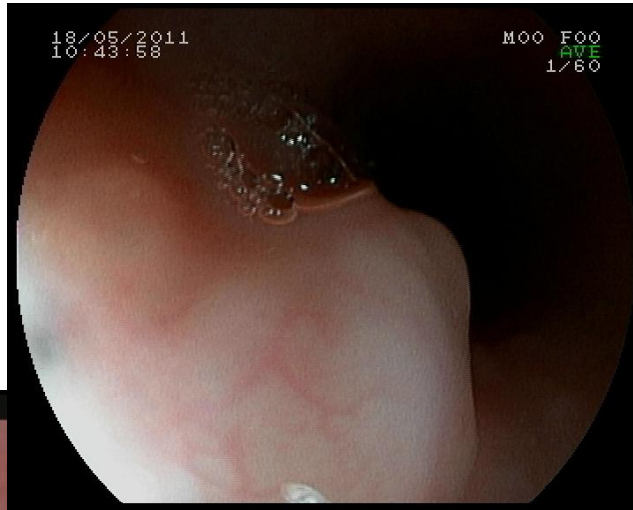QUISTE DUPLICACIÓN ESOFÁGICO



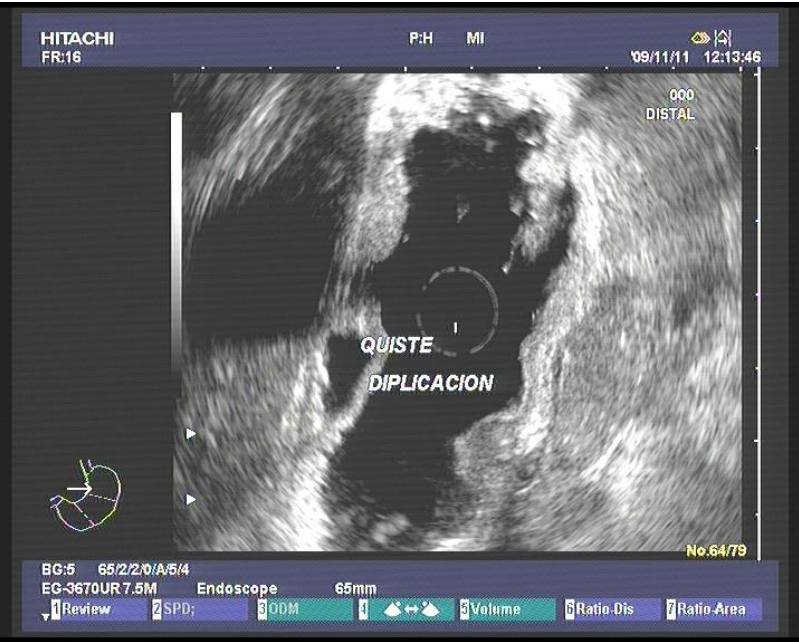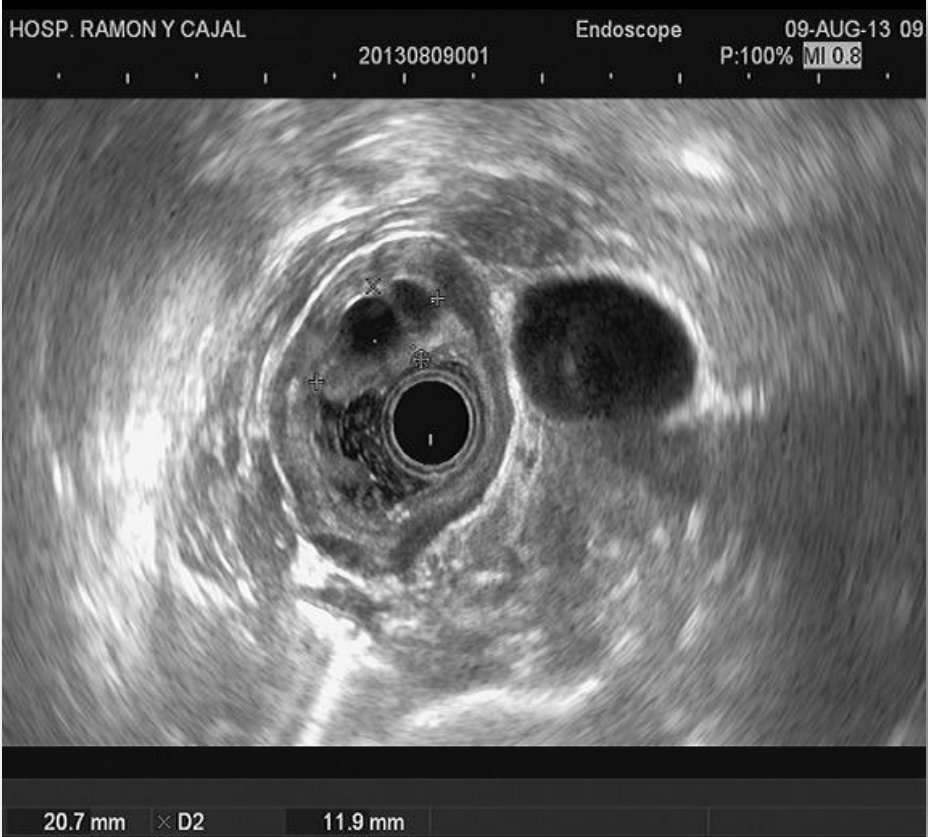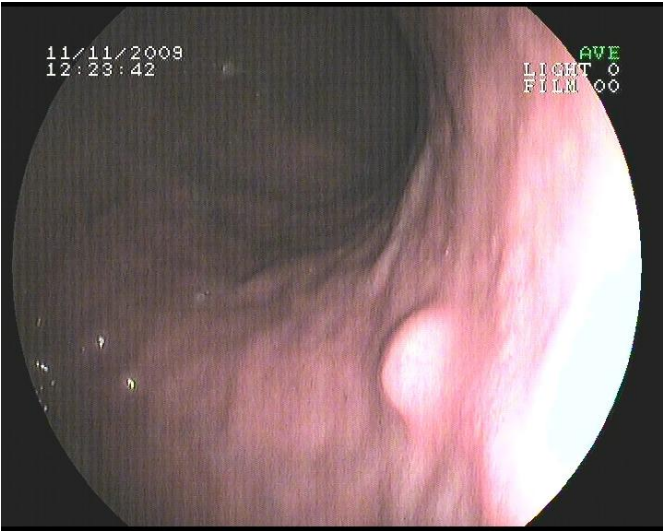
QUISTE MEDIASTÍNICO BRONCOGÉNICO



PÓLIPO ESOFÁGICO FIBROVASCULAR

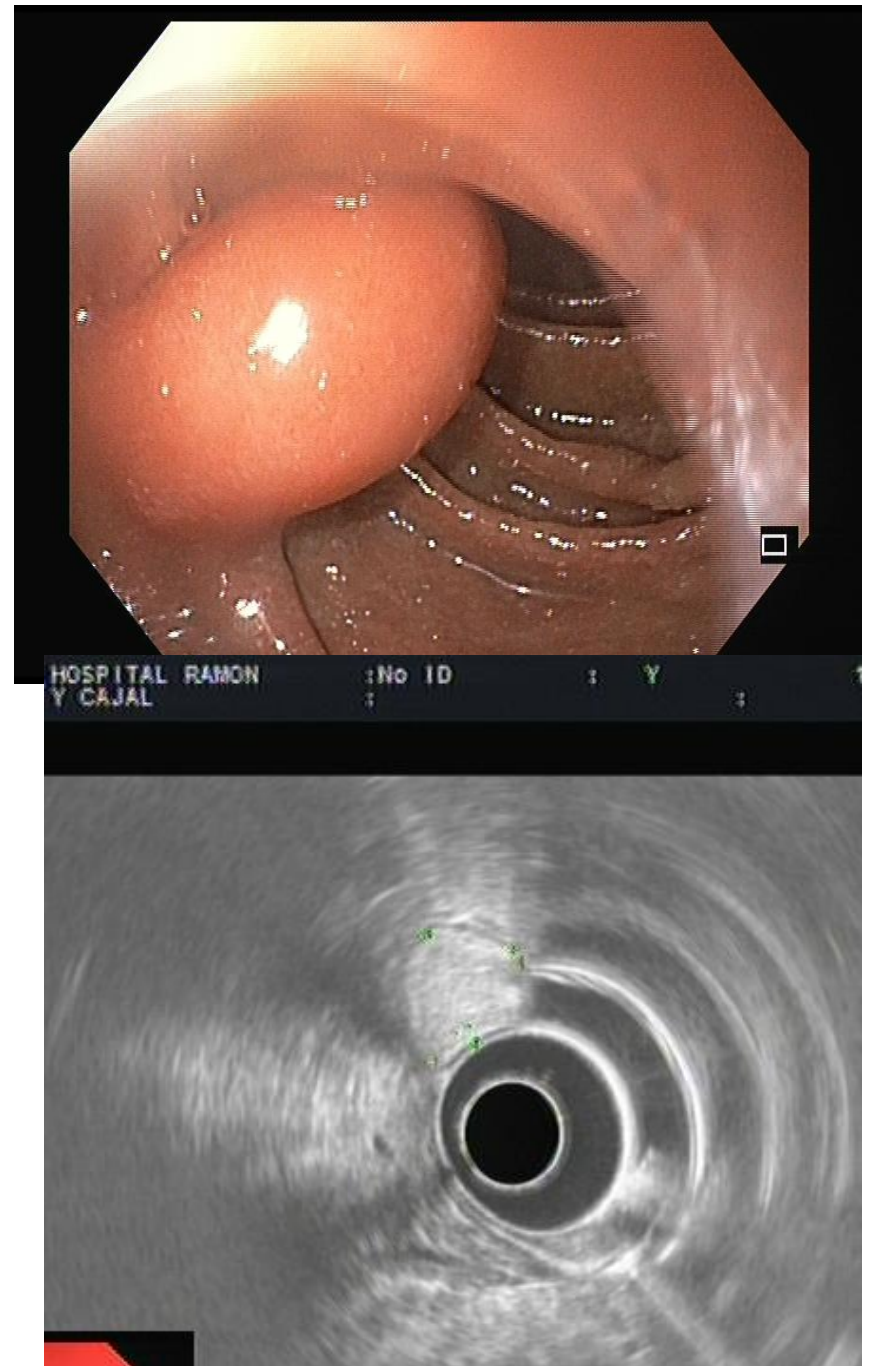
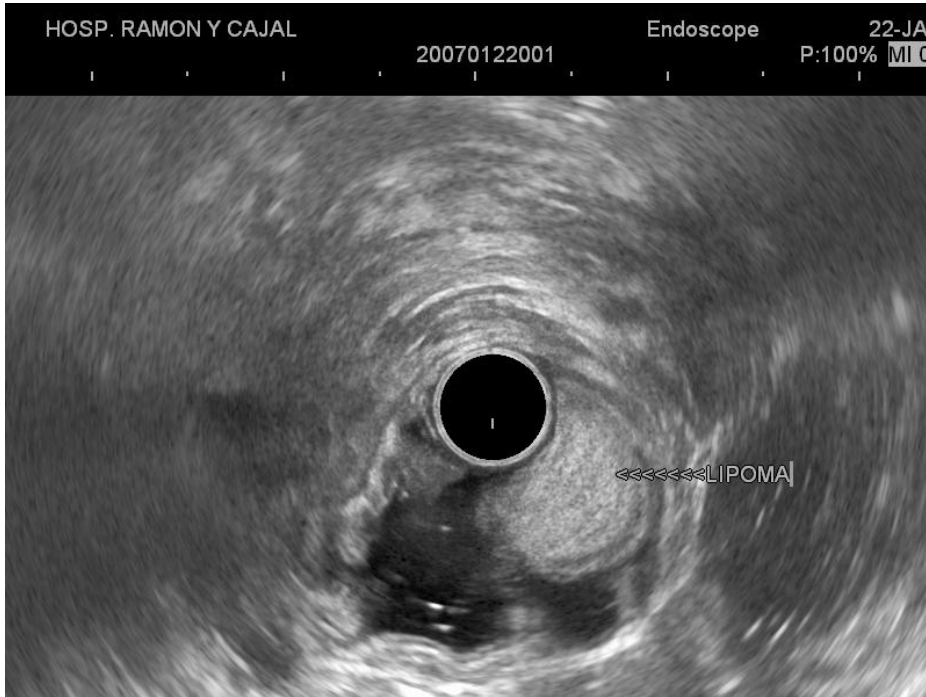


QUISTES DUPLICACIÓN PARED GÁSTRICA

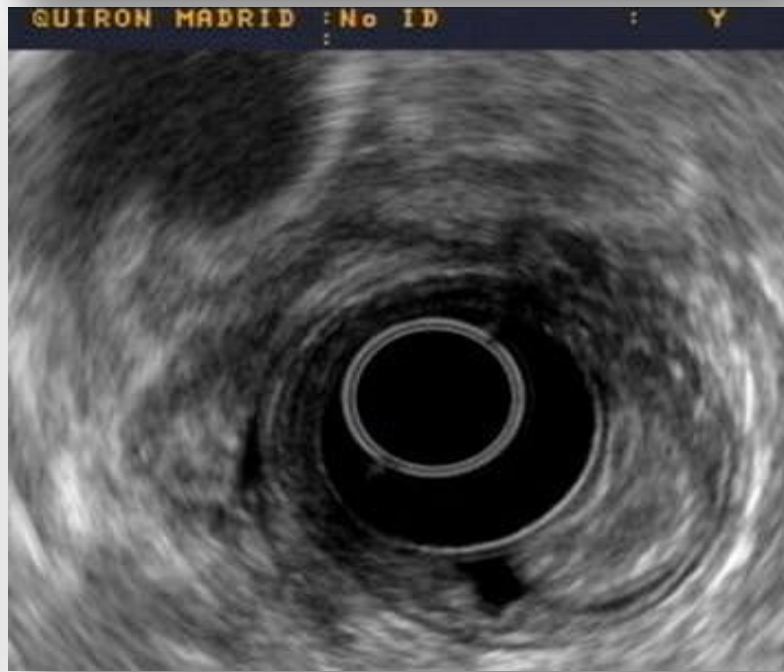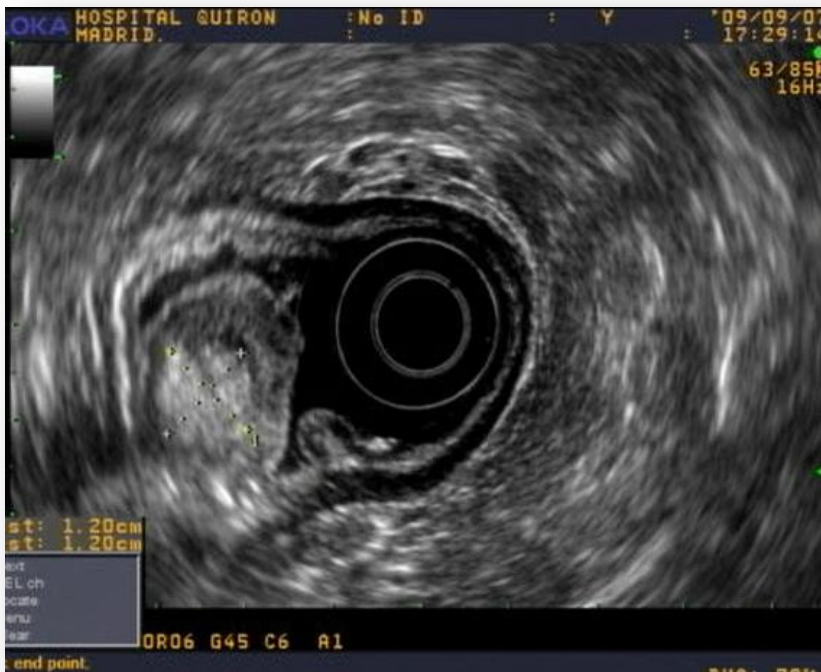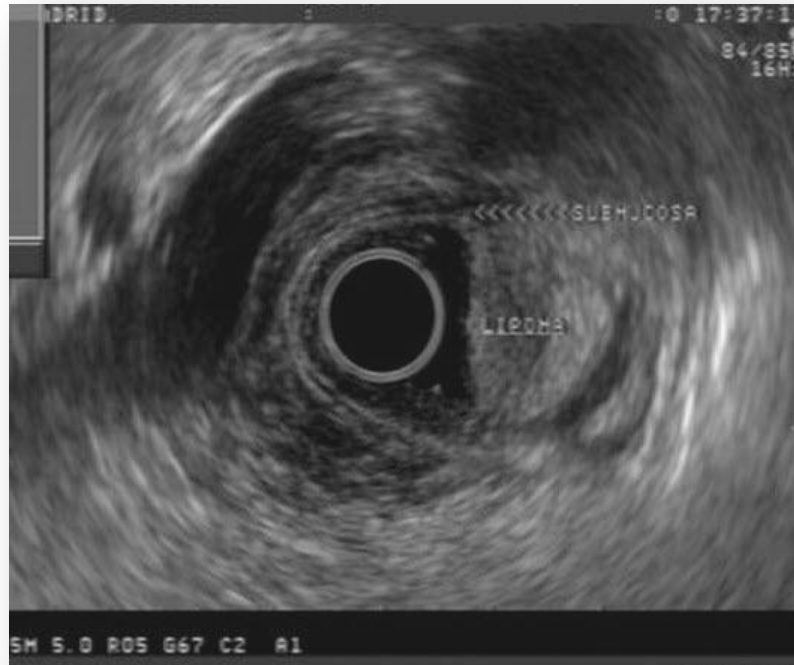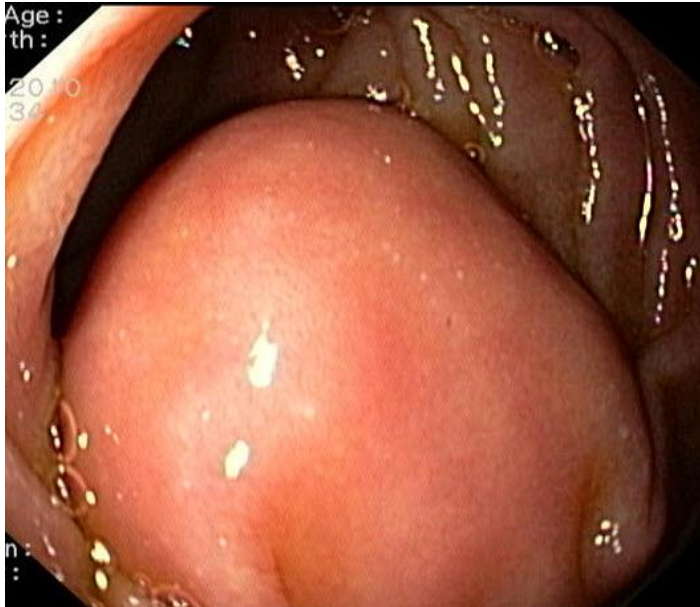


LIPOMA

Duodenal

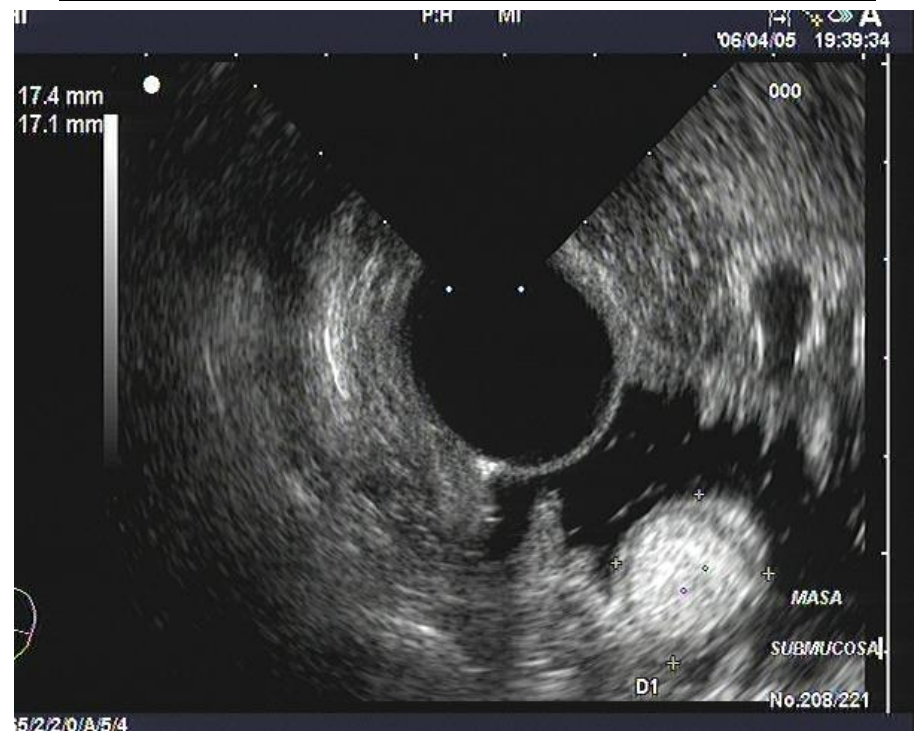
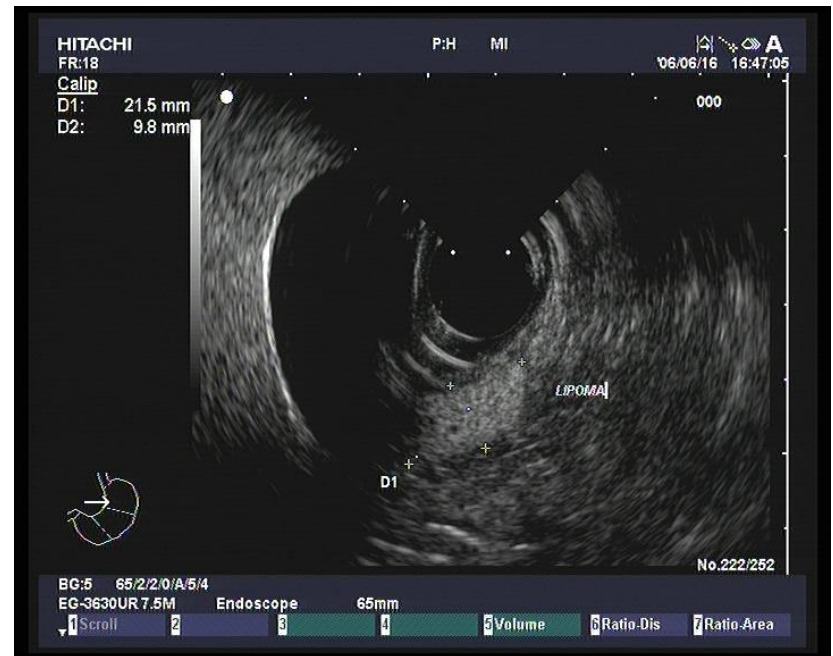
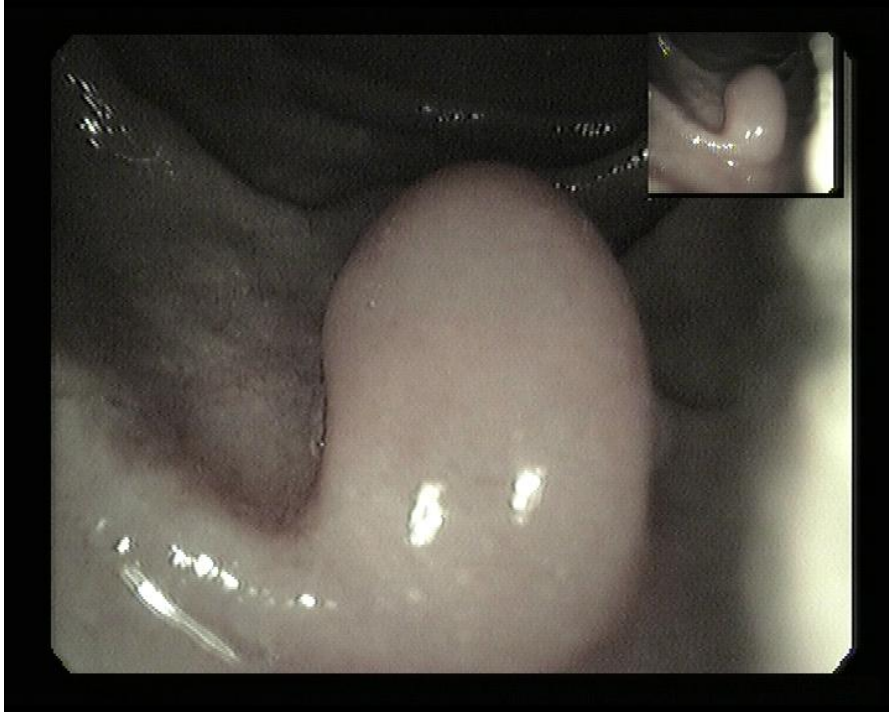LIPOMA Duodenal



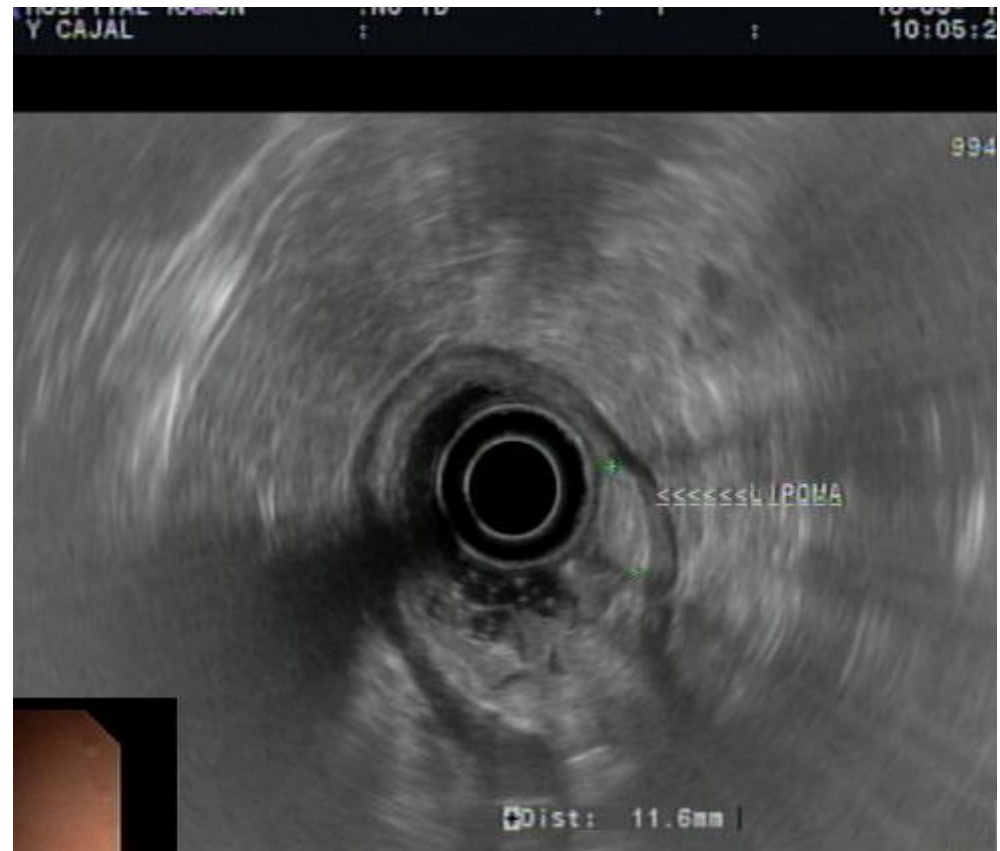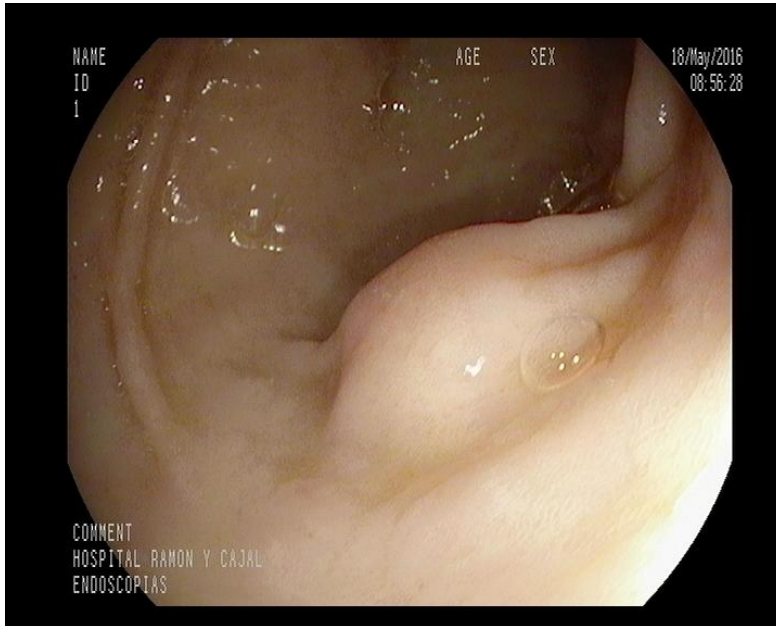
LIPOMA

Duodenal



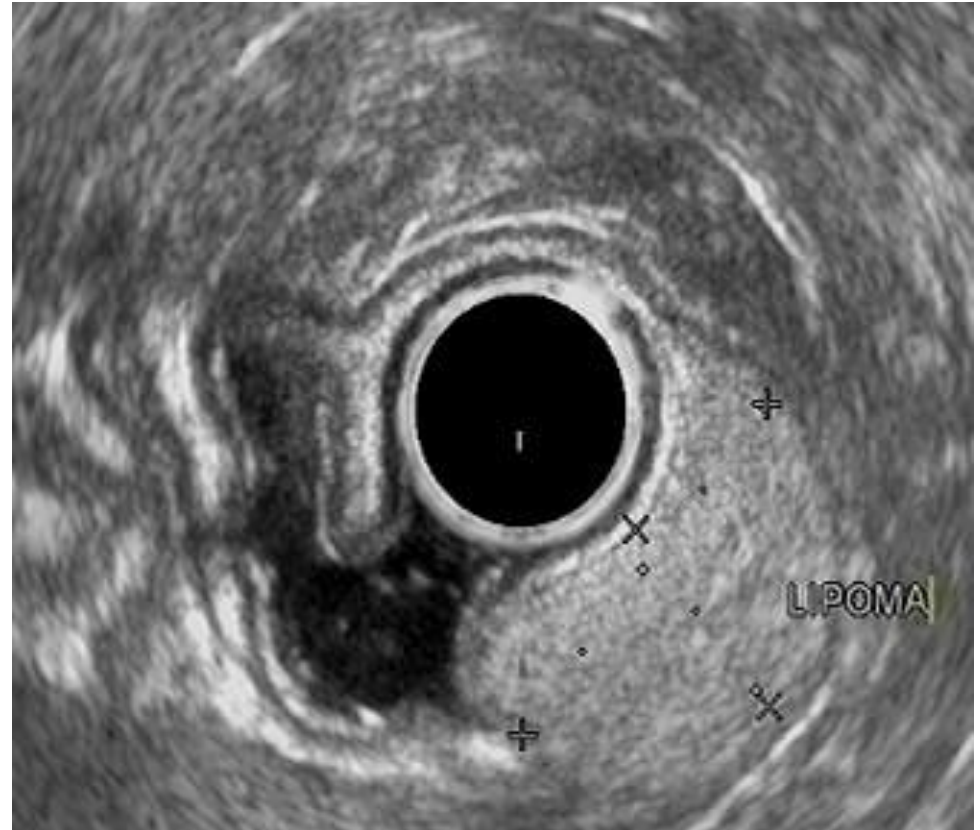
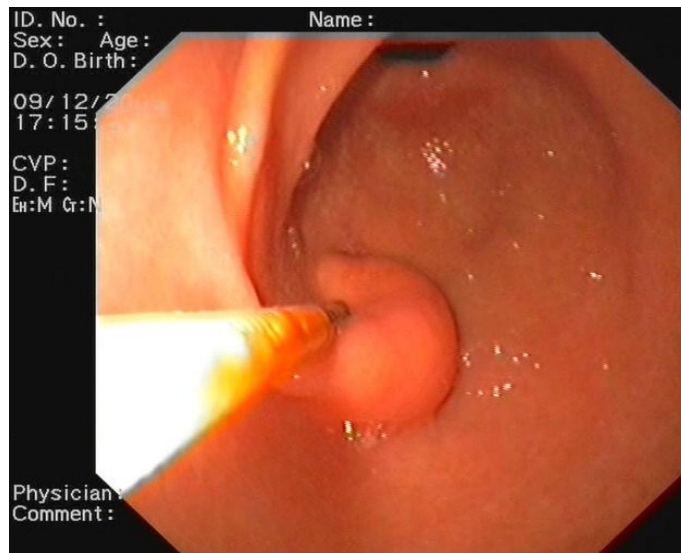
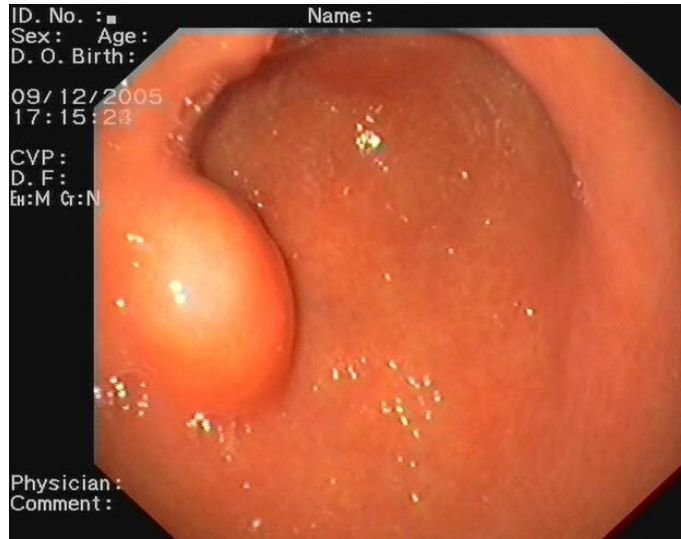
LIPOMA

Gástrico

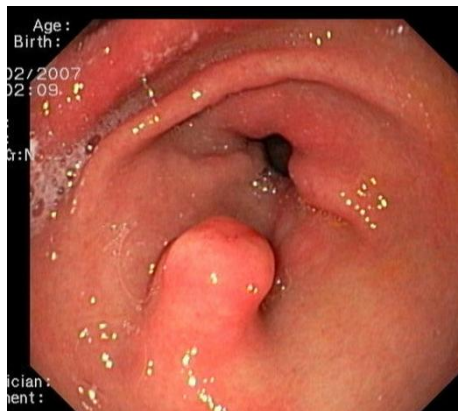
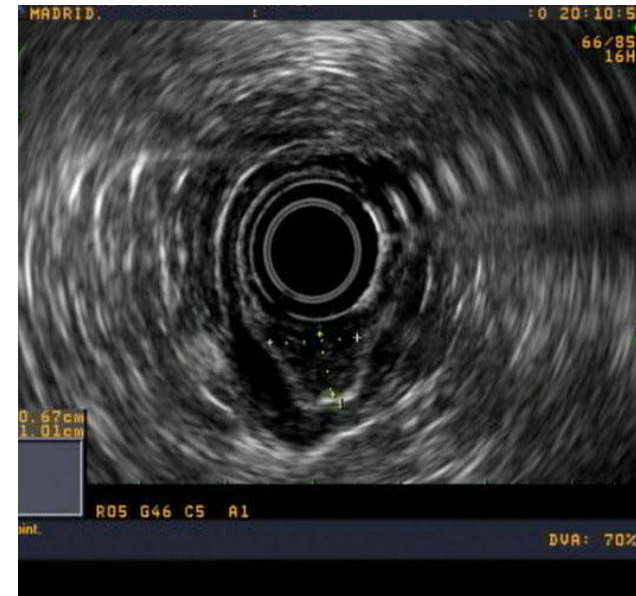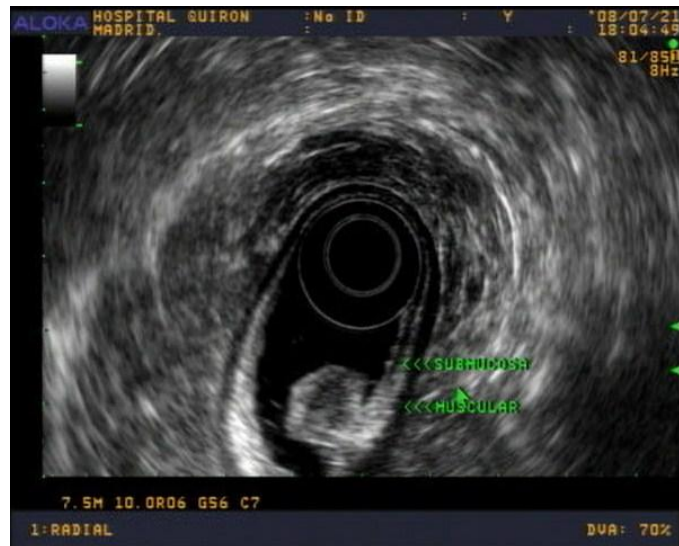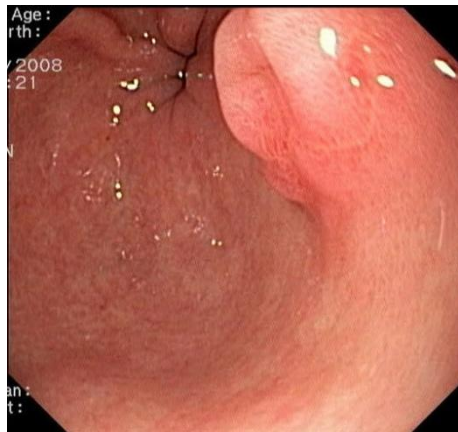
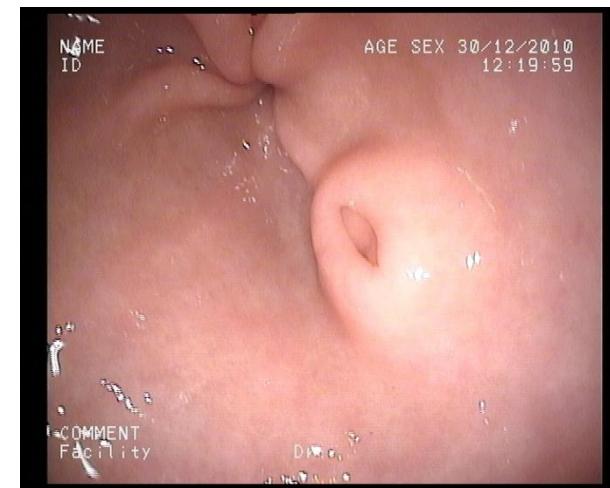


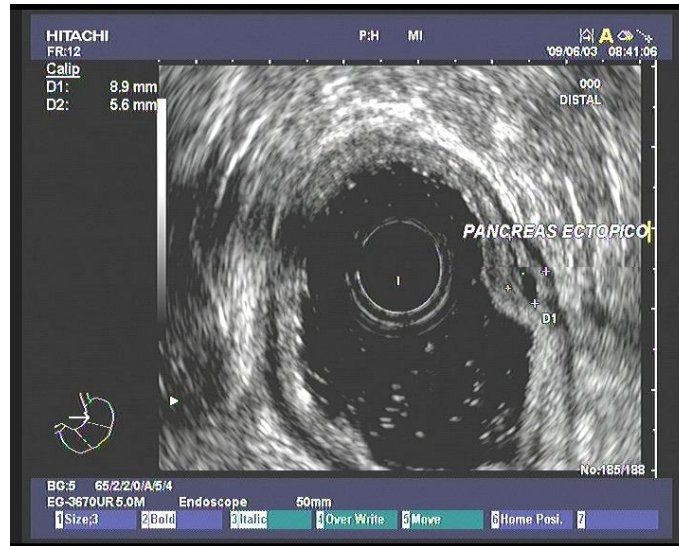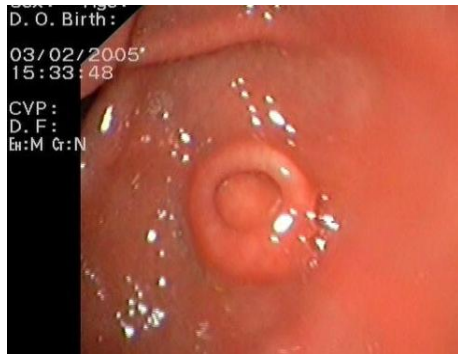LIPOMA

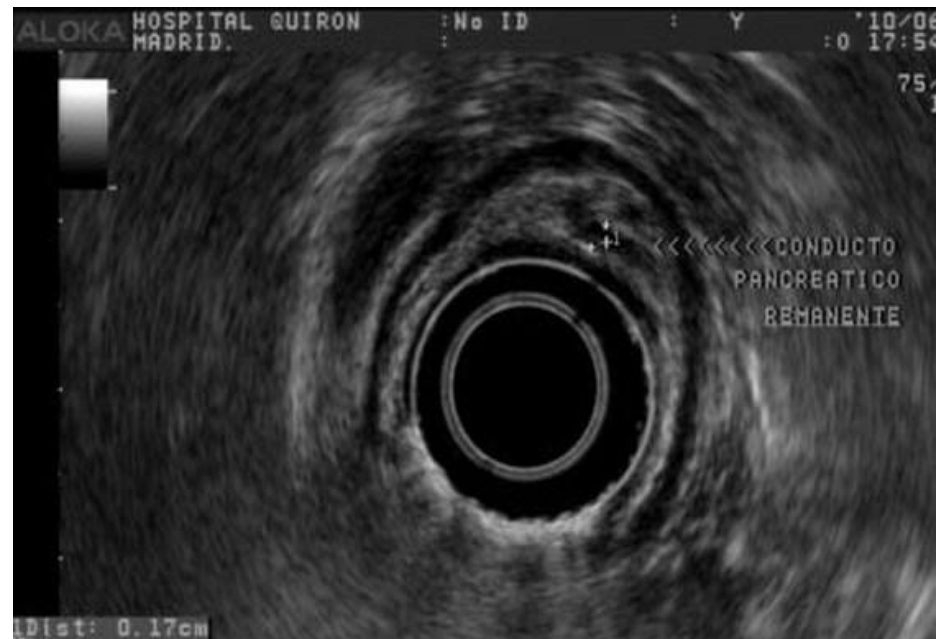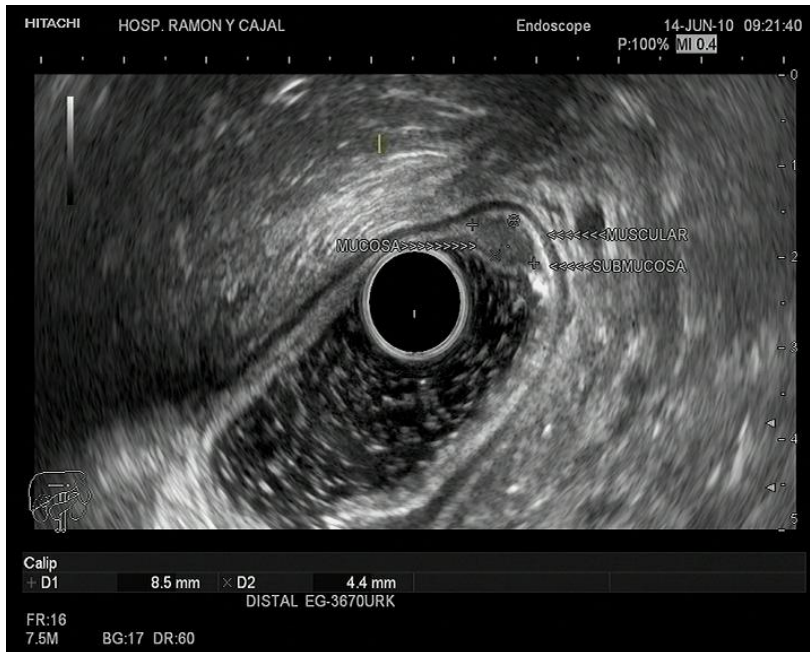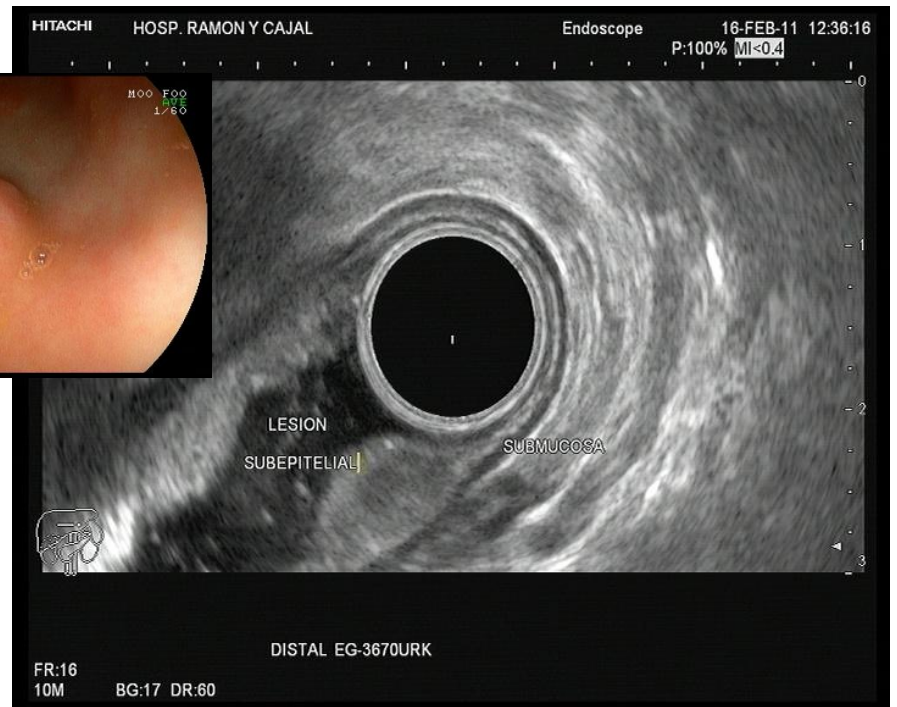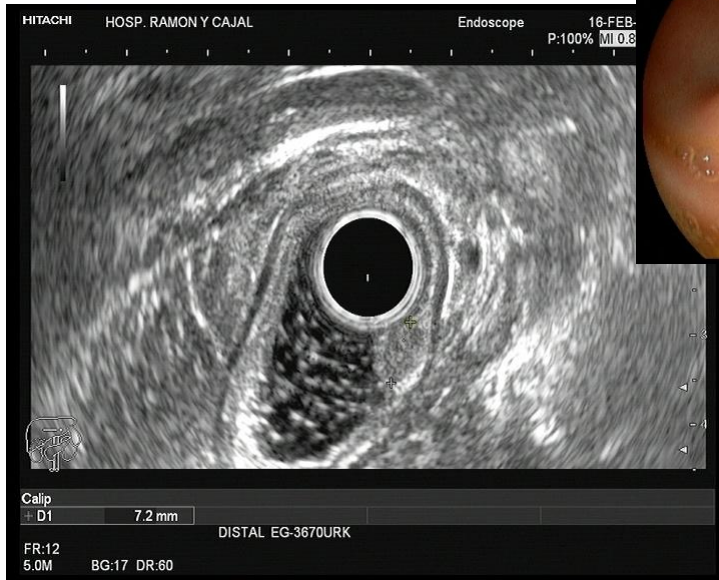Gástrico



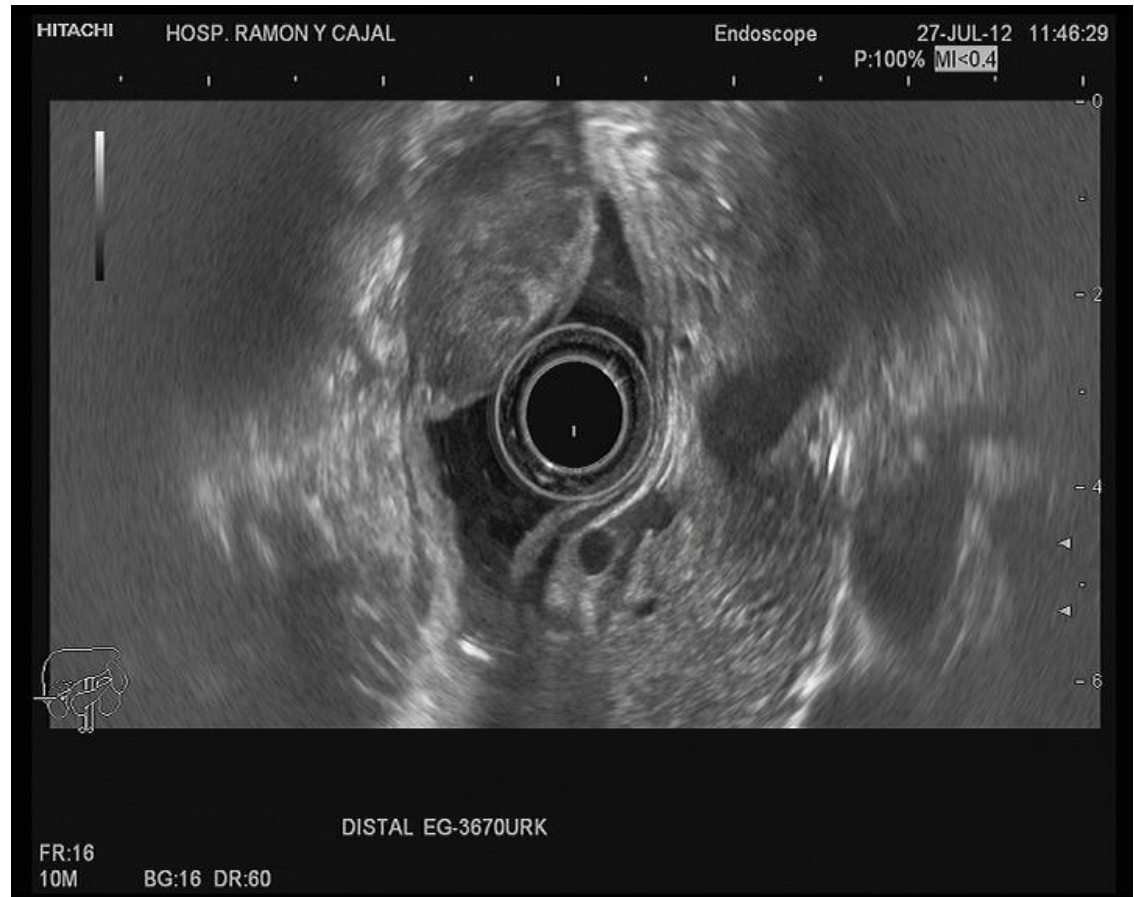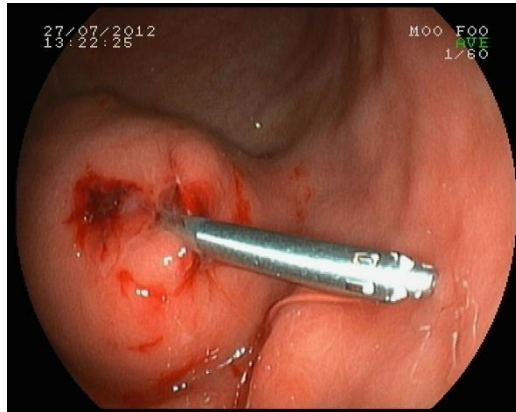
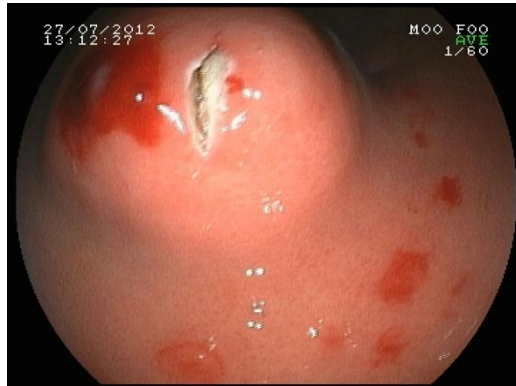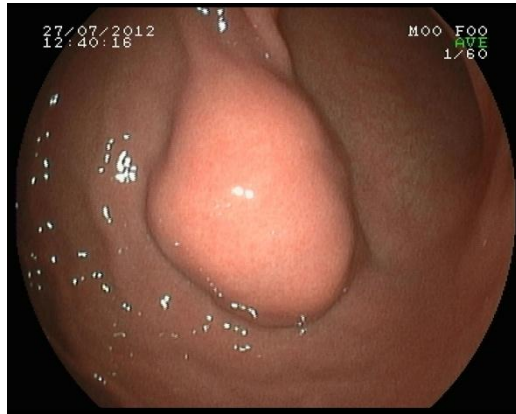
PÁNCREAS ECTÓPICO



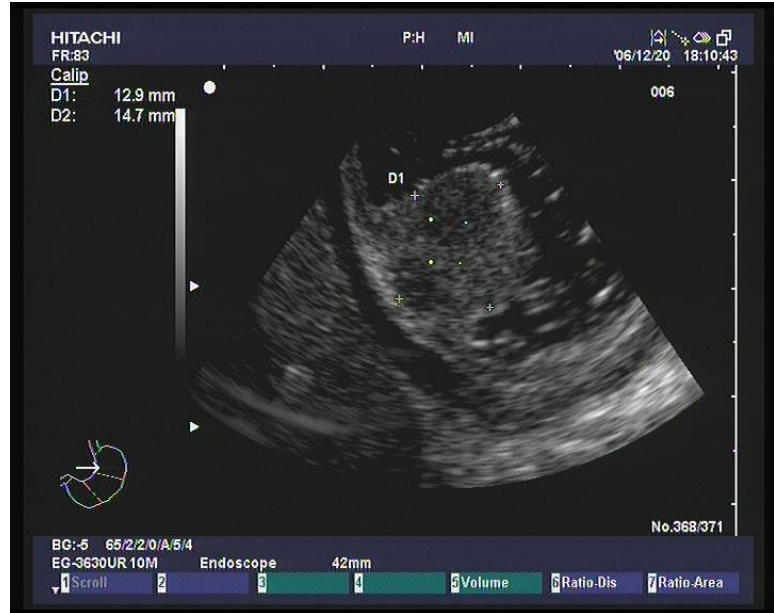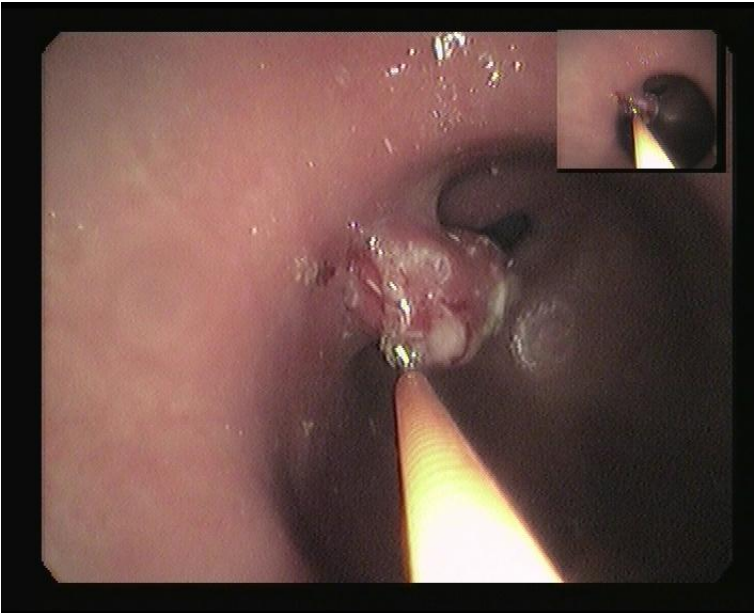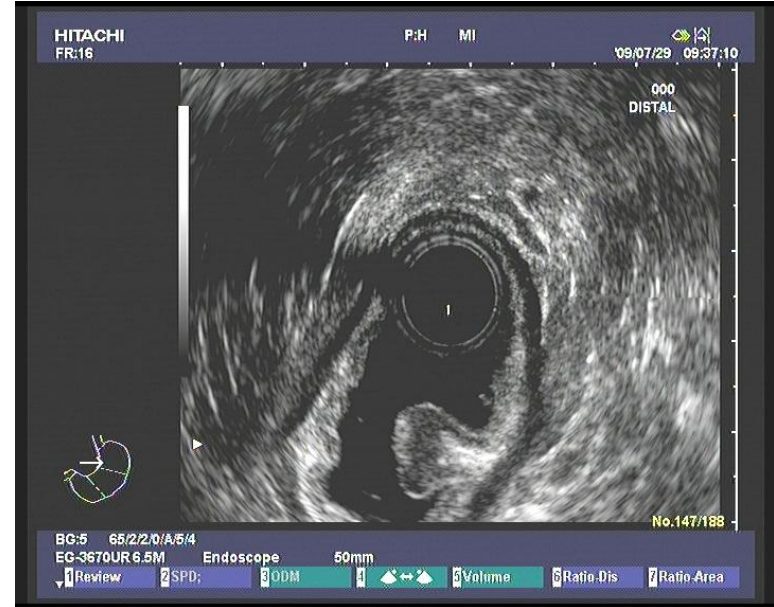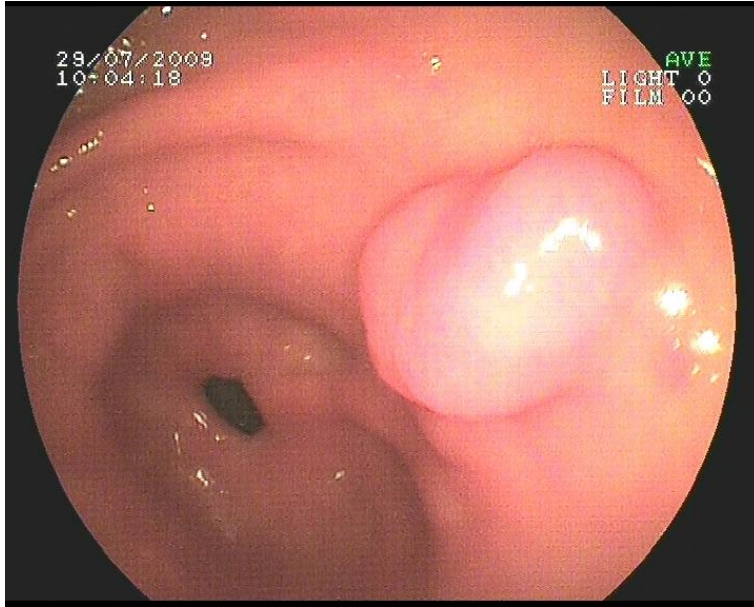
PÁNCREAS ECTÓPICO



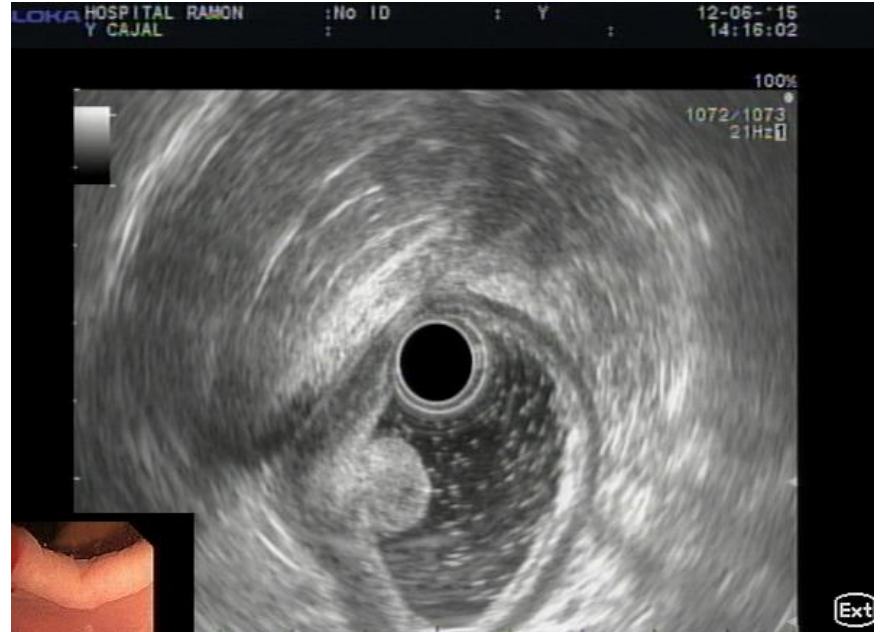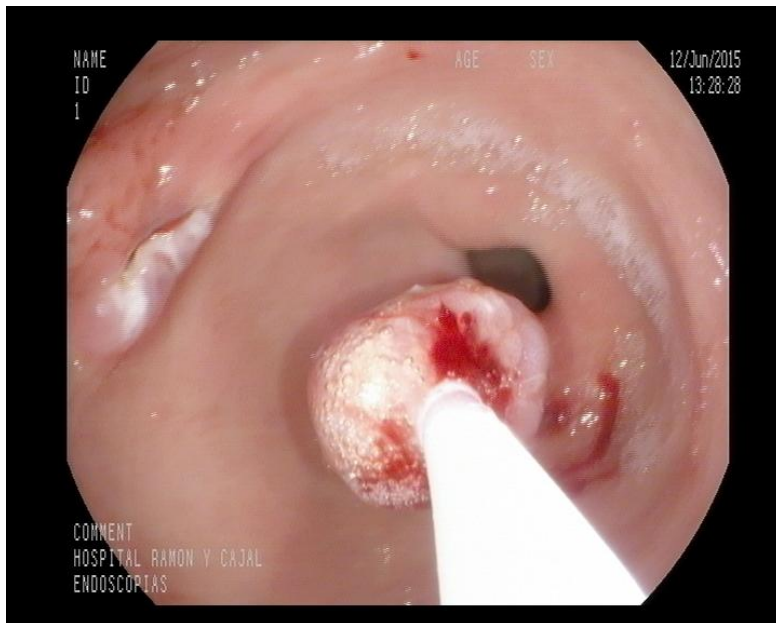
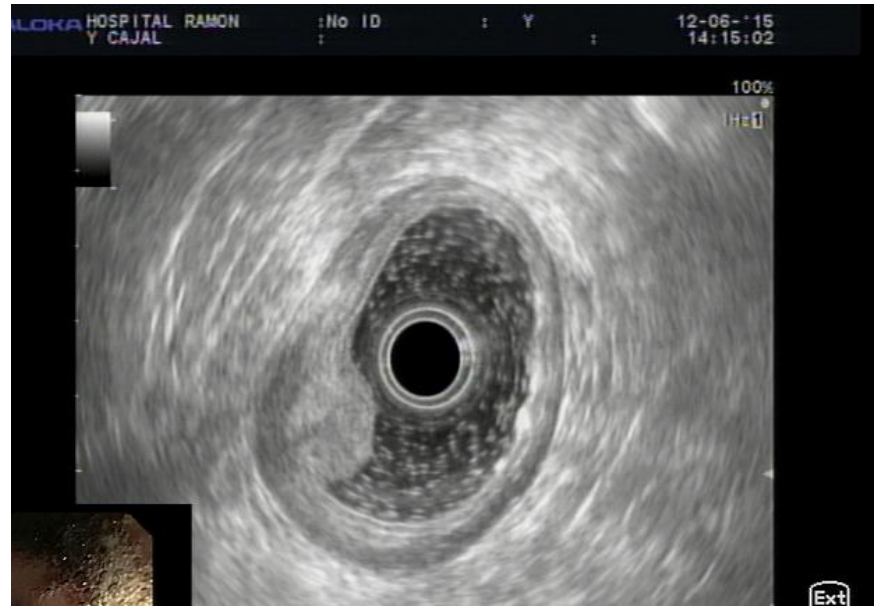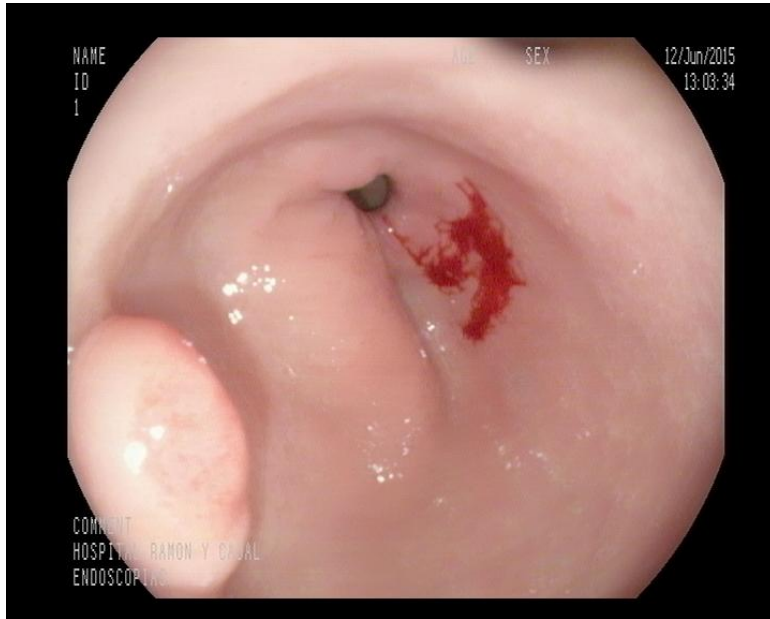PÁNCREAS ECTÓPICO



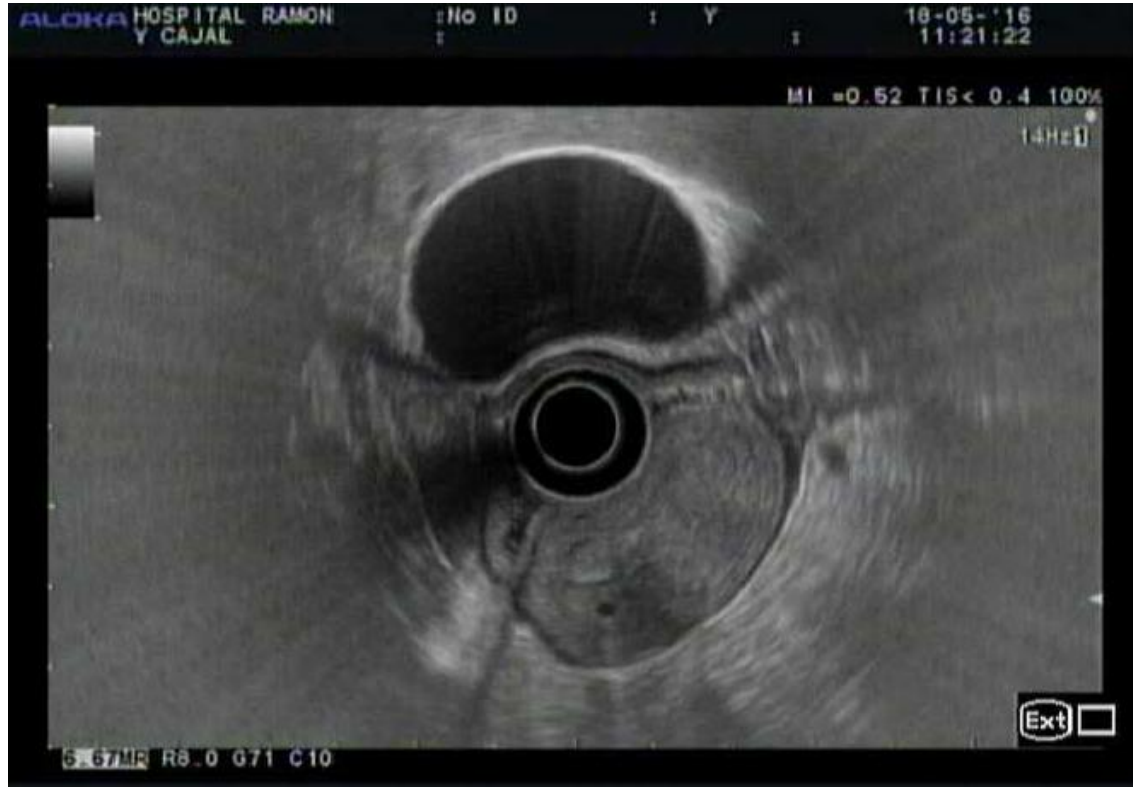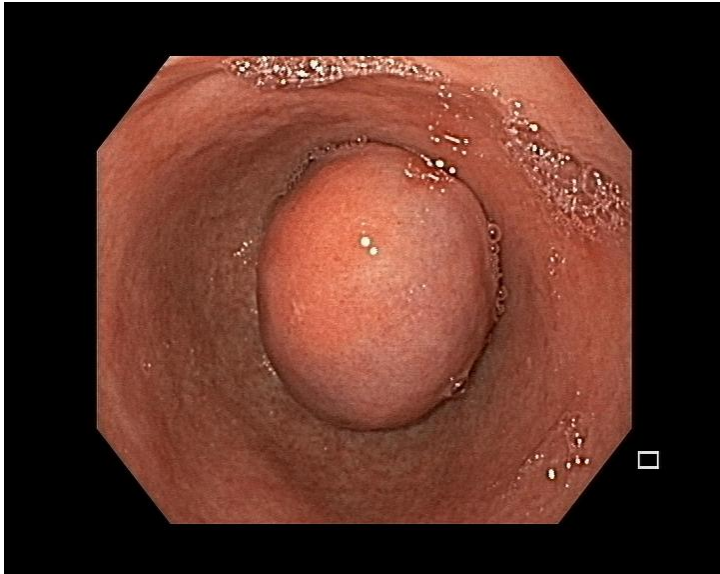
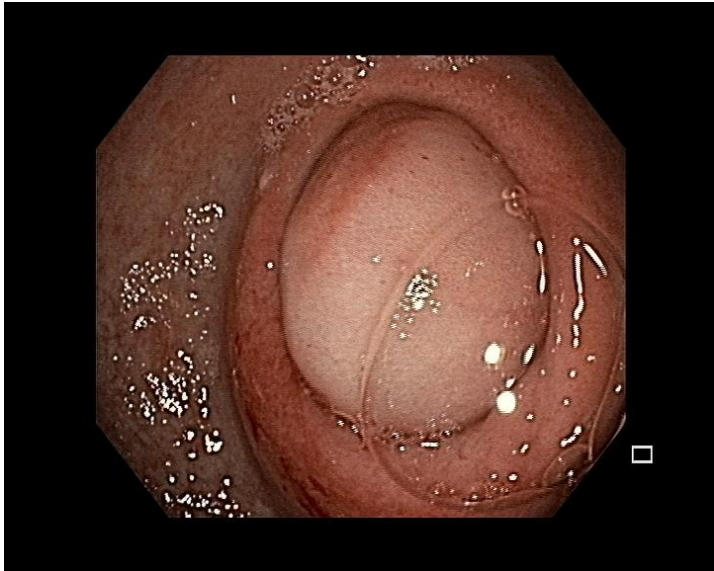
PÓLIPO INFLAMMATÓRIO MUCOSO



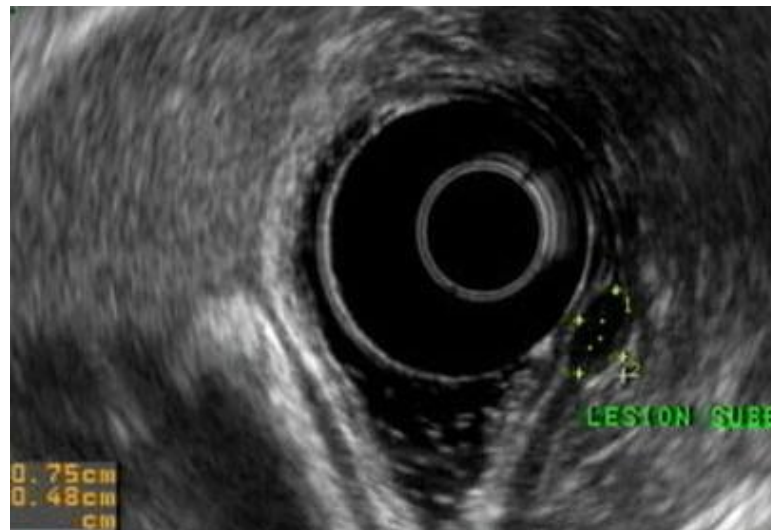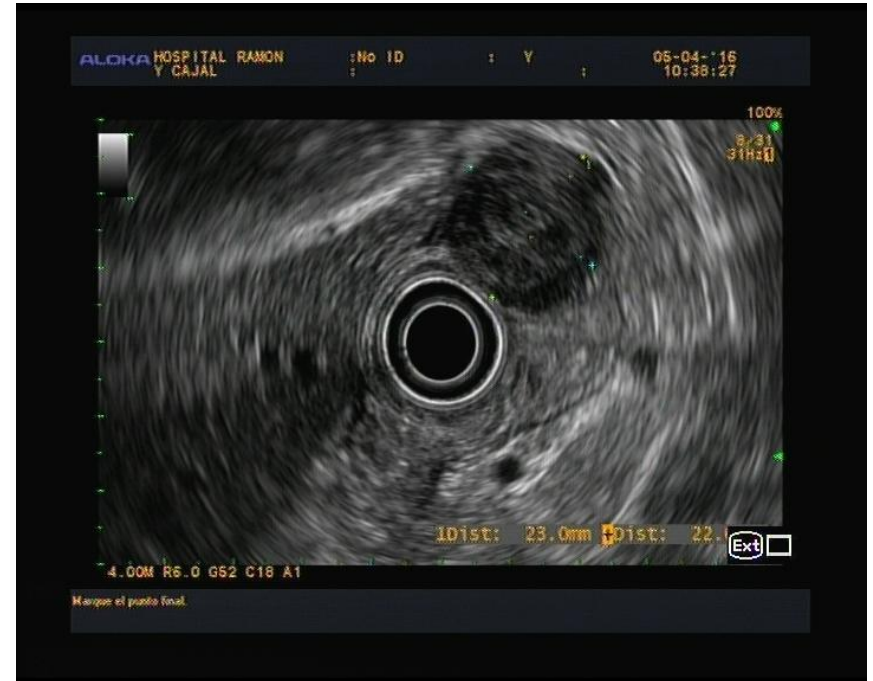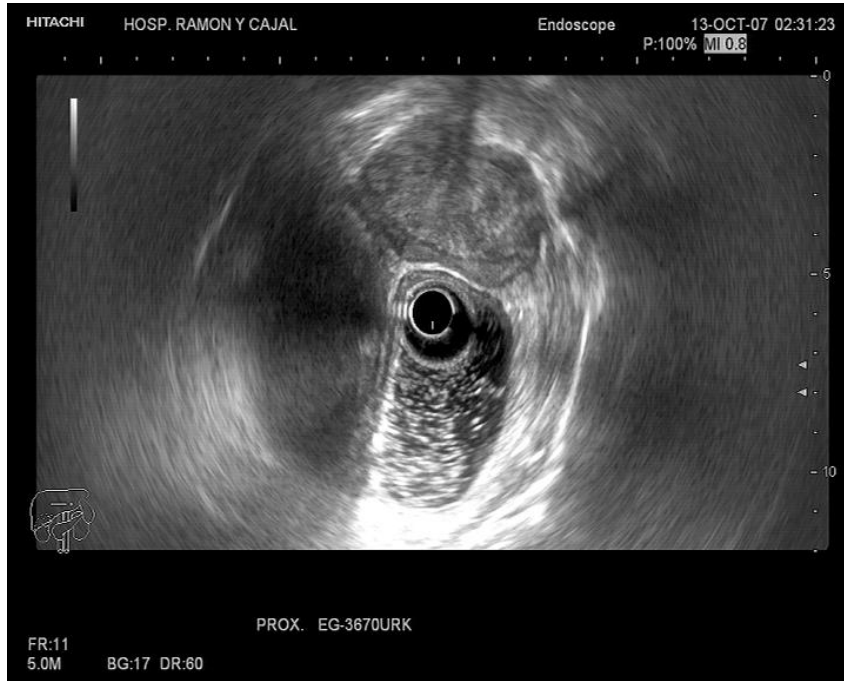PÓLIPO HAMARTOMATOSO



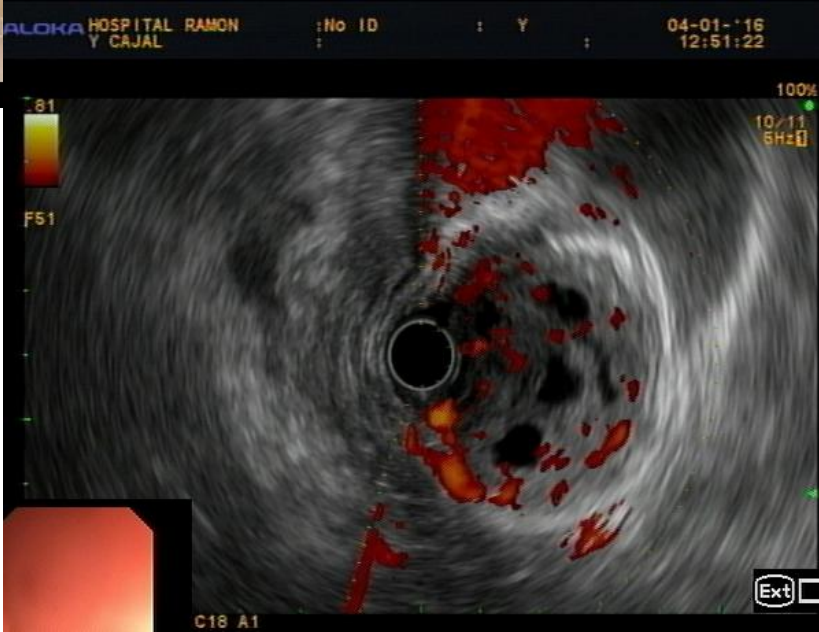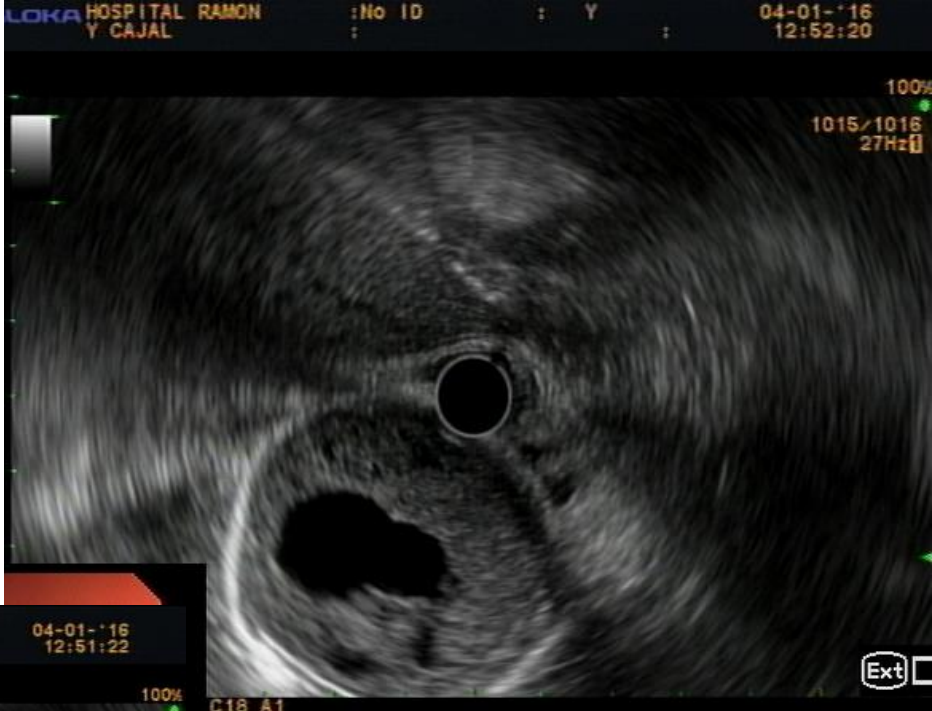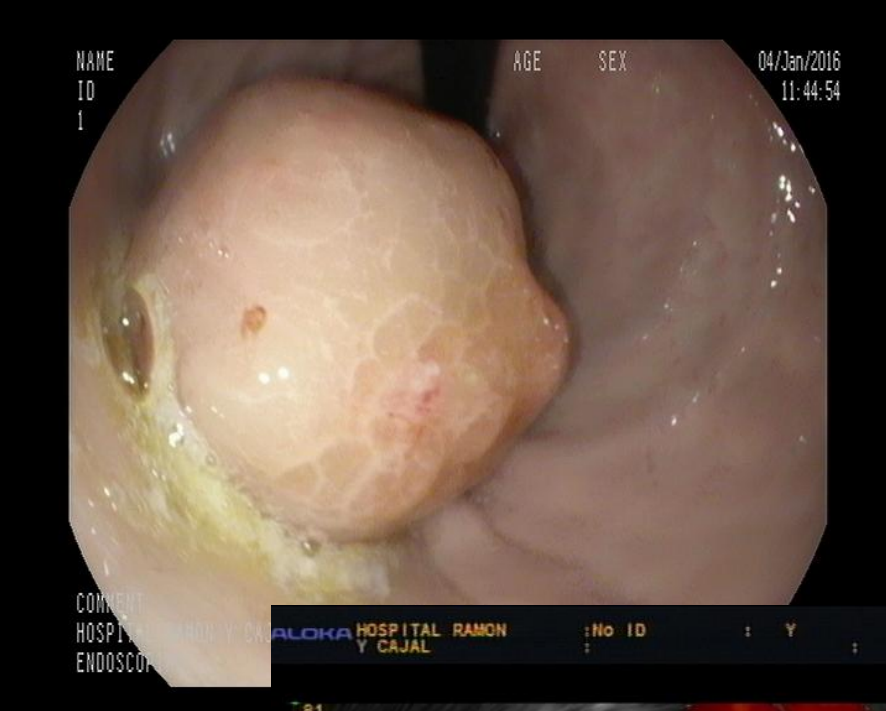
PÓLIPO DE GLÁNDULAS DE BRUNNER/BRUNNERIOMA



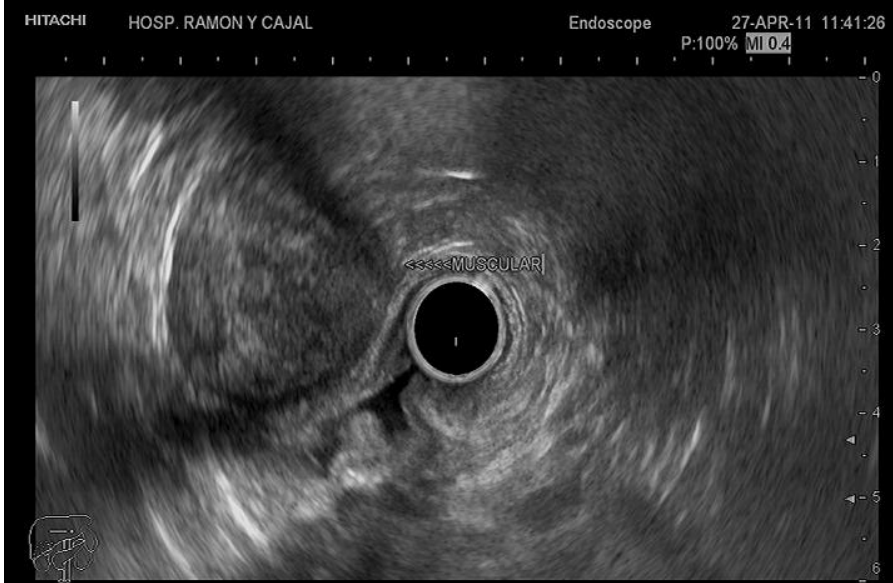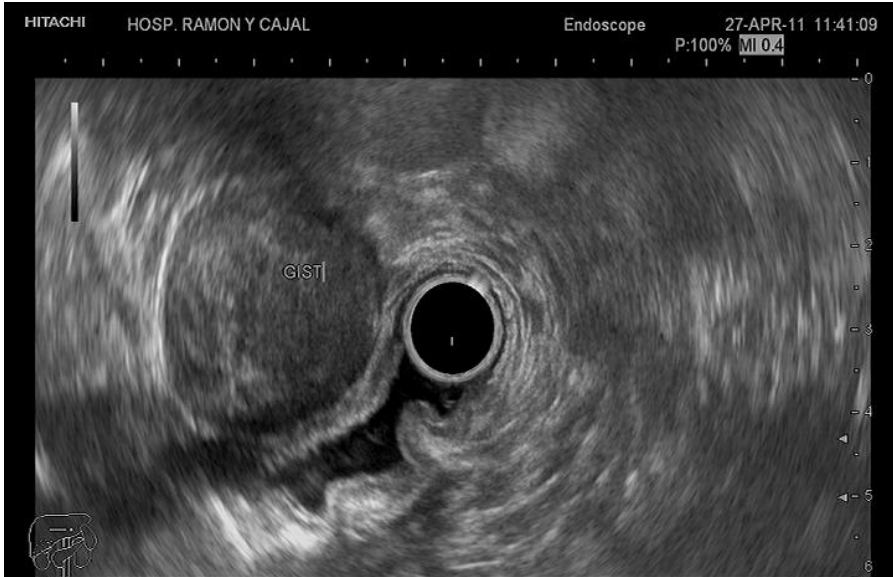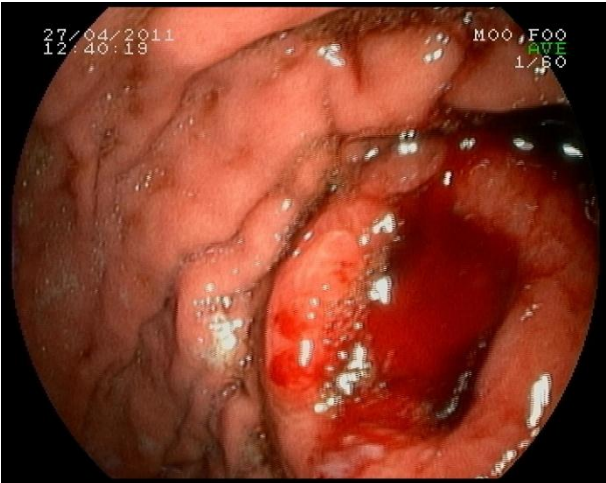
TUMOR DEL ESTROMA GASTROINTESTINAL (GIST)



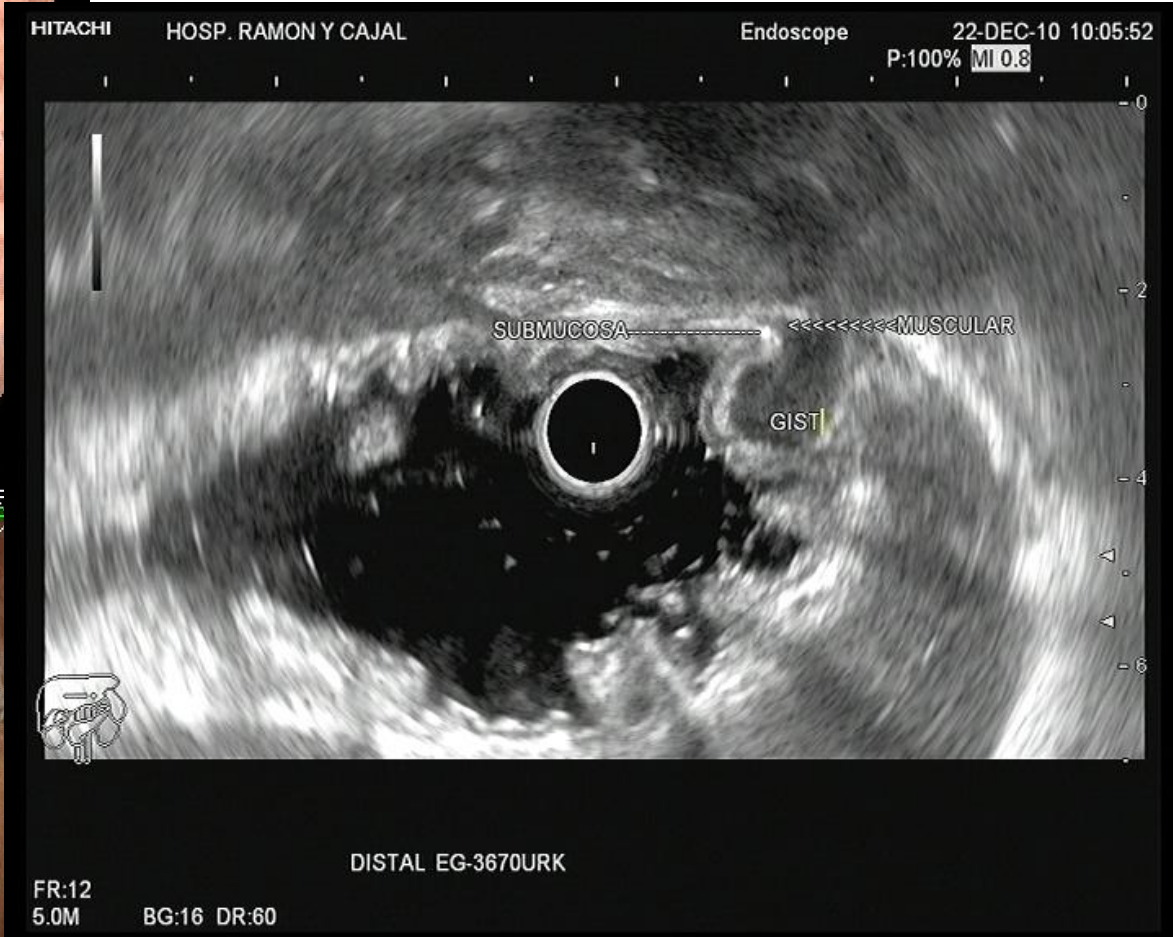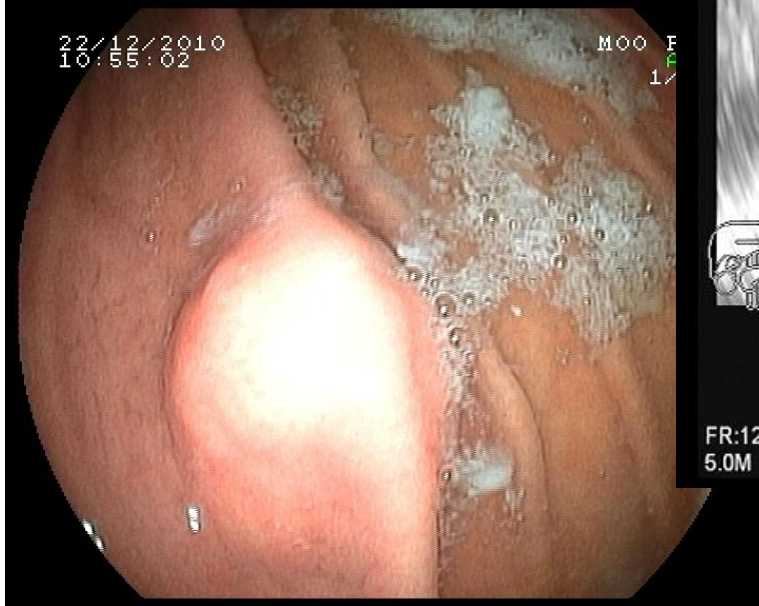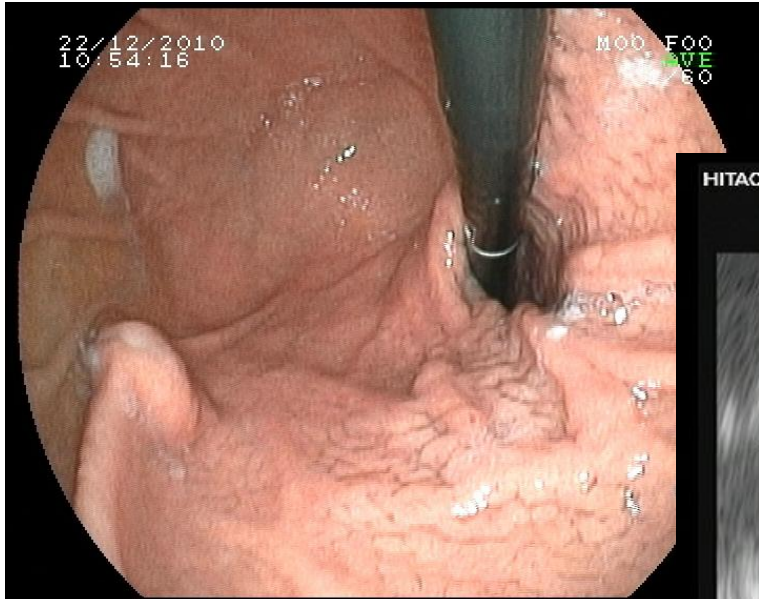
TUMOR DEL ESTROMA GASTROINTESTINAL (GIST)



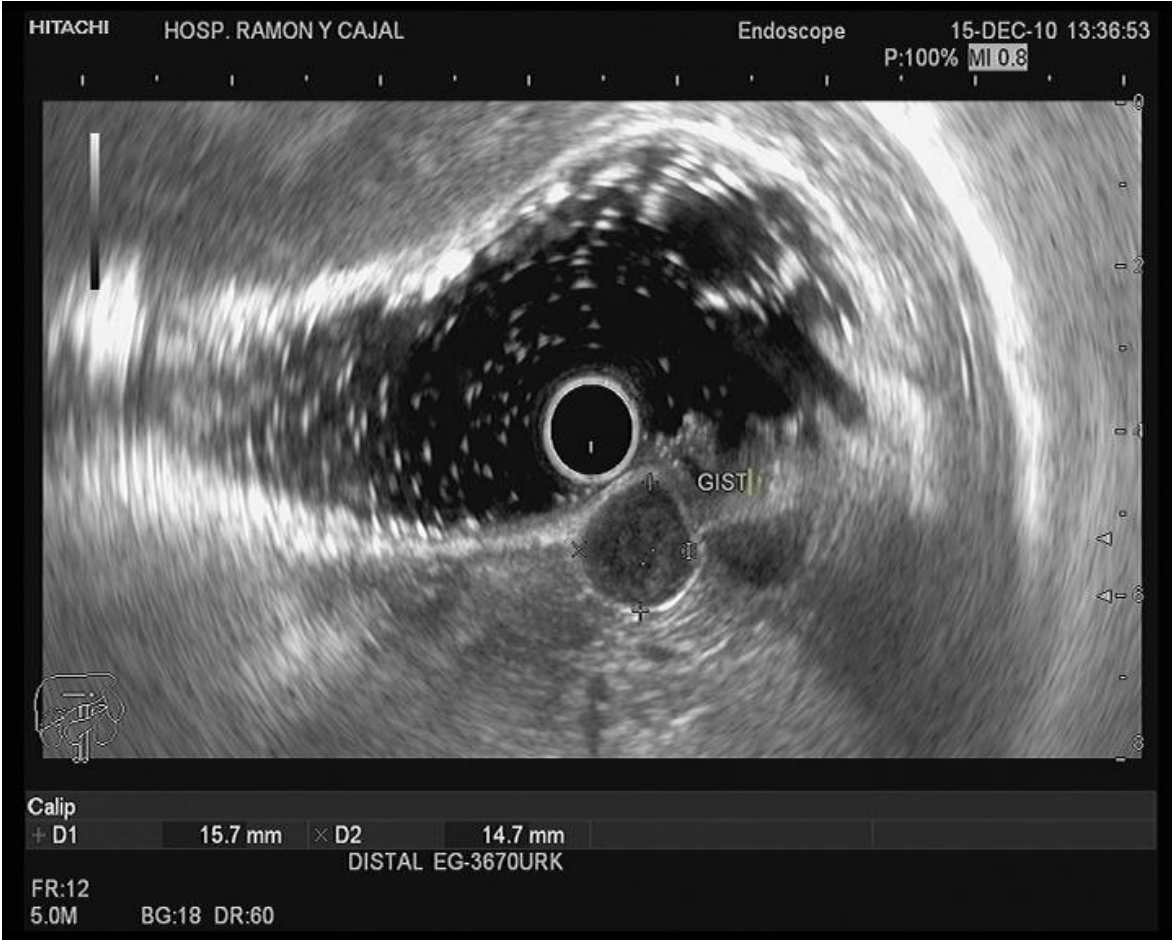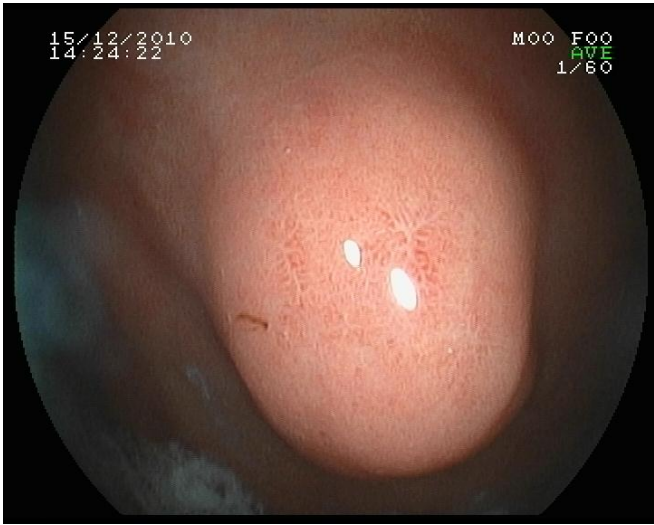
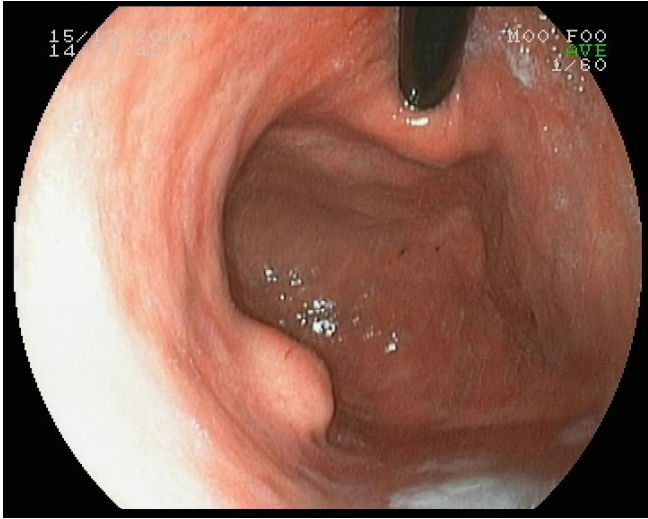
TUMOR DEL ESTROMA GASTROINTESTINAL (GIST)



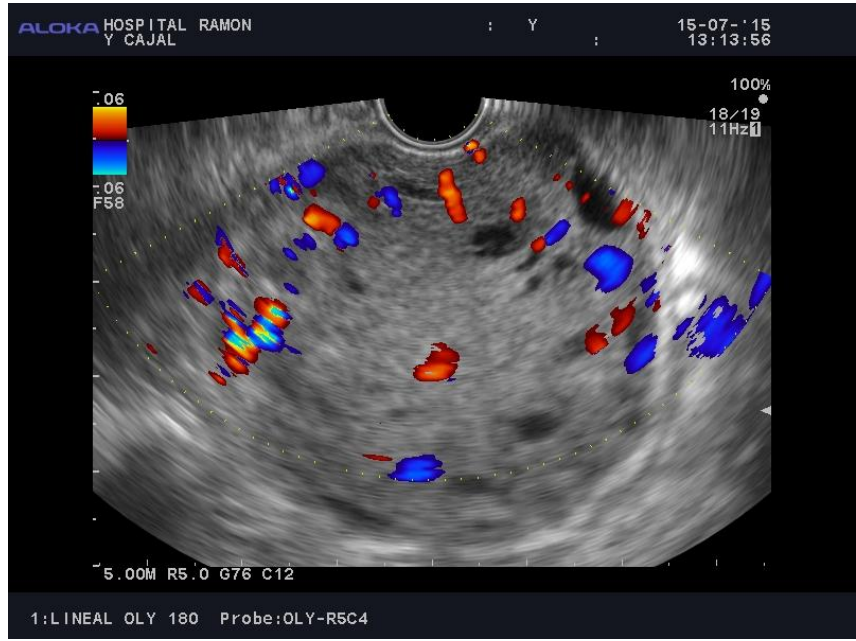
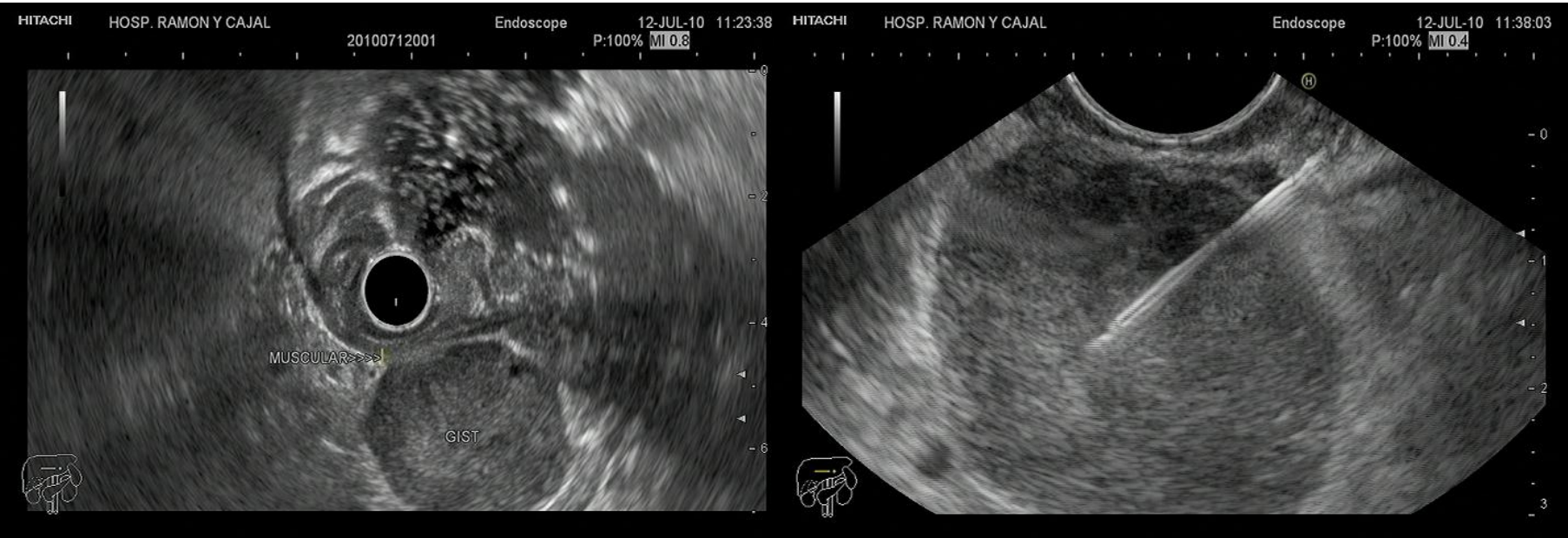TUMOR DEL ESTROMA GASTROINTESTINAL (GIST)



TUMOR DEL ESTROMA GASTROINTESTINAL (GIST)



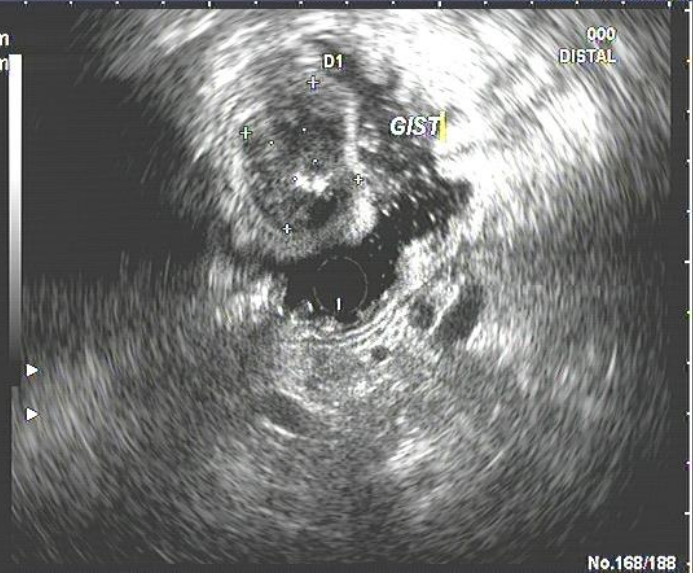TUMOR DEL ESTROMA GASTROINTESTINAL (GIST)



GIST (DATOS ENDOSONOGRÁFICOS MALIGNIDAD)

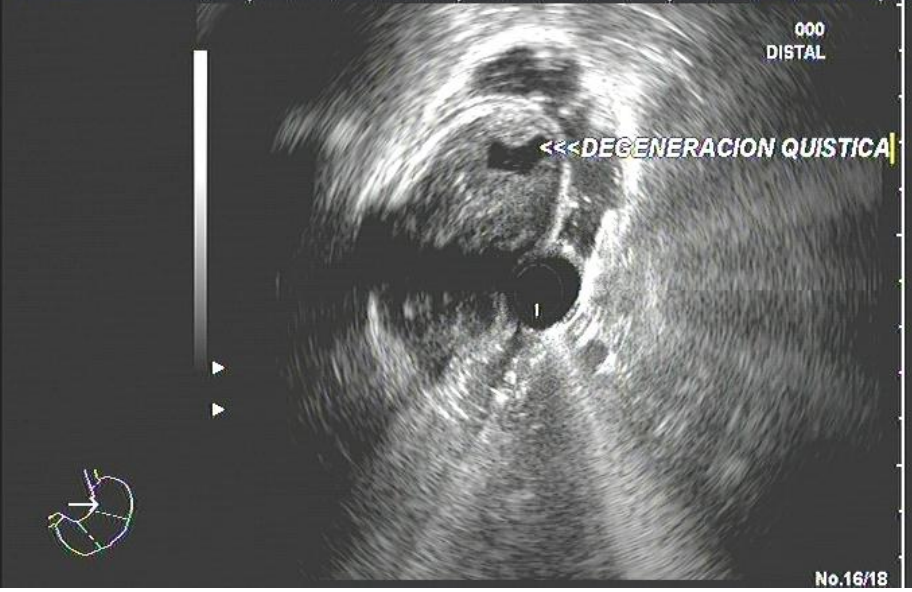
HITACHI FR:12 P:H MI 09/06/10 08:28:57

Calip
D1: 29.7 mm
D2: 26.2 mm



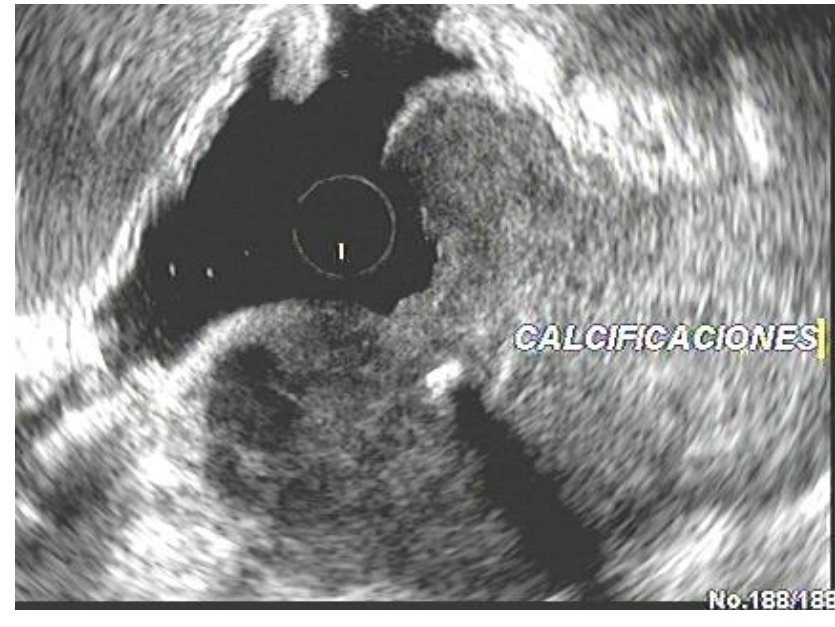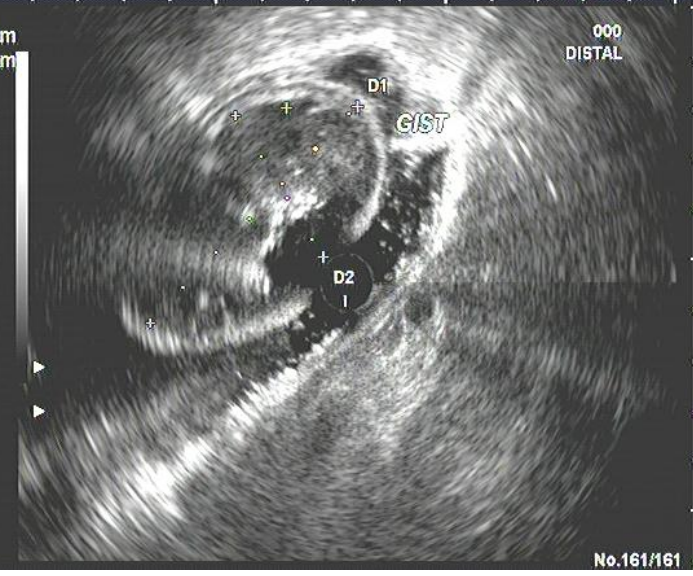
FR:10 09/06/10 08:30:57

000 DISTAL

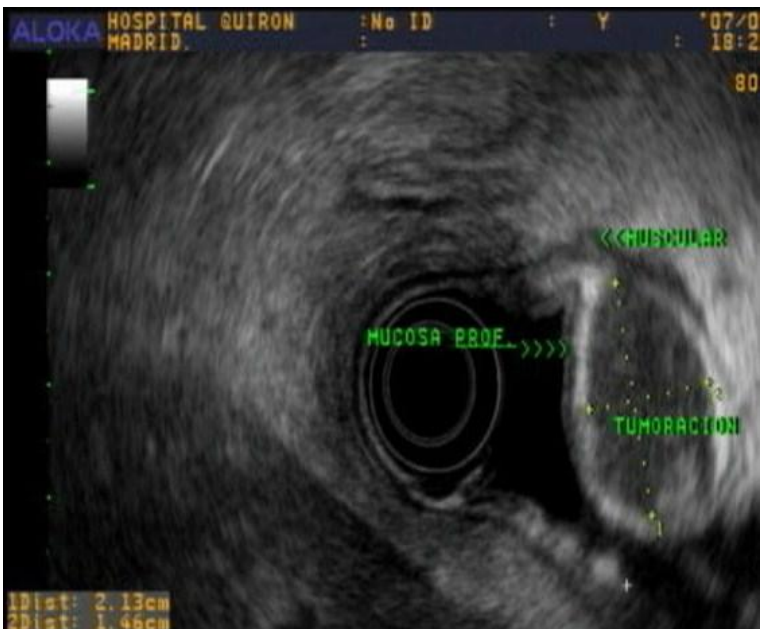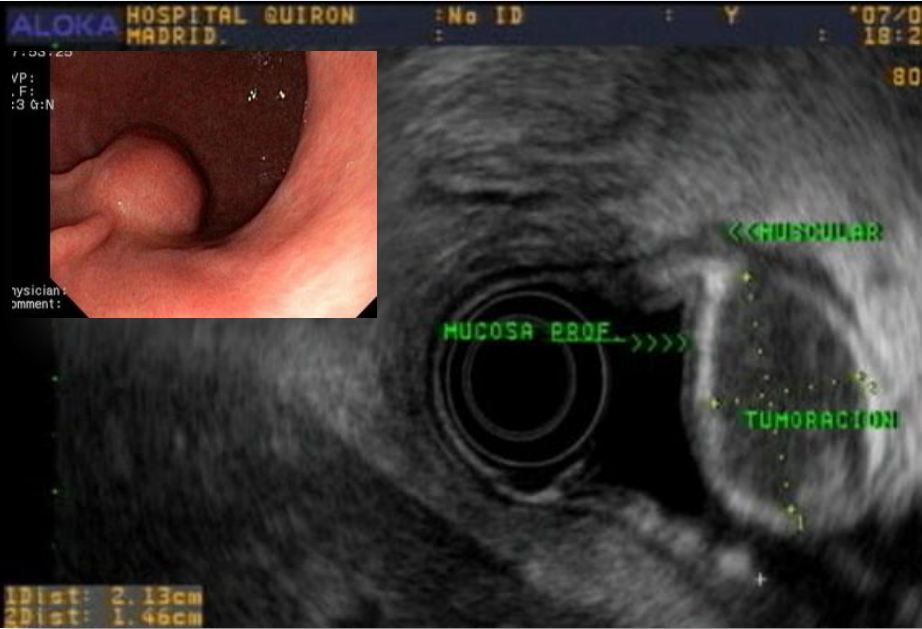
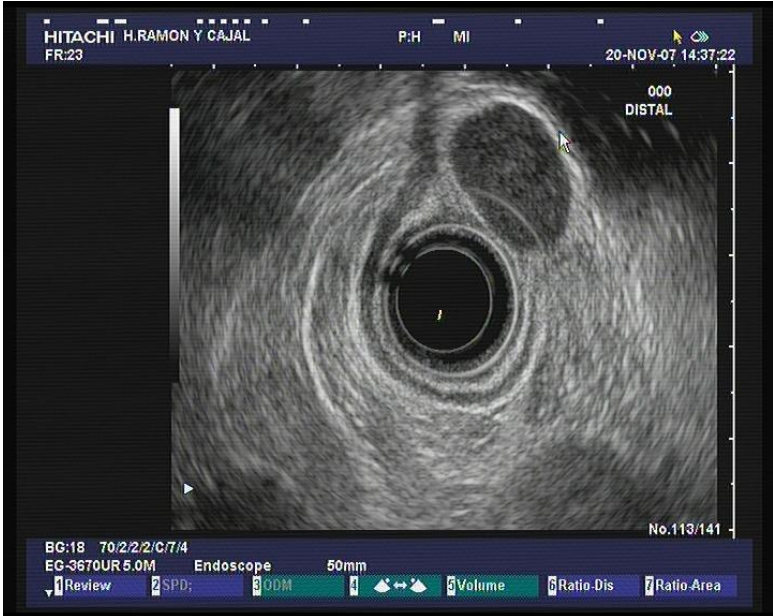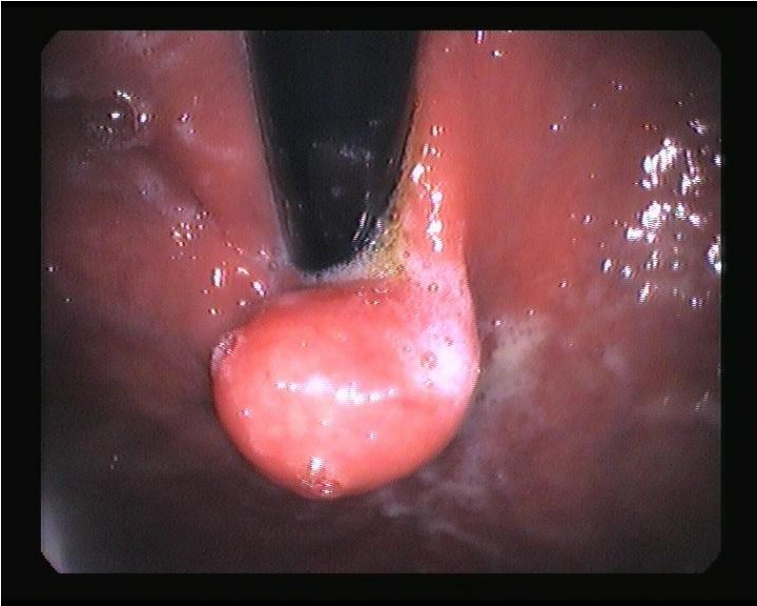


HITACHI FR:12 P:H MI 09/06/10 08:30:05

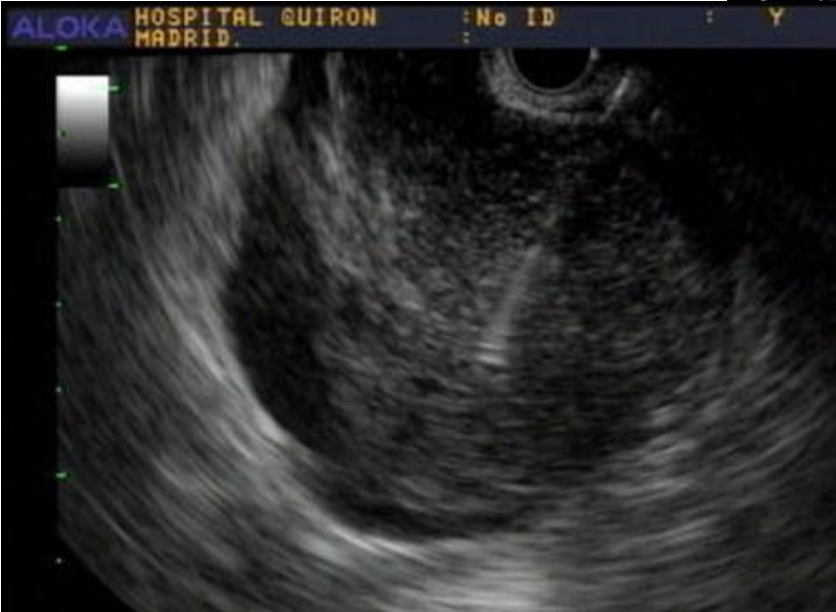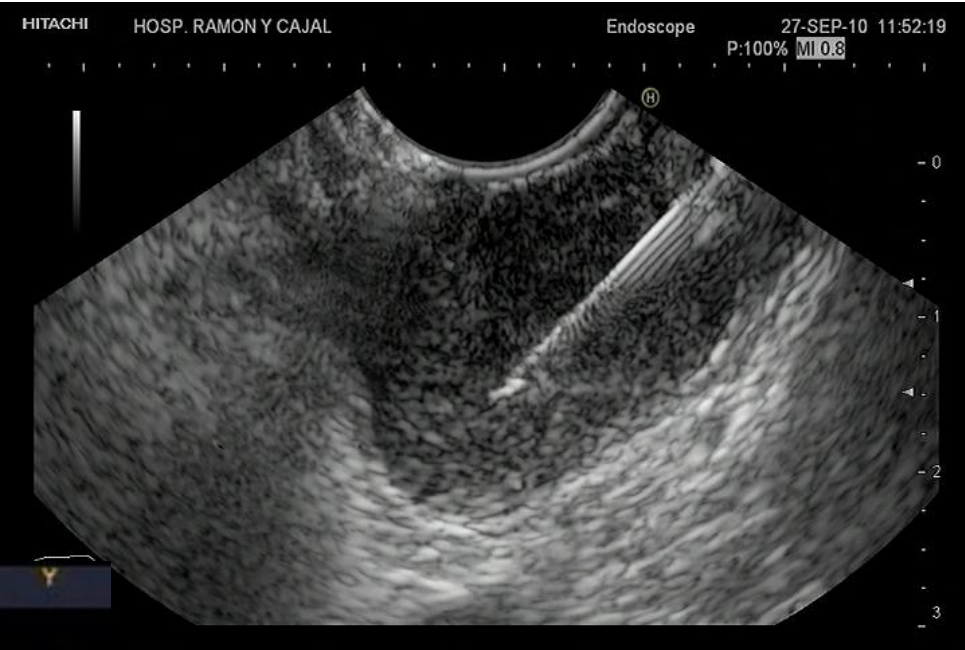
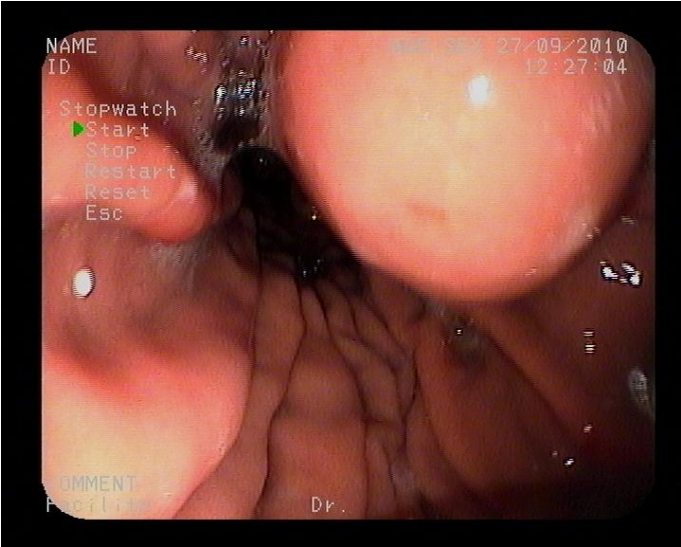
Calip
D1: 62.3 mm
D2: 33.9 mm



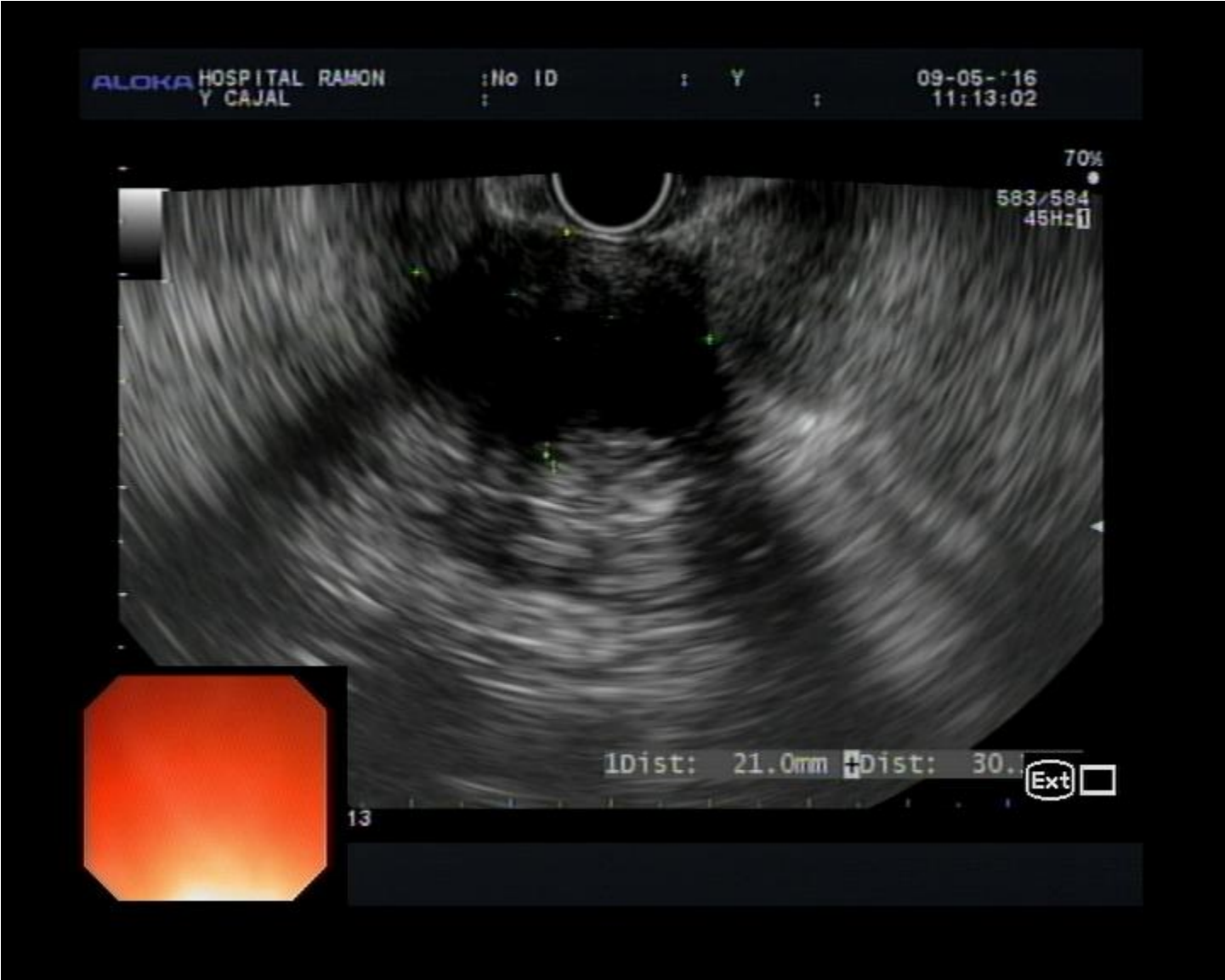
TUMOR DEL ESTROMA GASTROINTESTINAL (GIST)



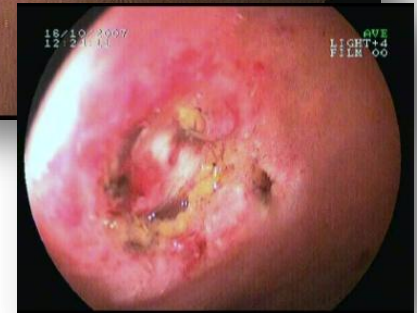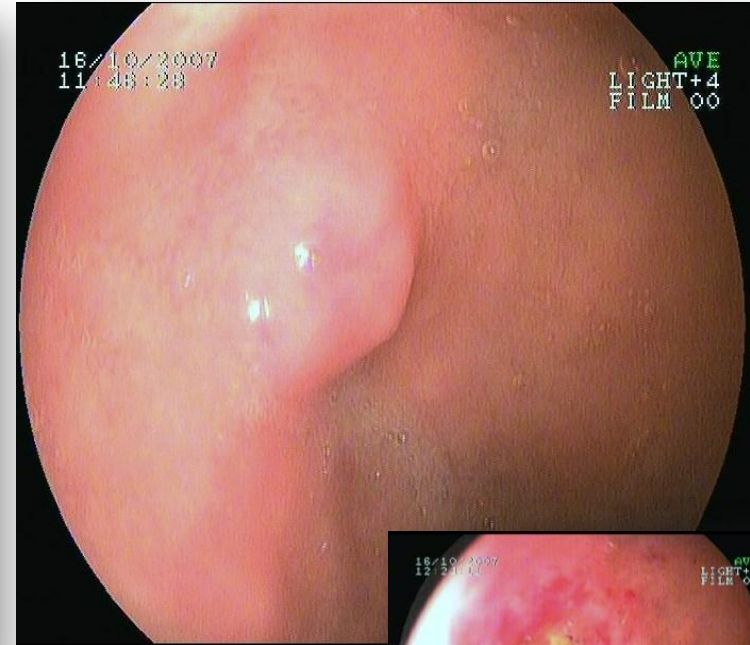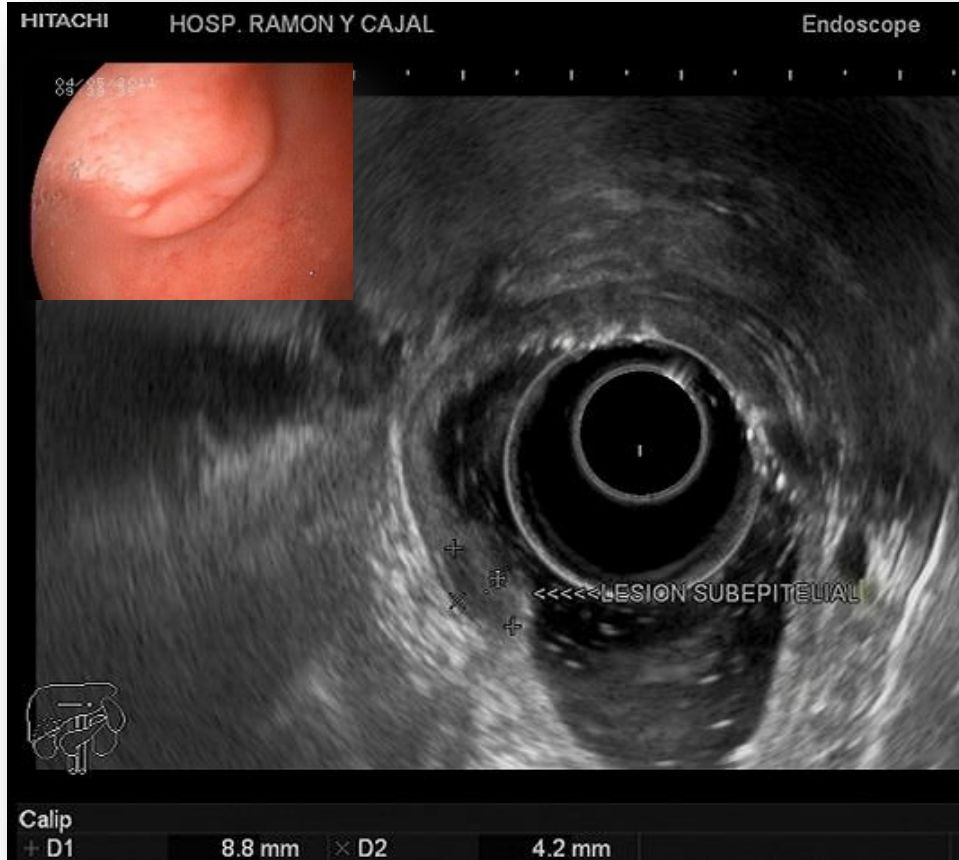
TUMOR DEL ESTROMA GASTROINTESTINAL (PAAF)



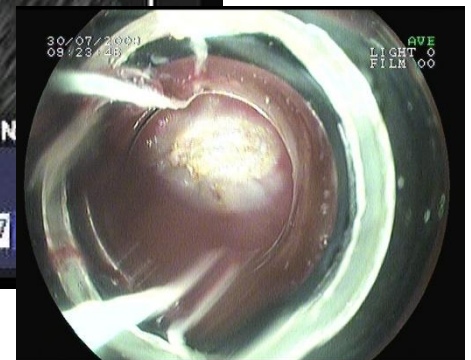
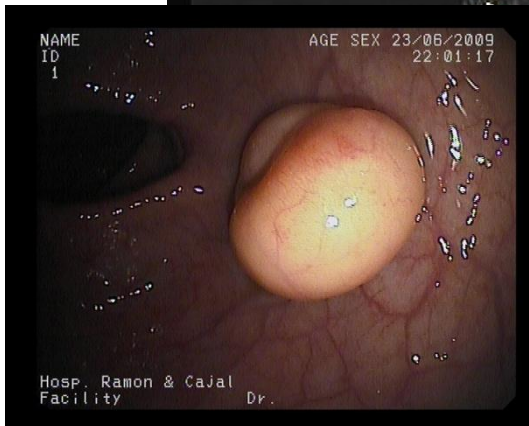
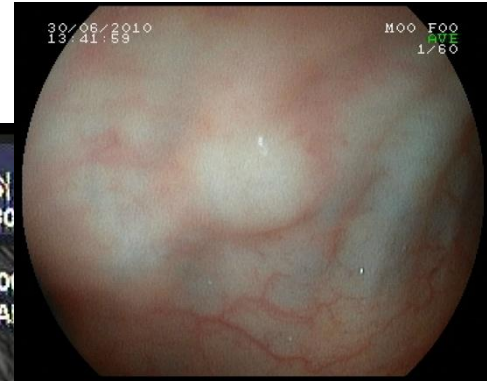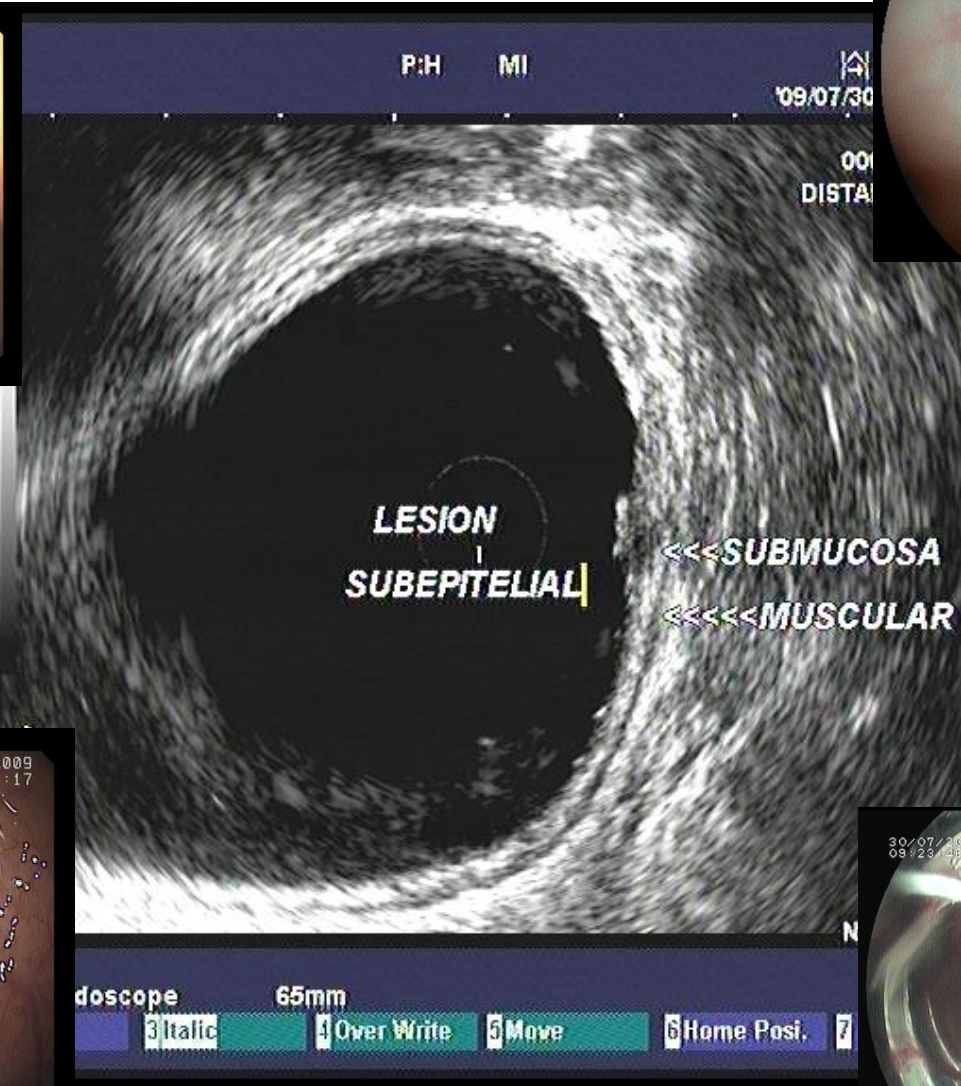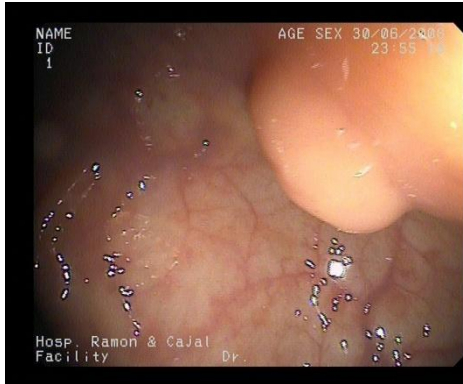
SCHWANNOMA



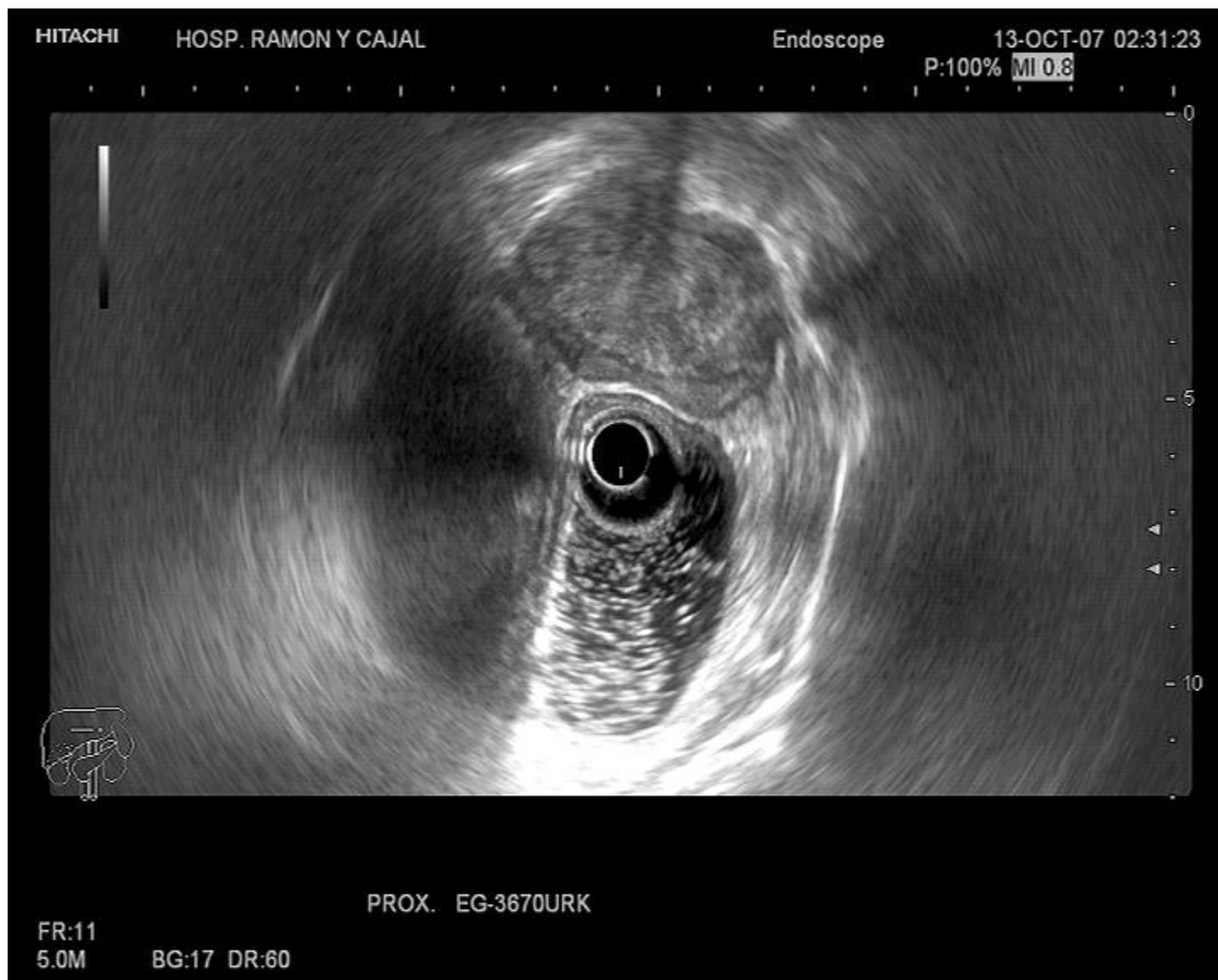GASTRINOMA



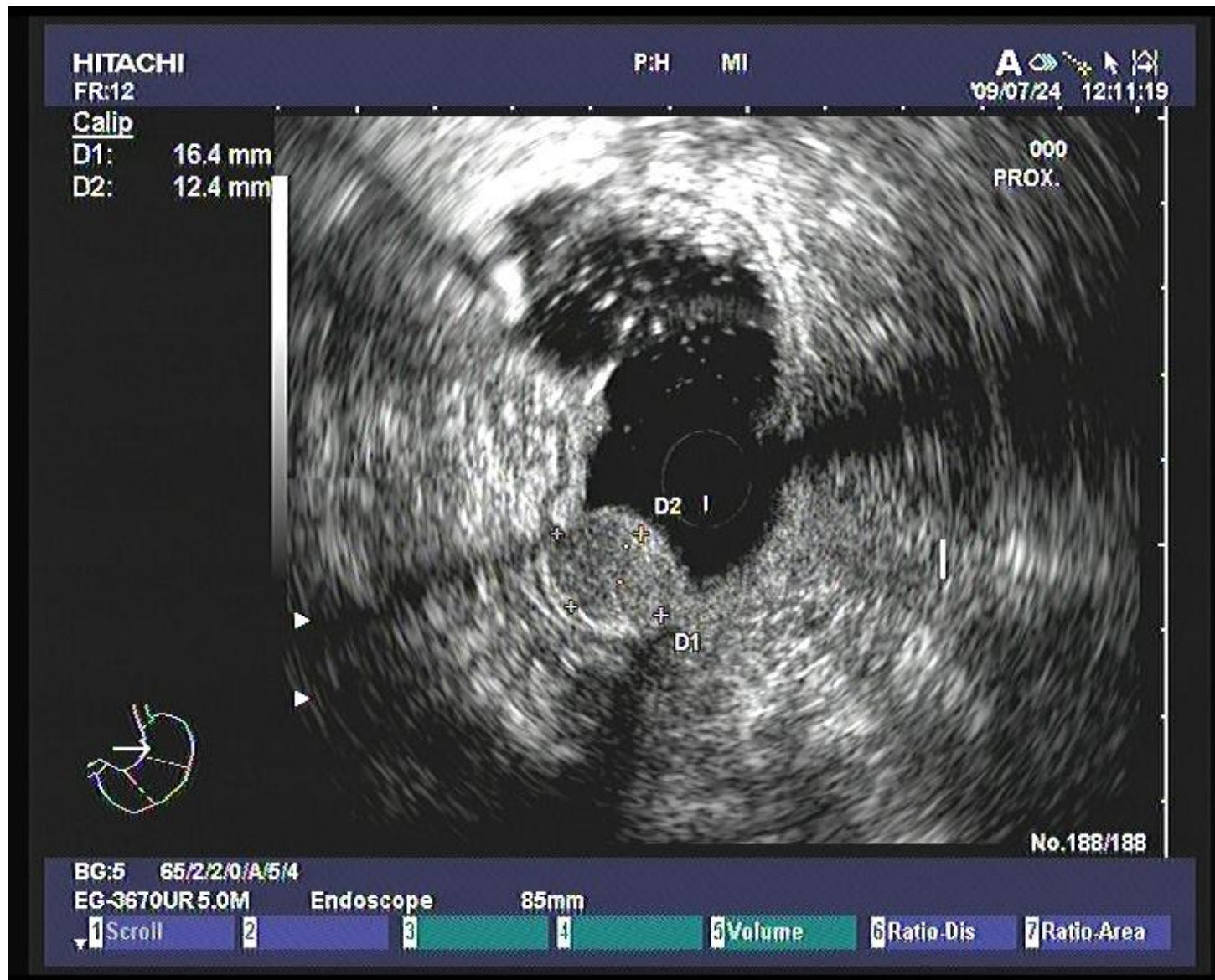TUMOR CARCINOIDE RECTAL



TUMOR ESTROMAL RECTAL



TUMOR ESTROMAL RECTAL



LIPOMA

