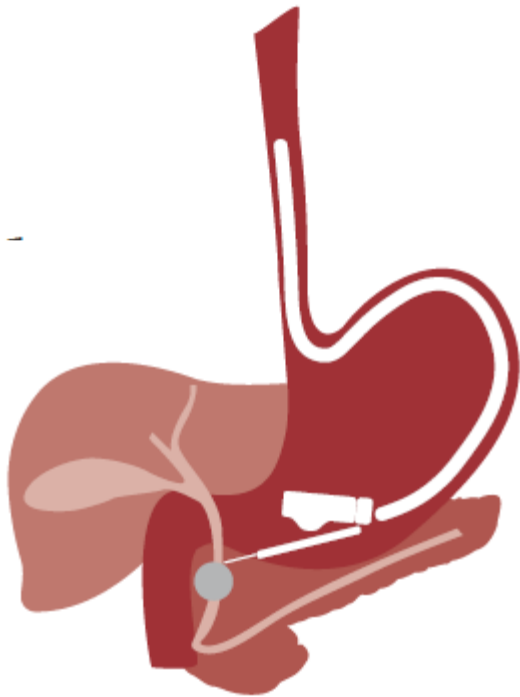
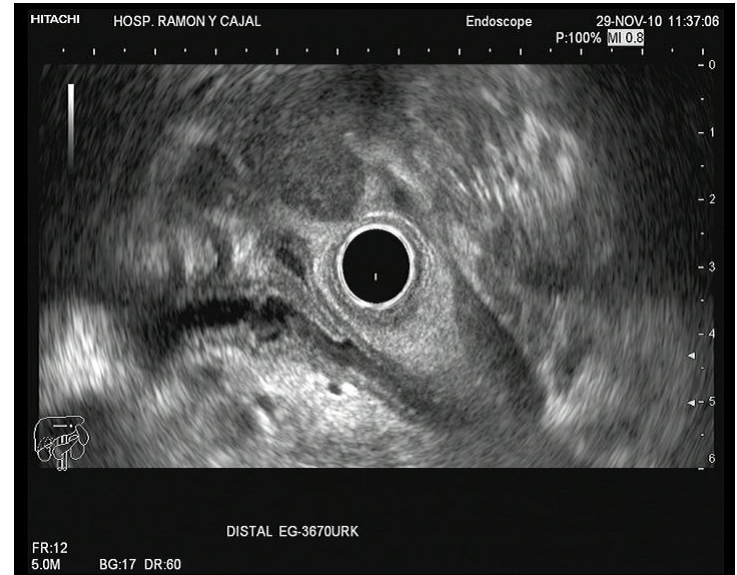
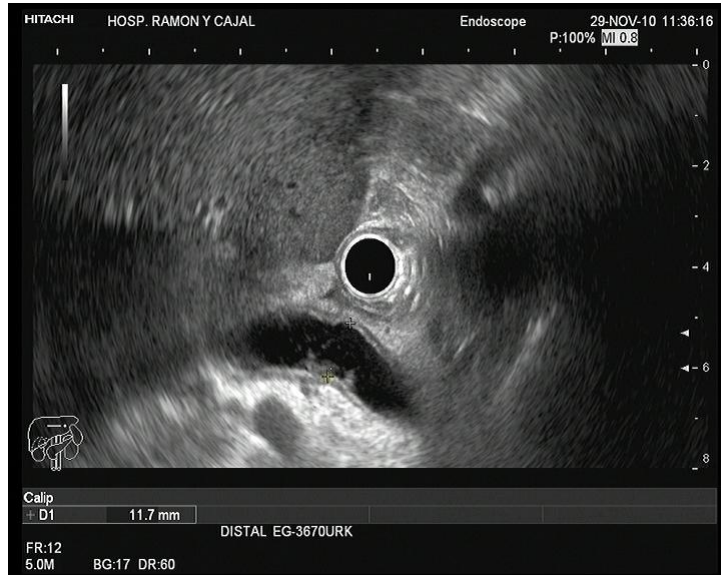
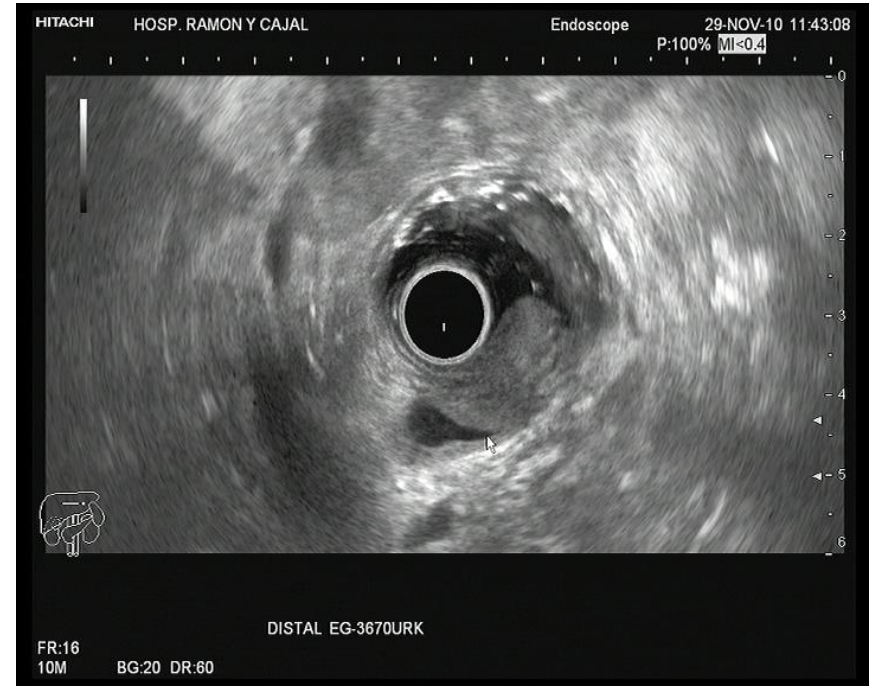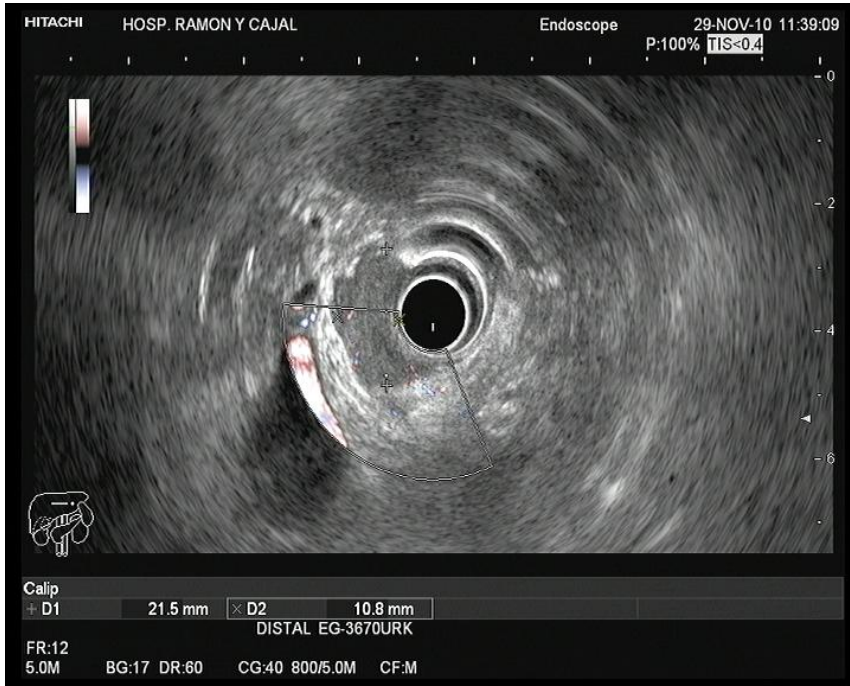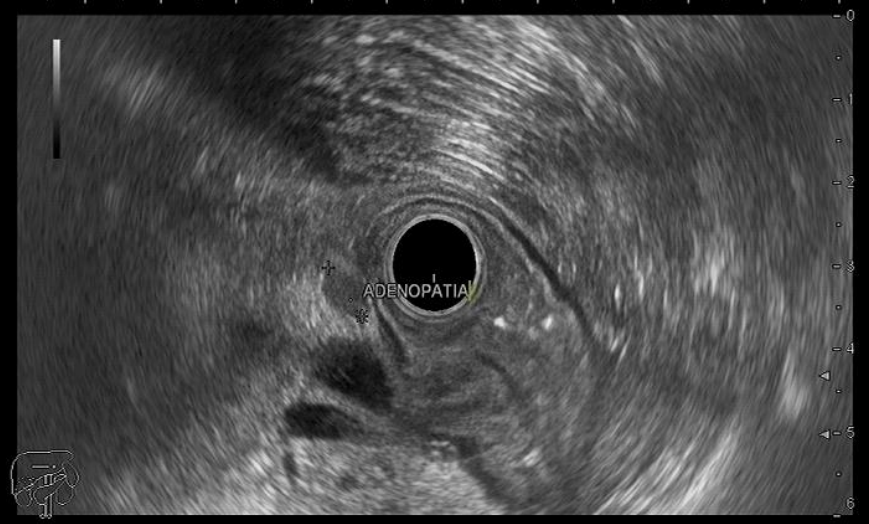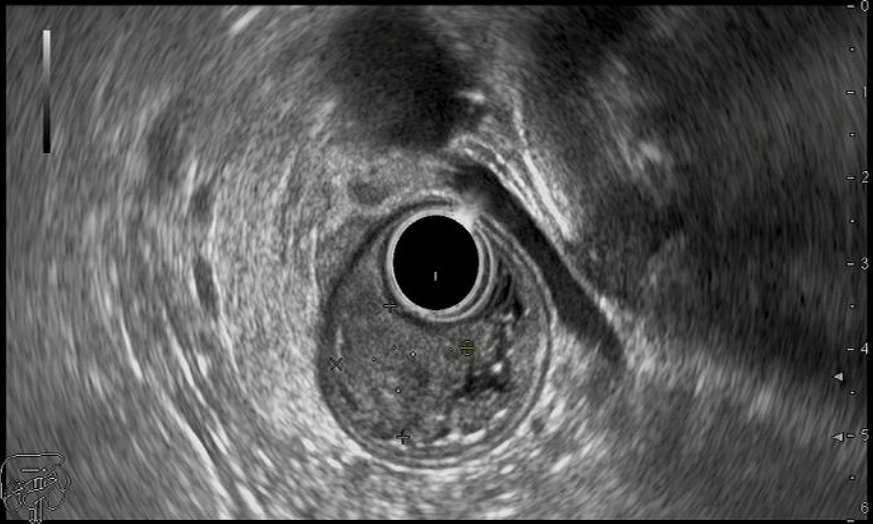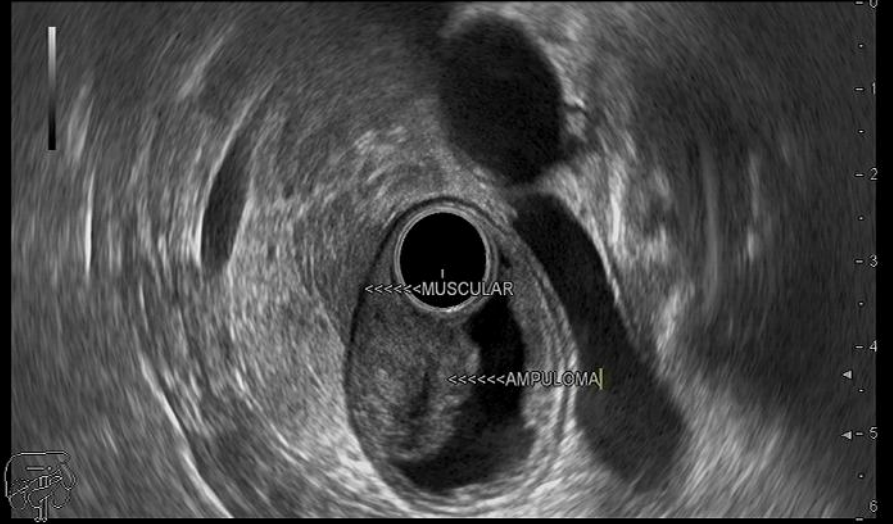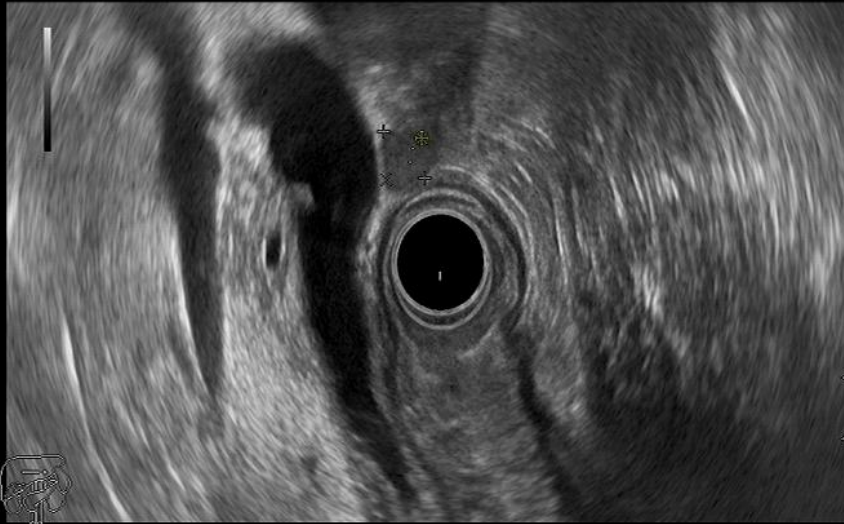**Especialización en
Ultrasonografía
Endoscópica Avanzada**



**GALERÍA IMÁGENES
ECOENDOSCOPIA
AMPULOMA
Y
COLANGIOCARCINOMA**

AMPULOMAS



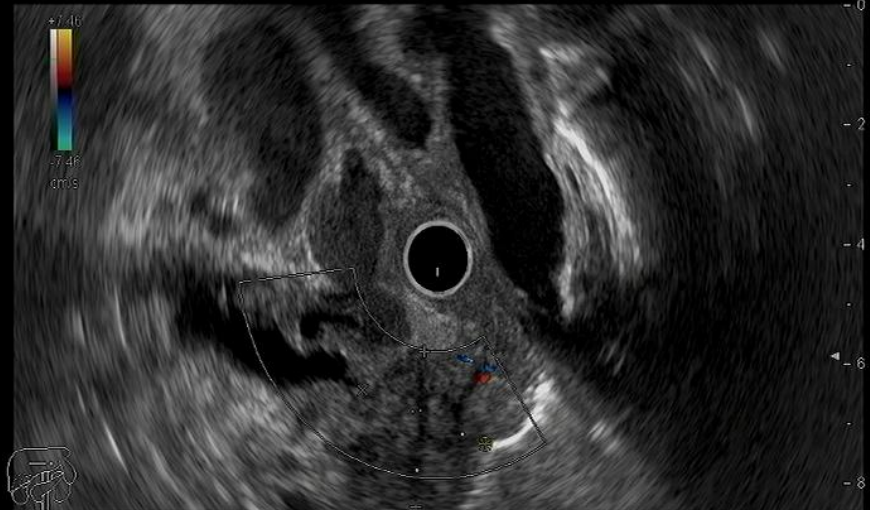
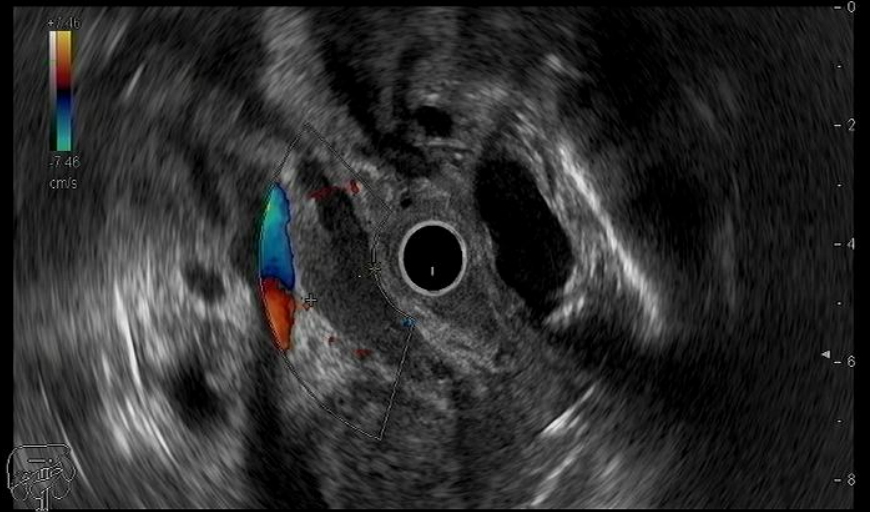
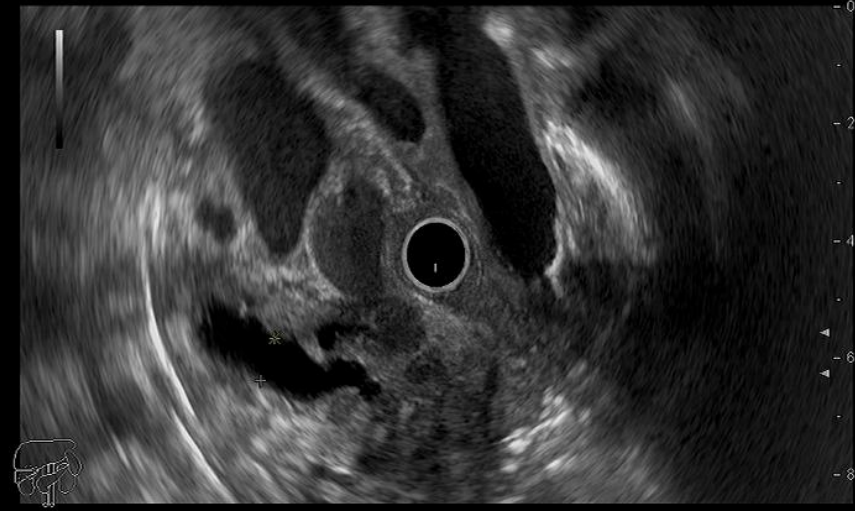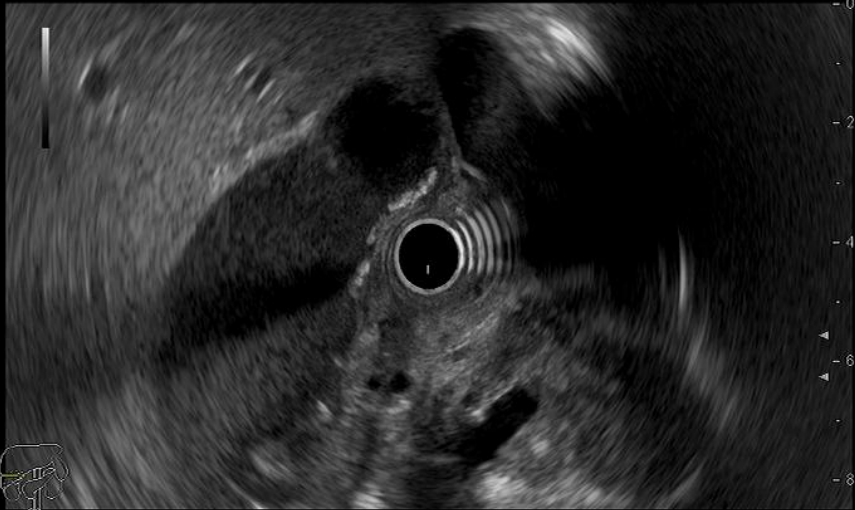


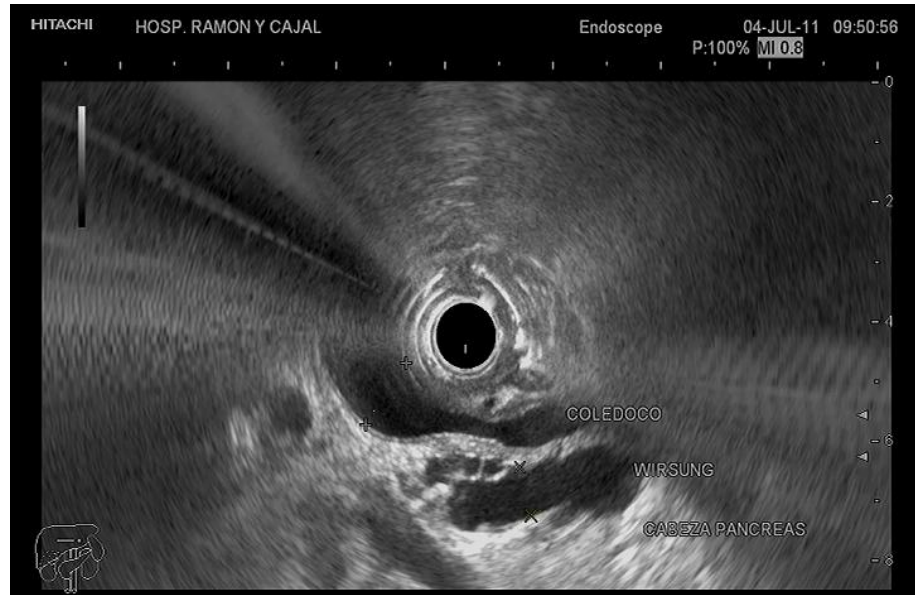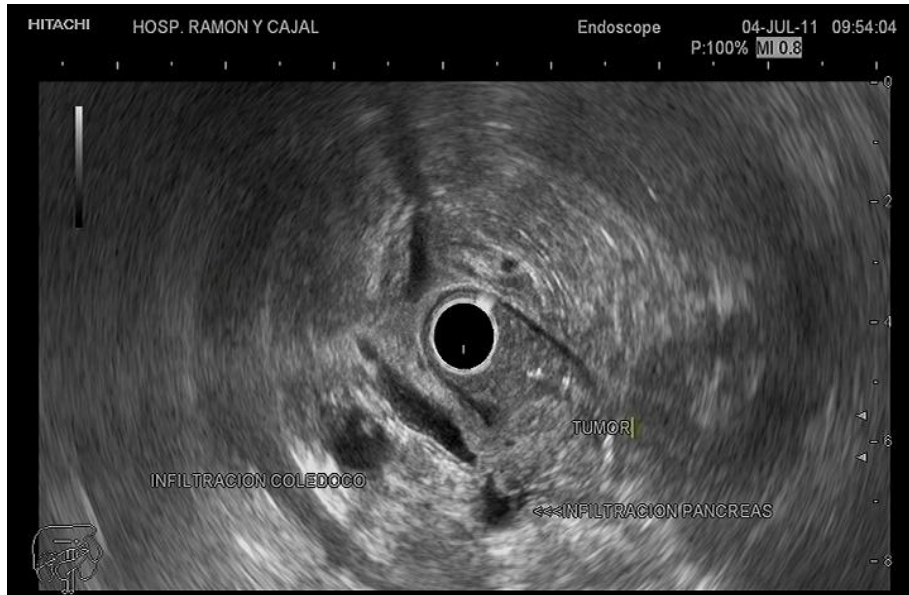Calip
 + D1 15.4 mm × D2 17.0 mm
 DISTAL EG-3670URK

FR:12
 5.0M BG:17 DR:60

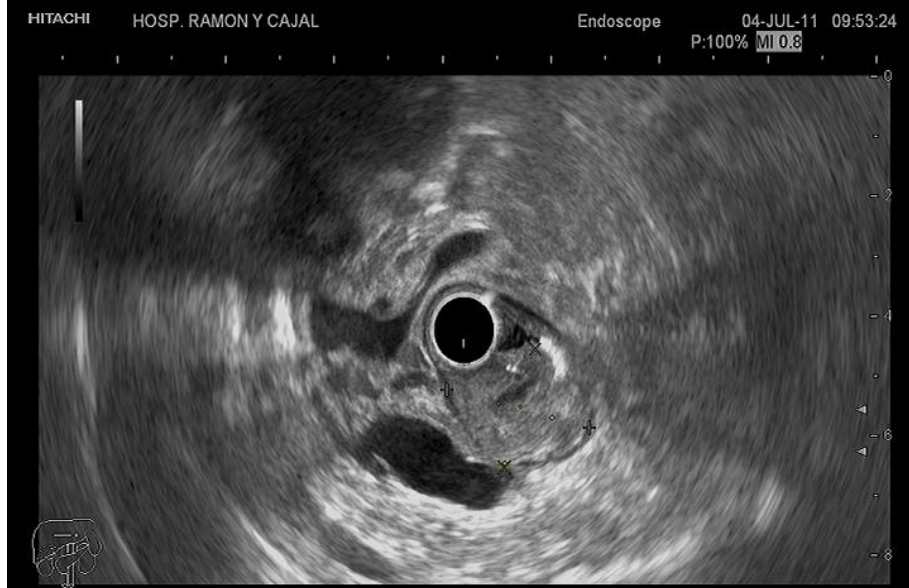Calip
 + D1 7.3 mm
 DISTAL EG-3670URK

FR:16
 9.0M BG:17 DR:60

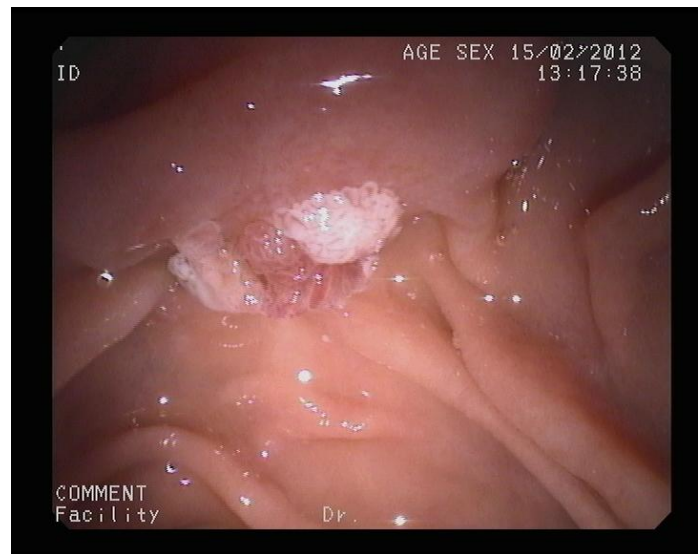


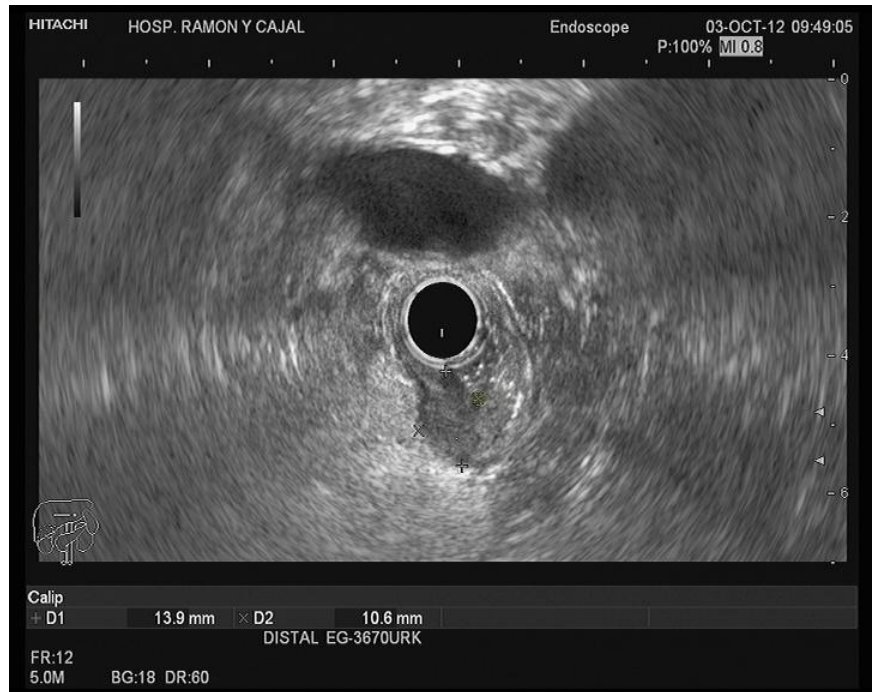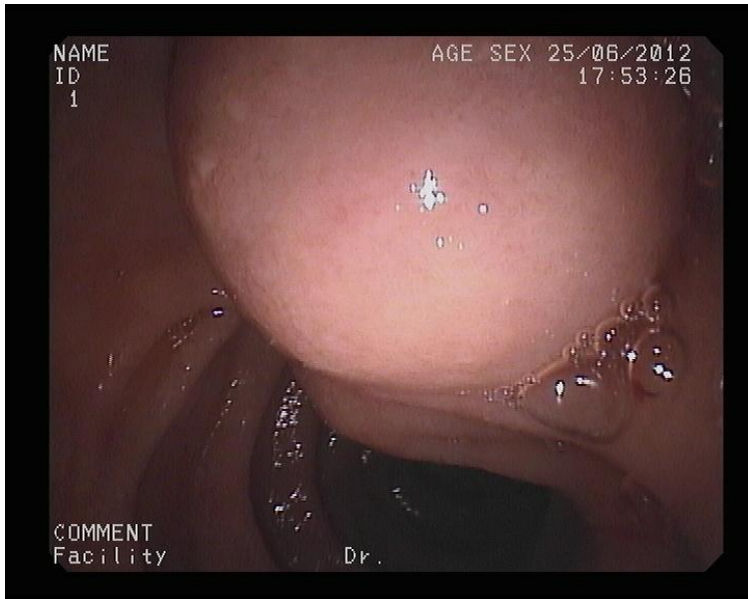
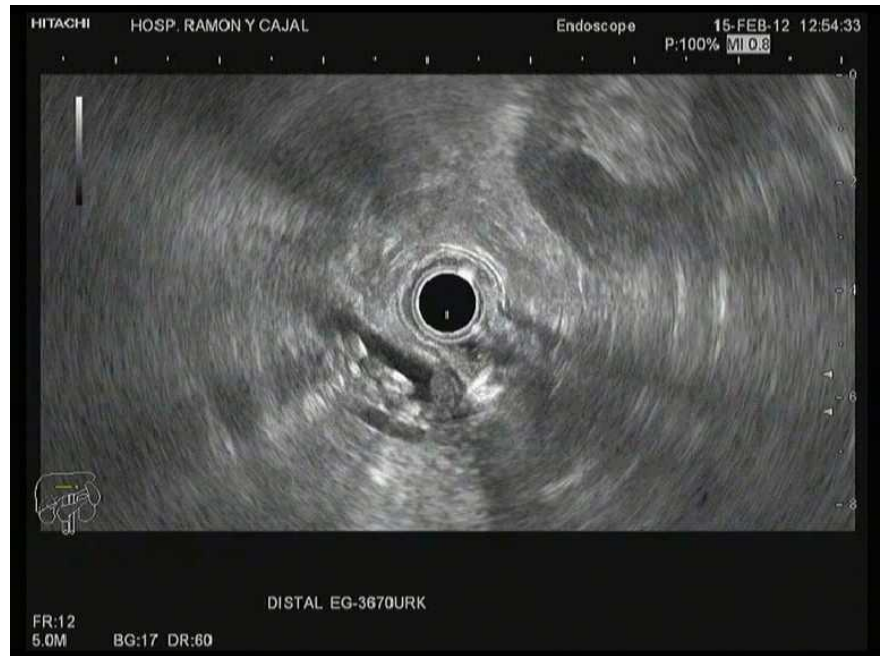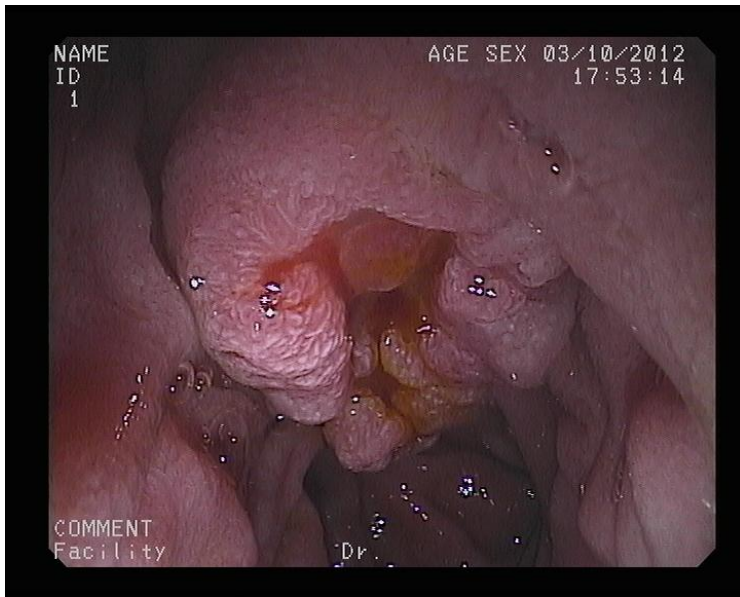


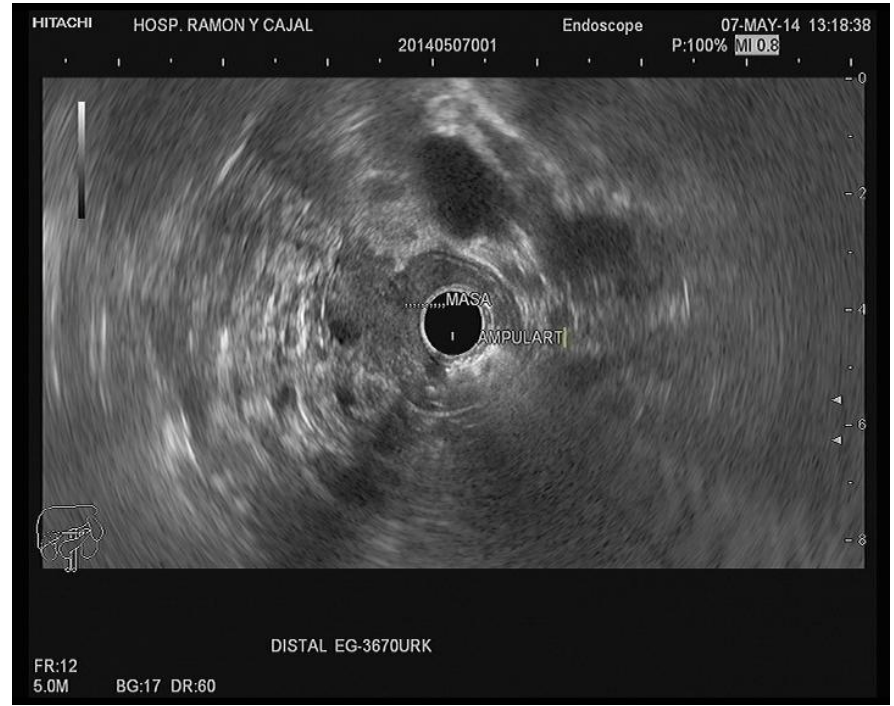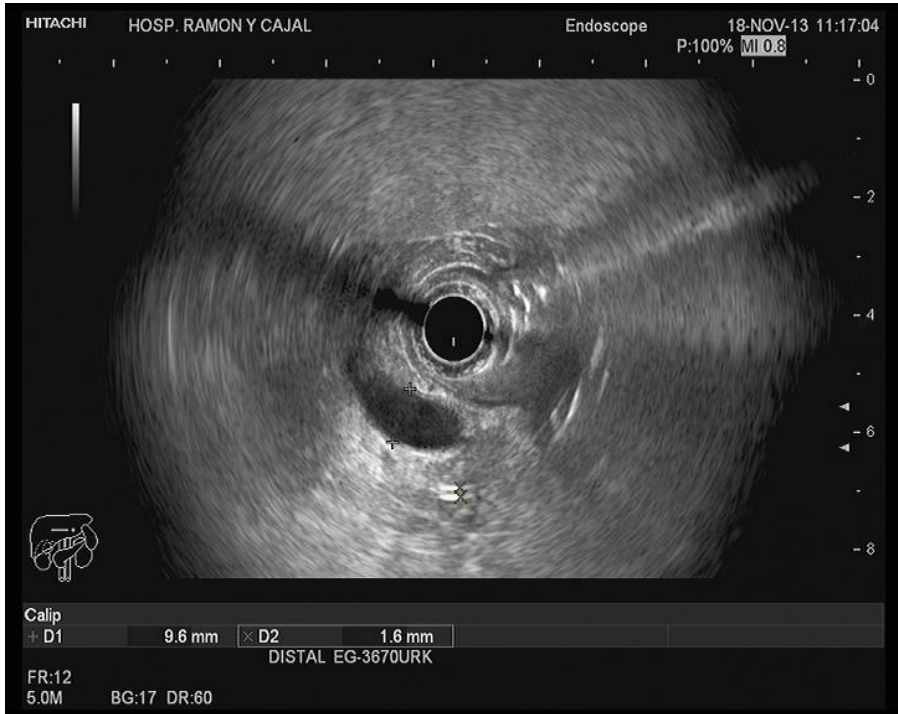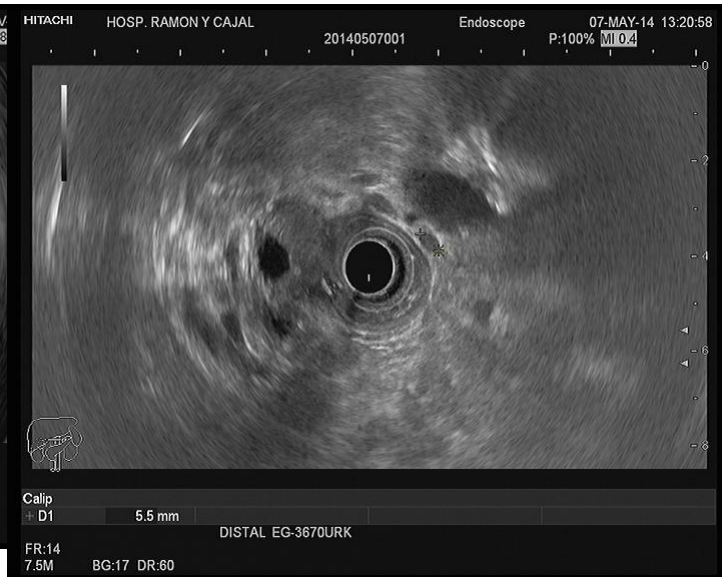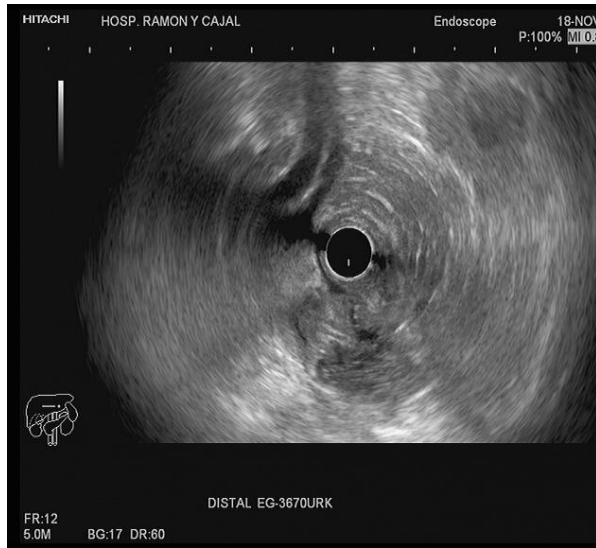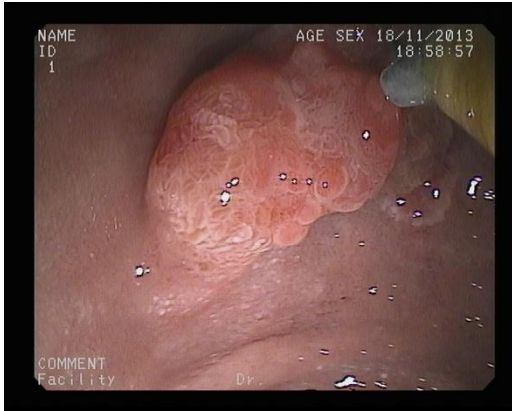Calip
+ D1 12.7 mm × D2 8.3 mm
DISTAL EG-3670URK
FR:12
5.0M BG:17 DR:60

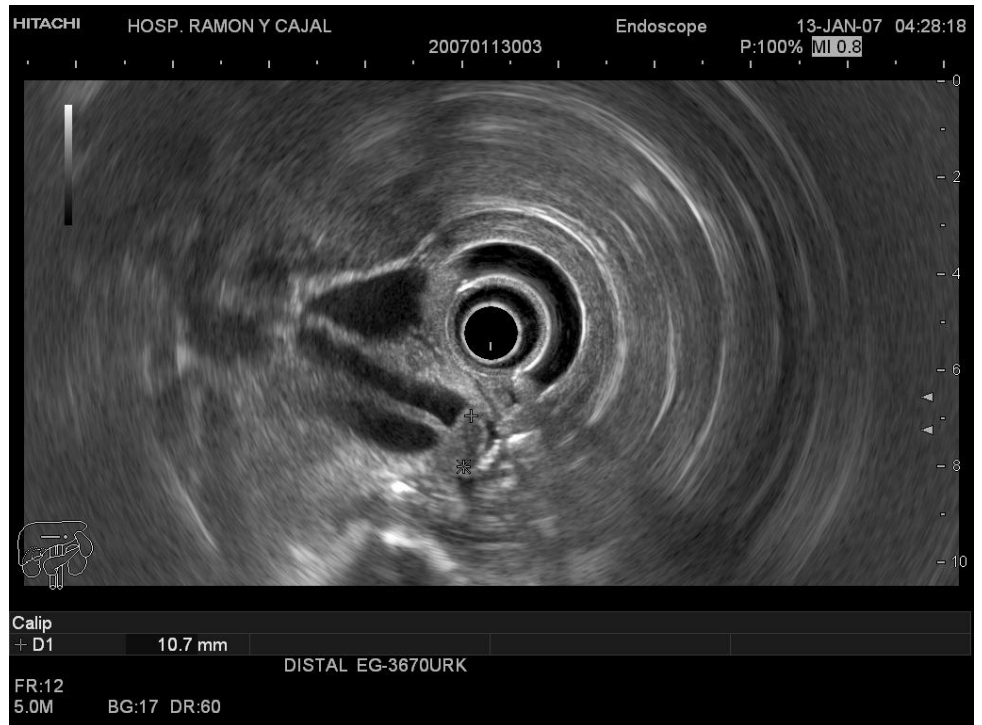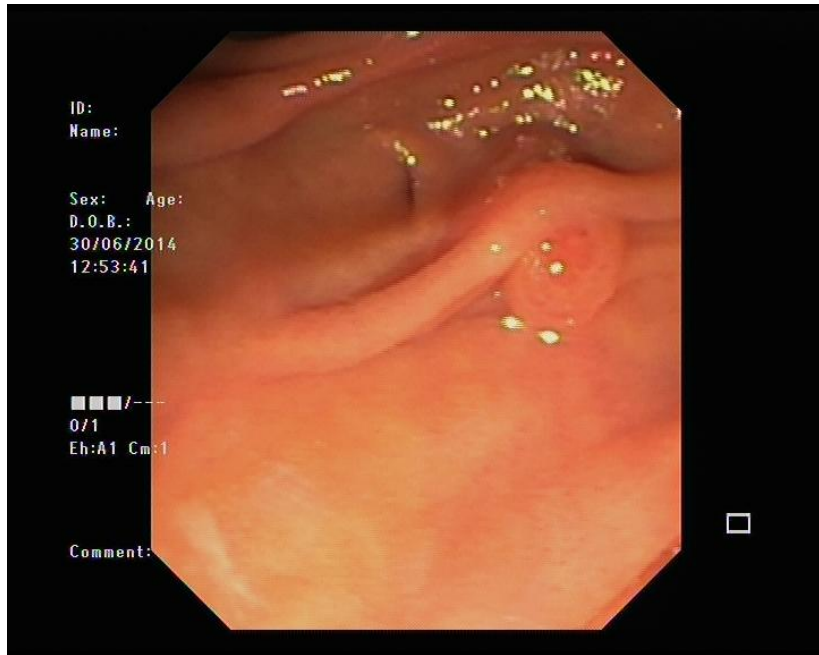


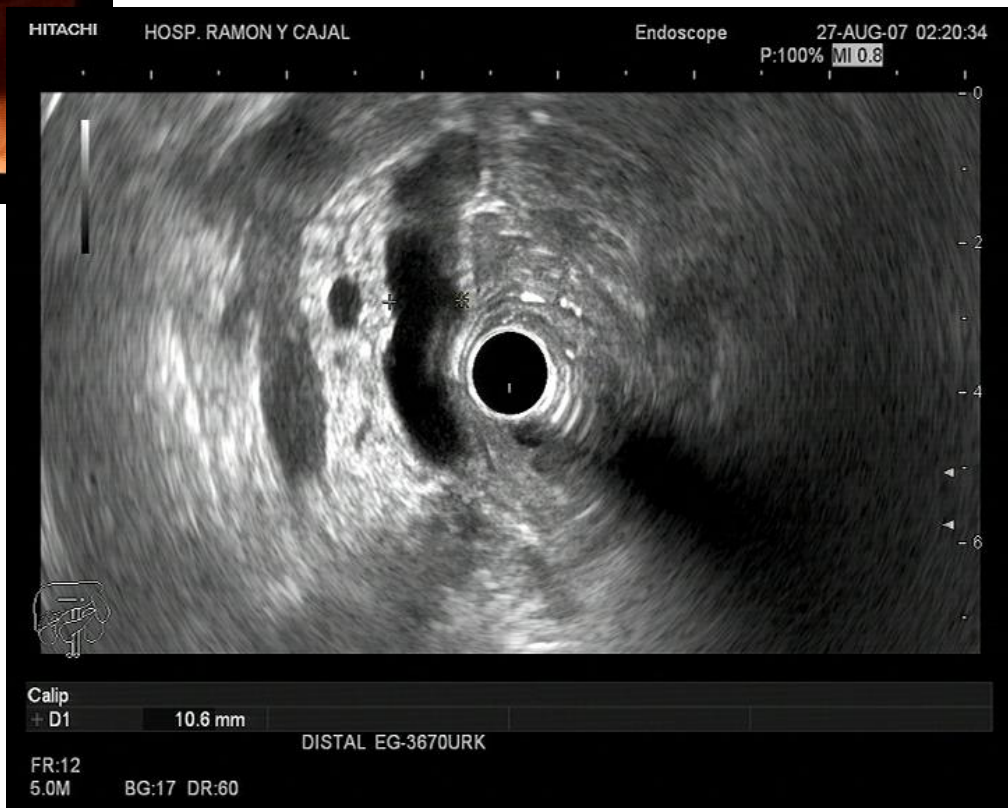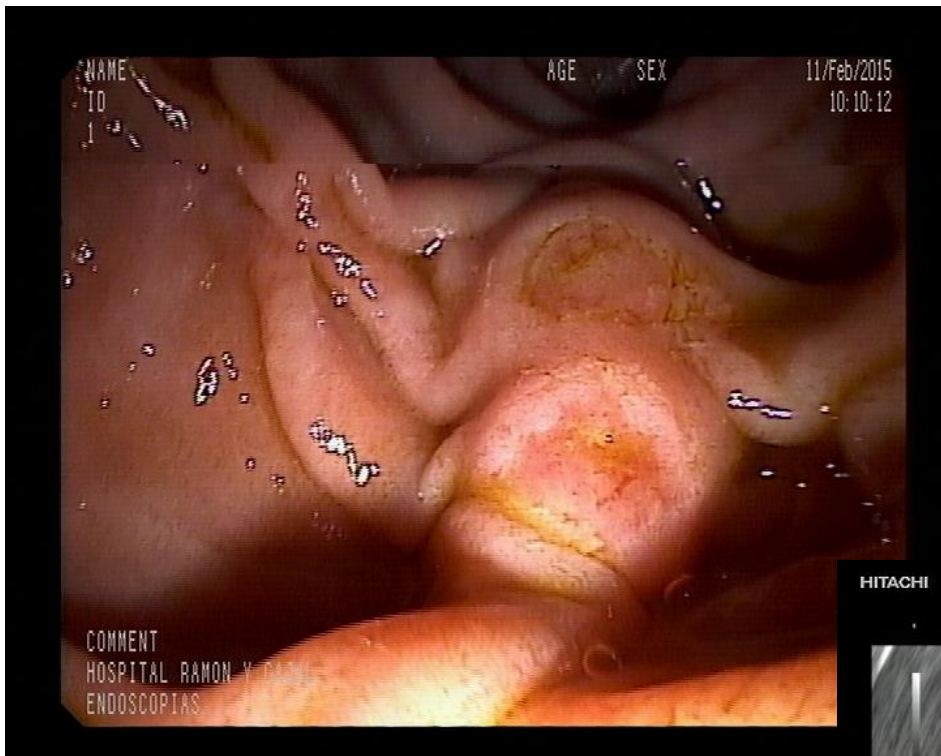
Calip
+ D1 27.0 mm × D2 20.6 mm
DISTAL EG-3670URK
FR:12
5.0M BG:17 DR:60



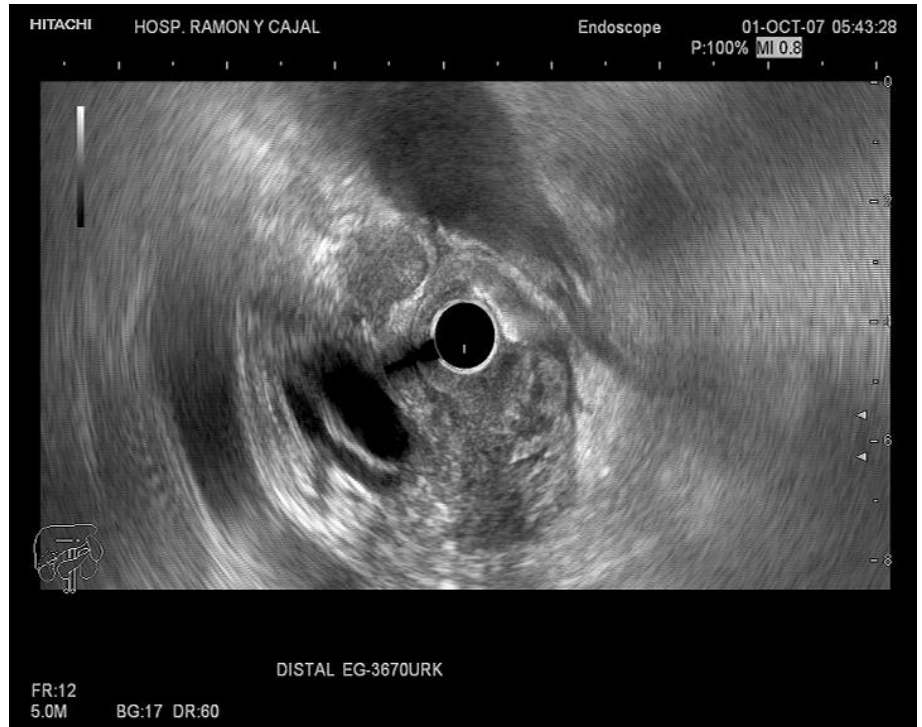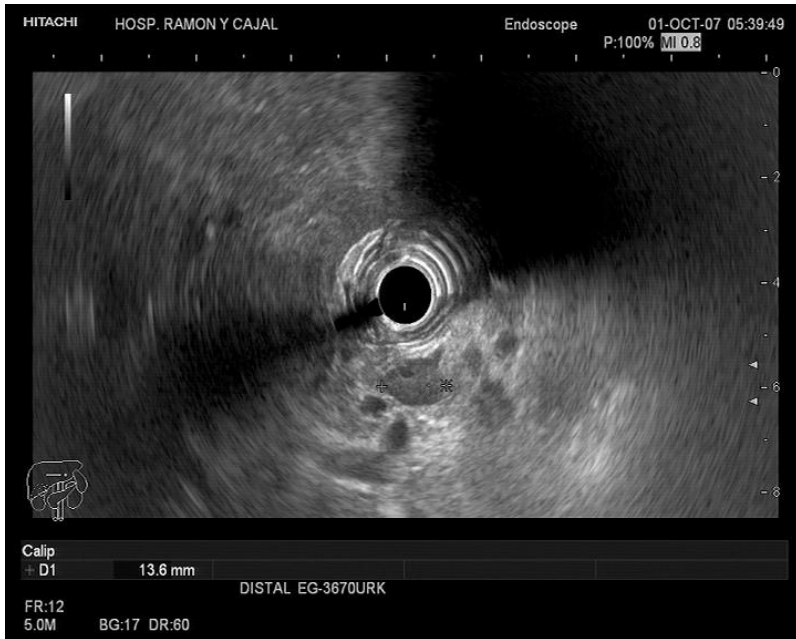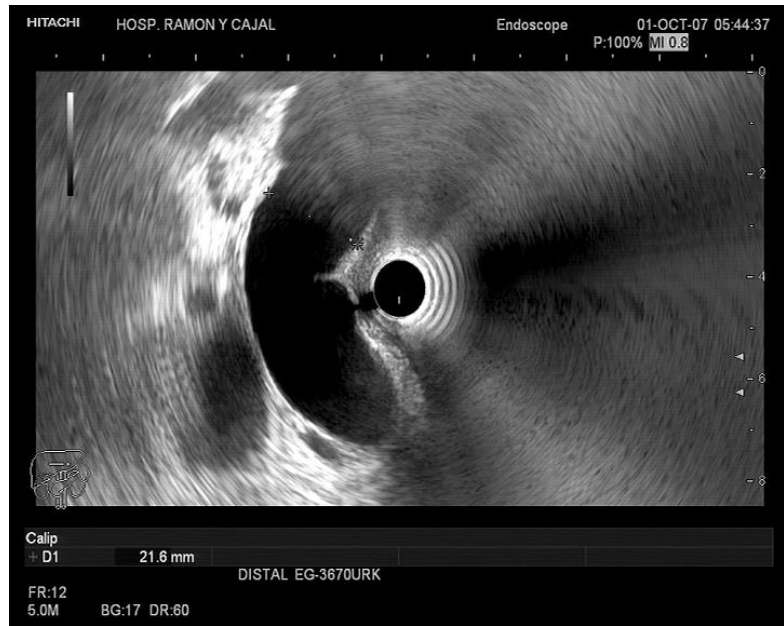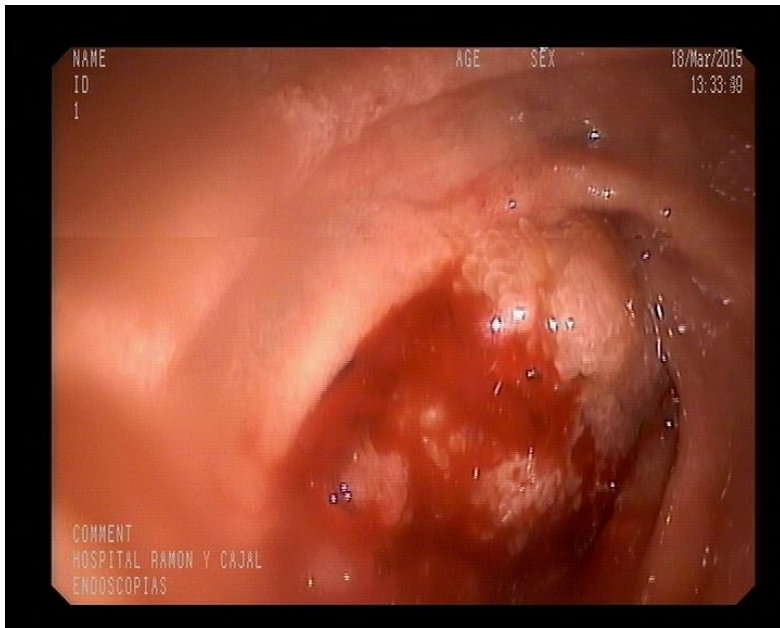


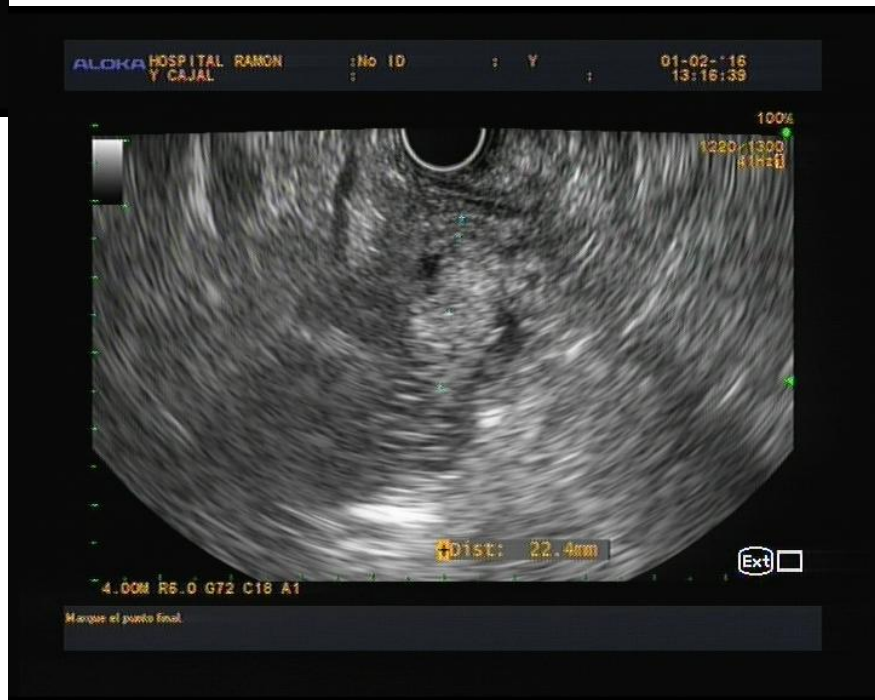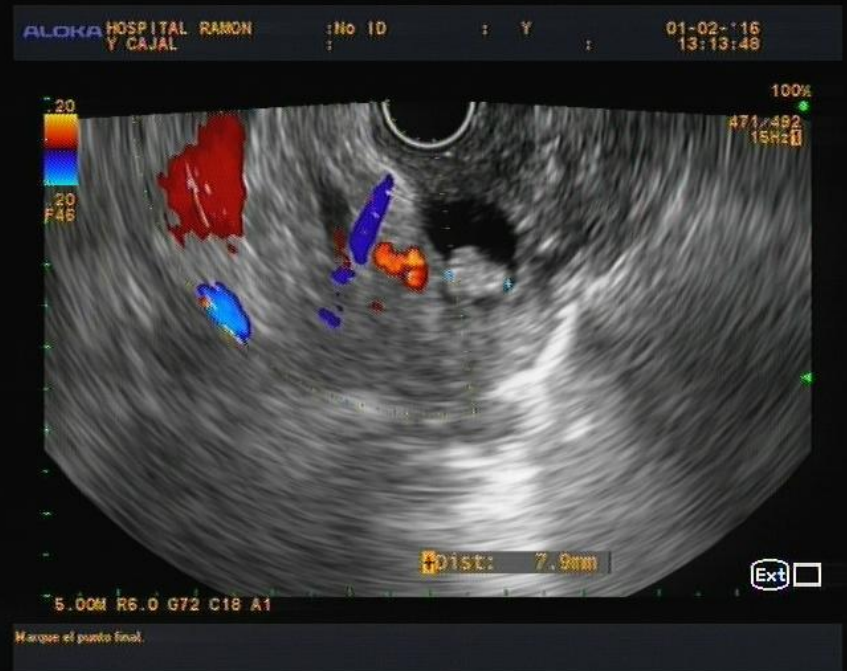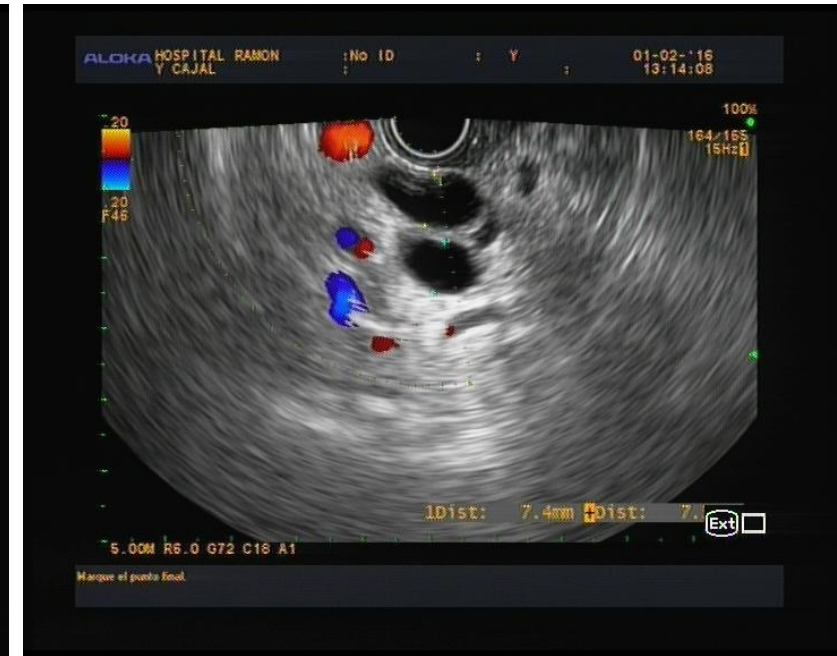


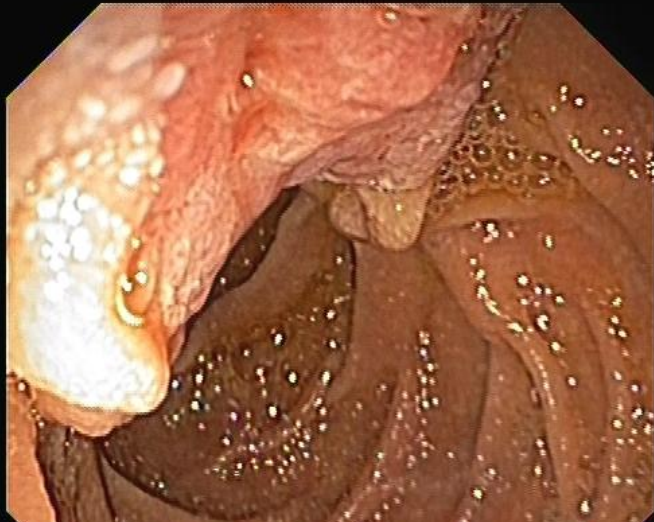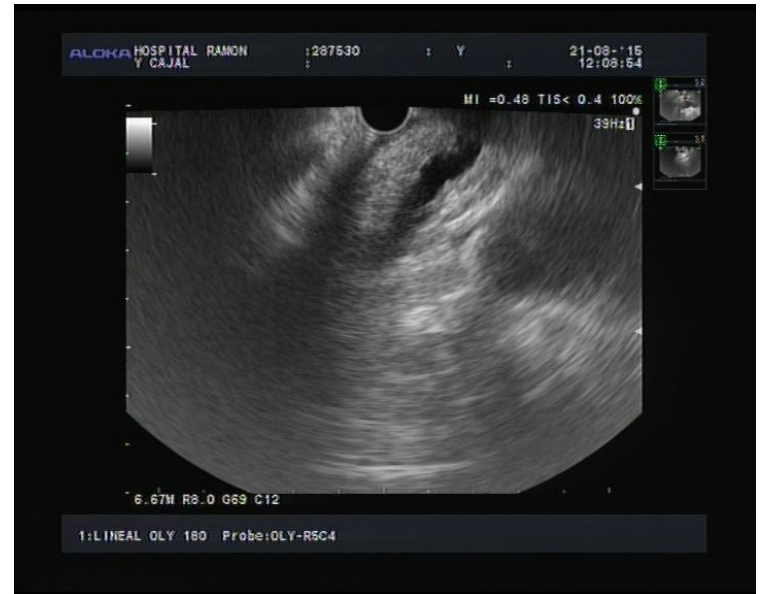


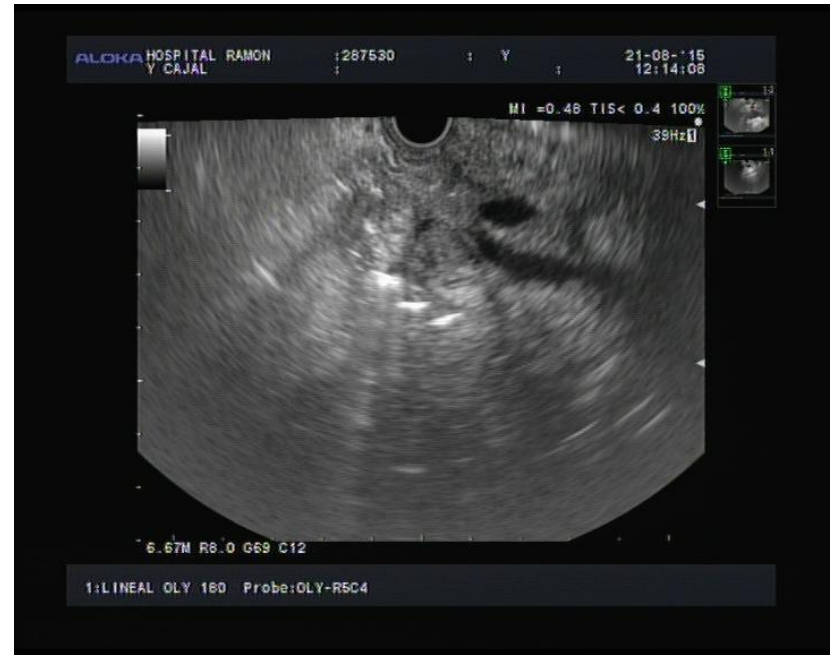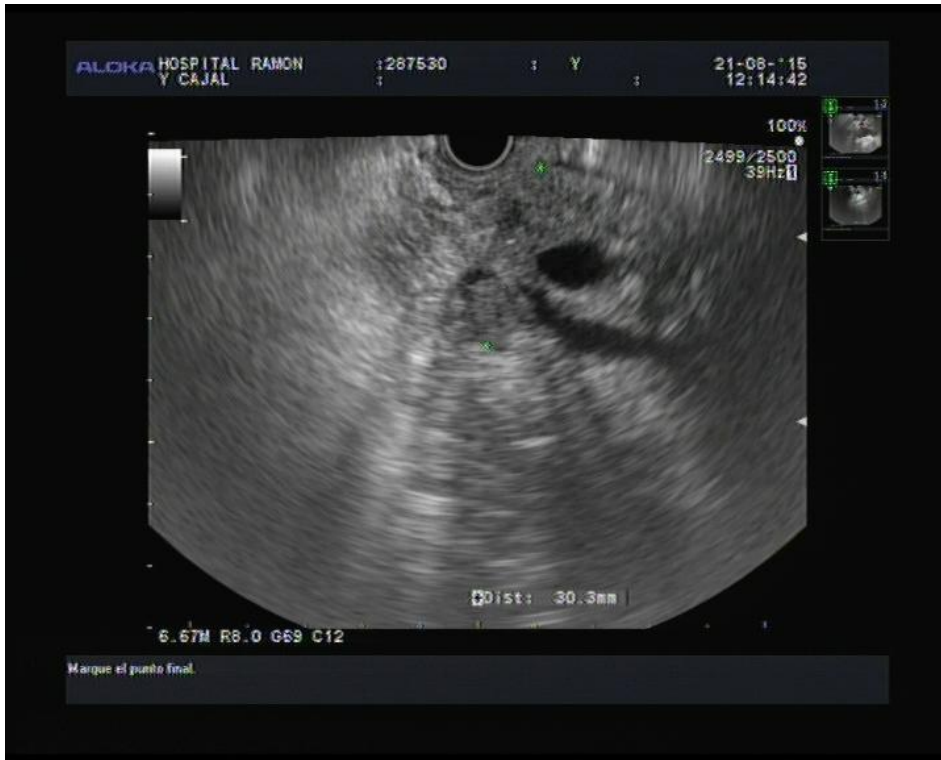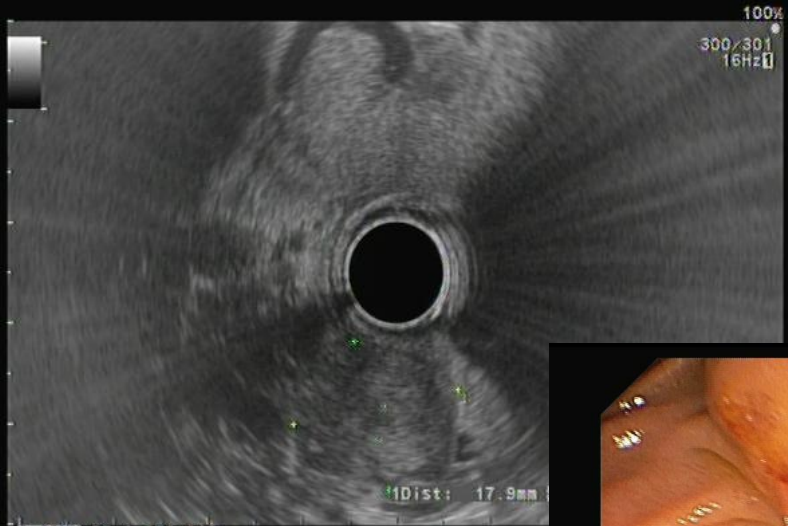


Calip
+ D1 10.6 mm DISTAL EG-3670URK
FR:12
5.0M BG:17 DR:60

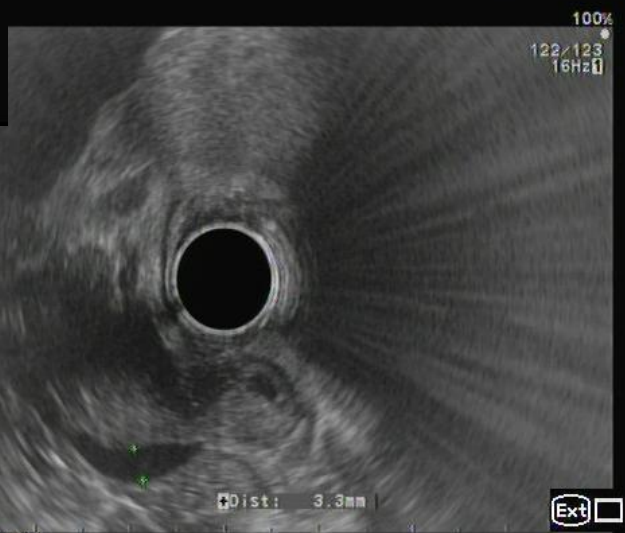
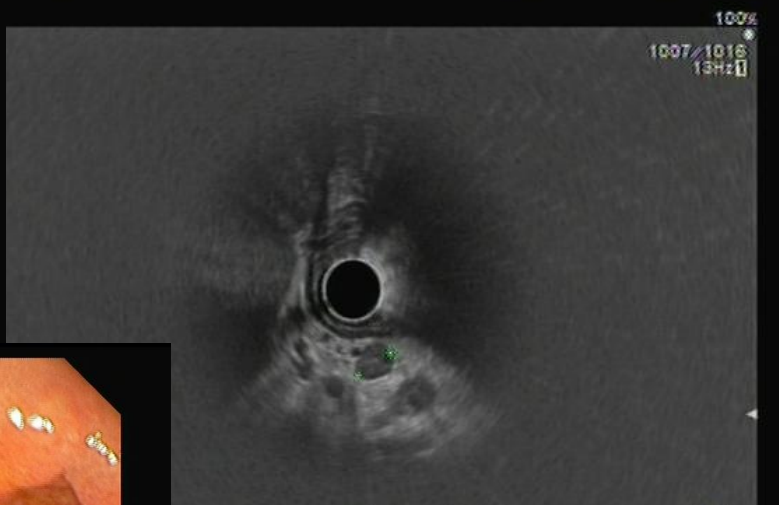






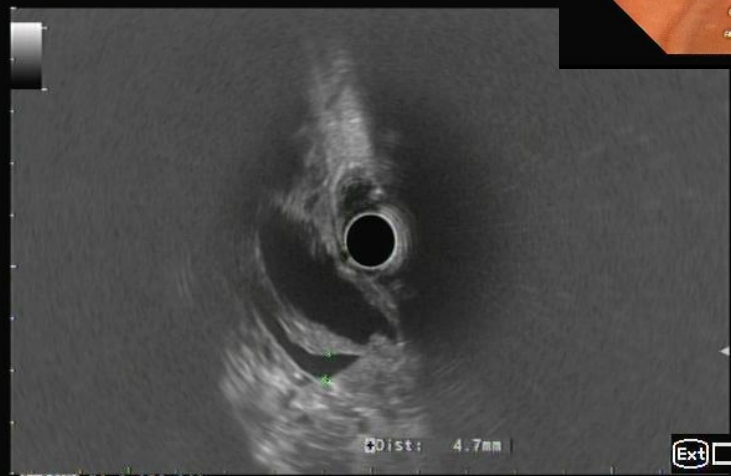

8.00MHz R5.0 G73 C10



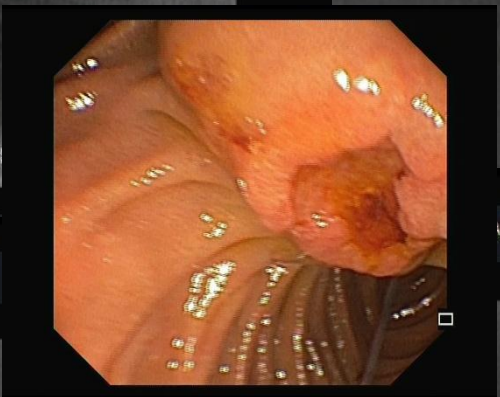8.00MHz R5.0 G73 C10

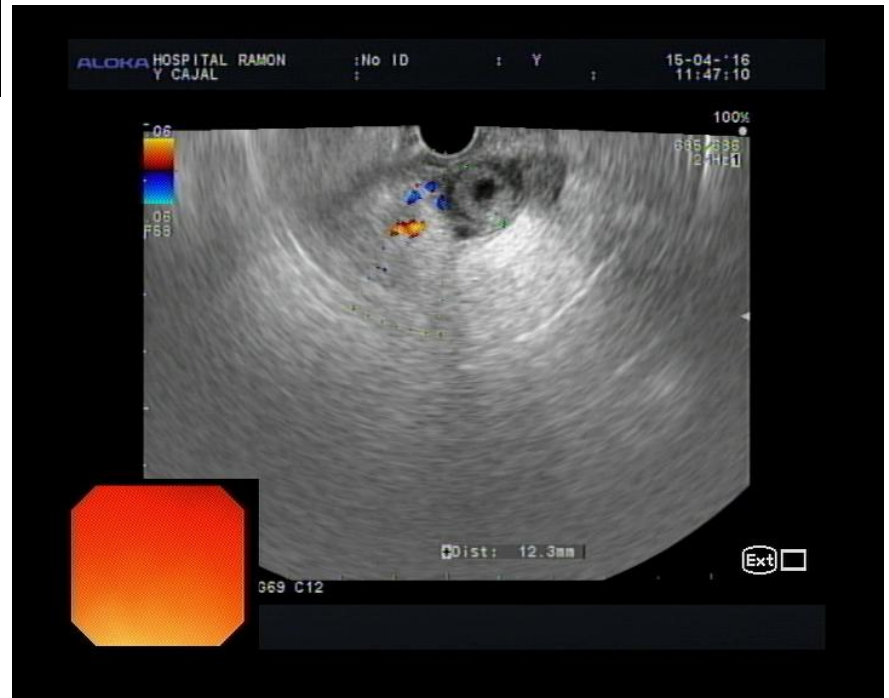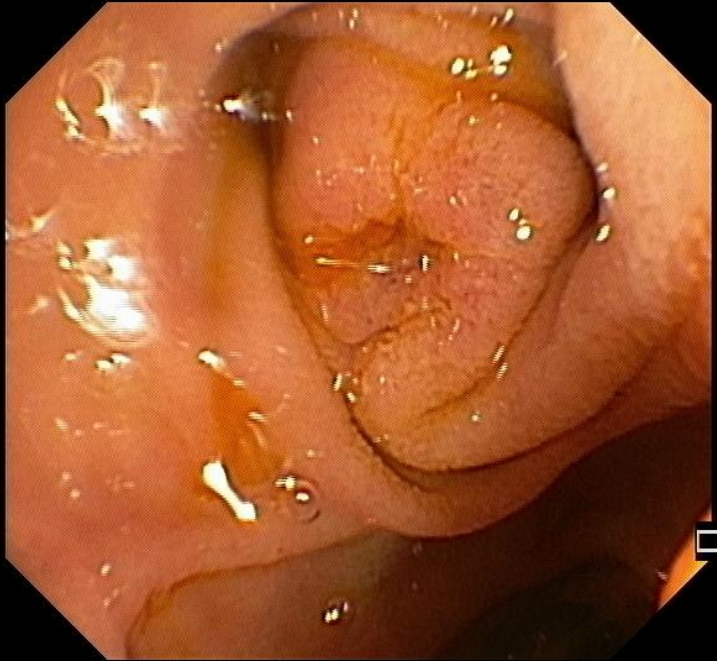Marque el punto final.

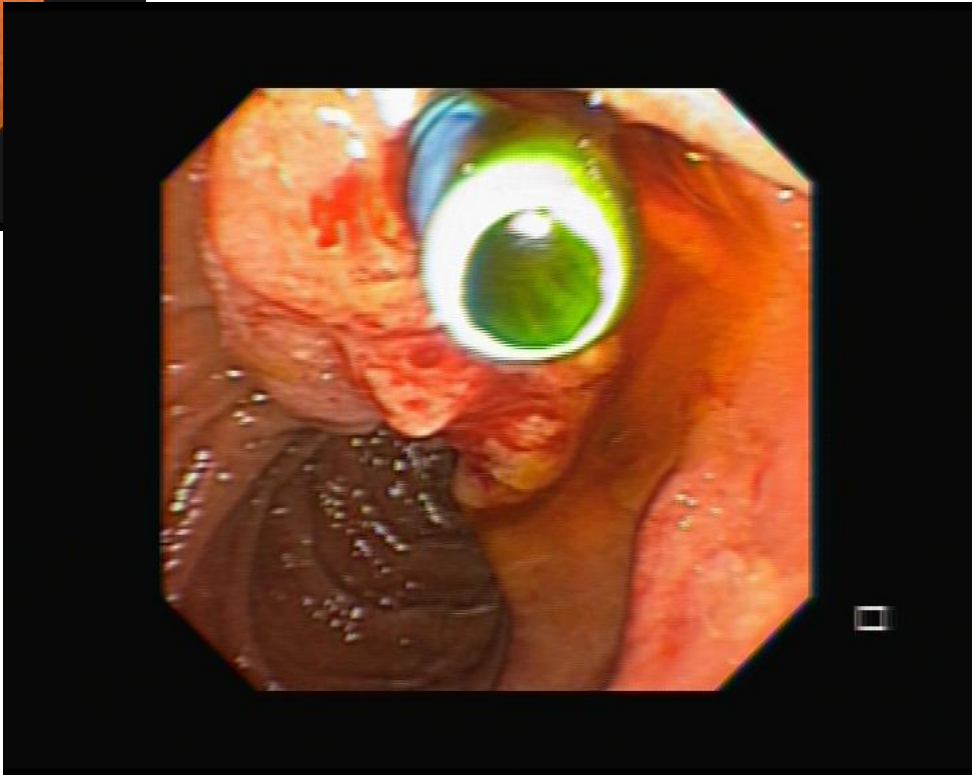
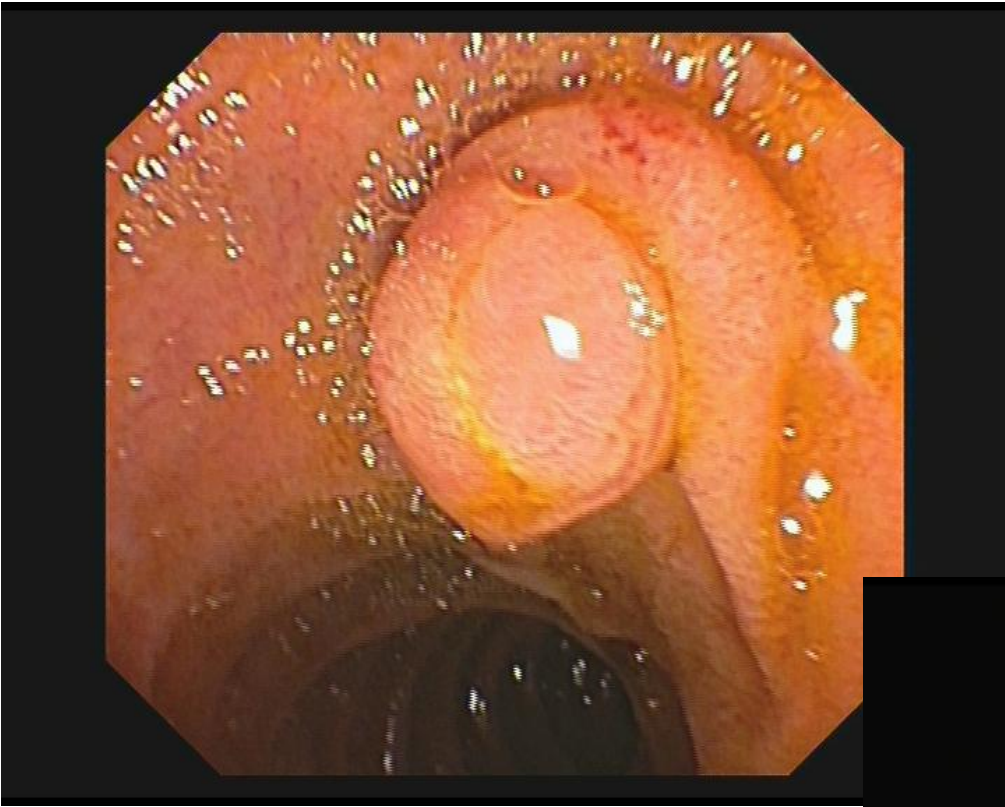


8.00MHz R9.0 G73 C10

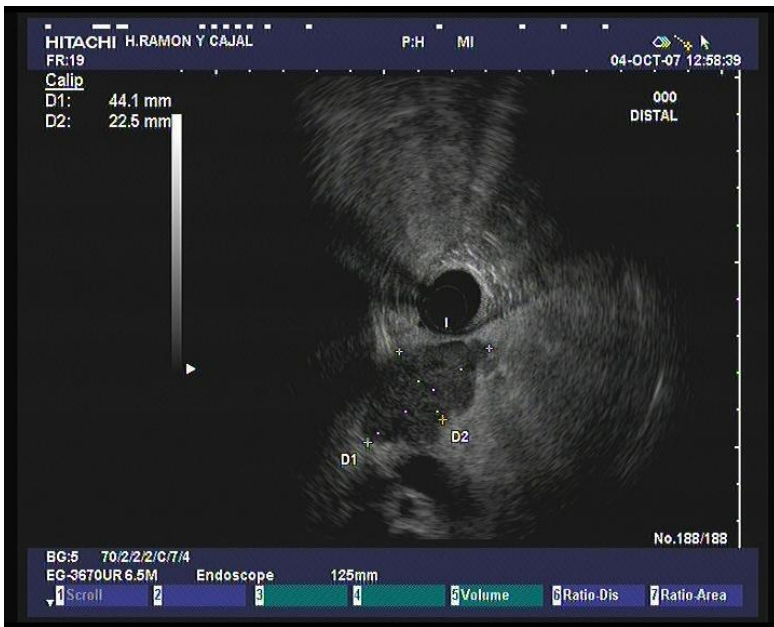Marque el punto final.



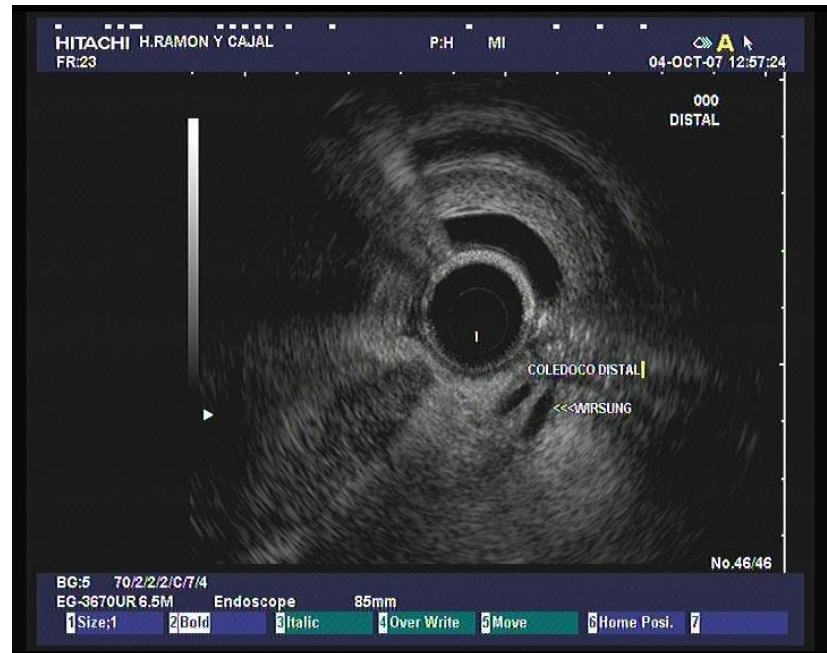



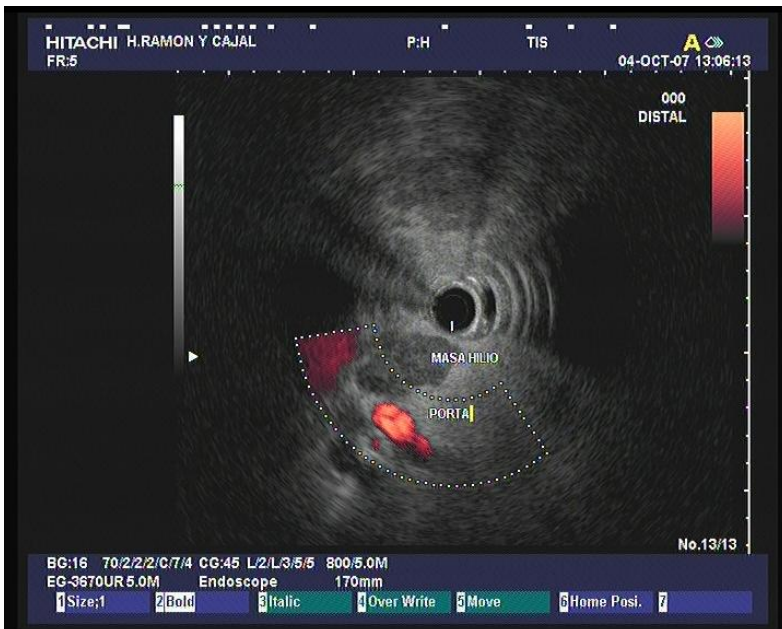COLANGIOCARCINOMAS

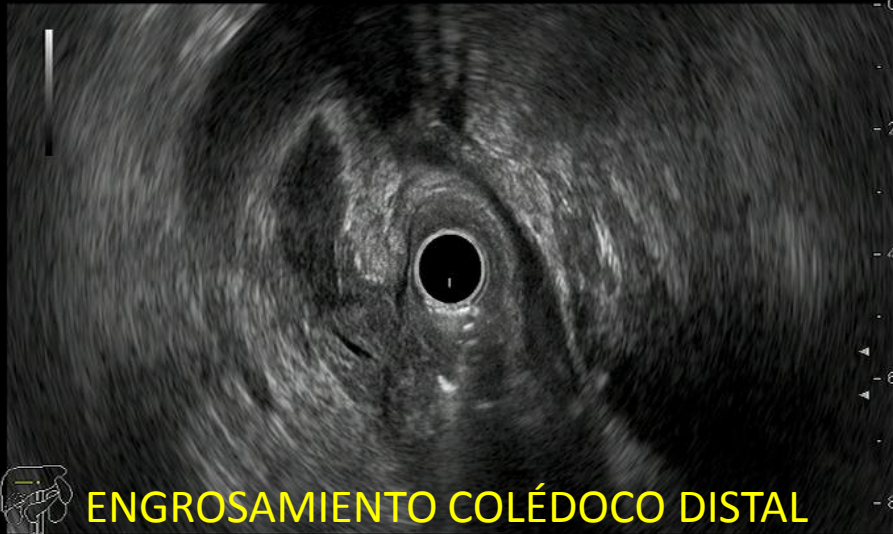

MASA EN HILIO

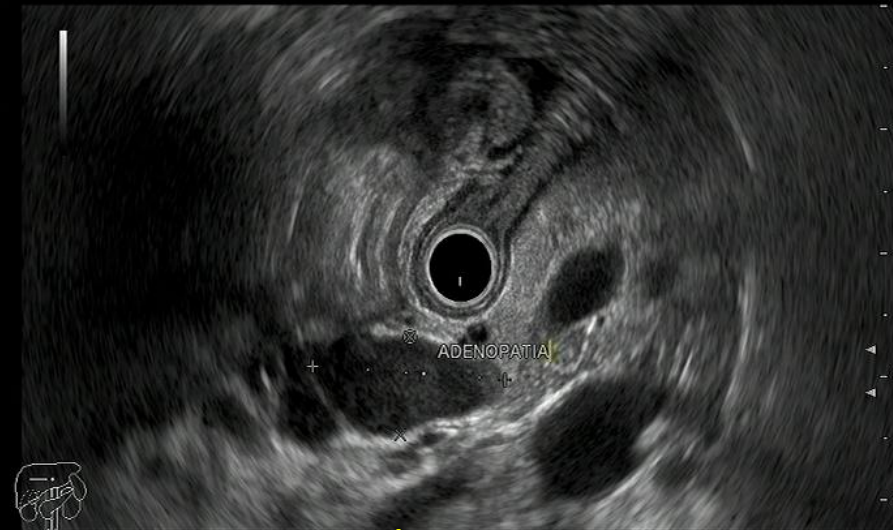

COLÉDOCO DISTAL Y WIRSUNG NORMALES





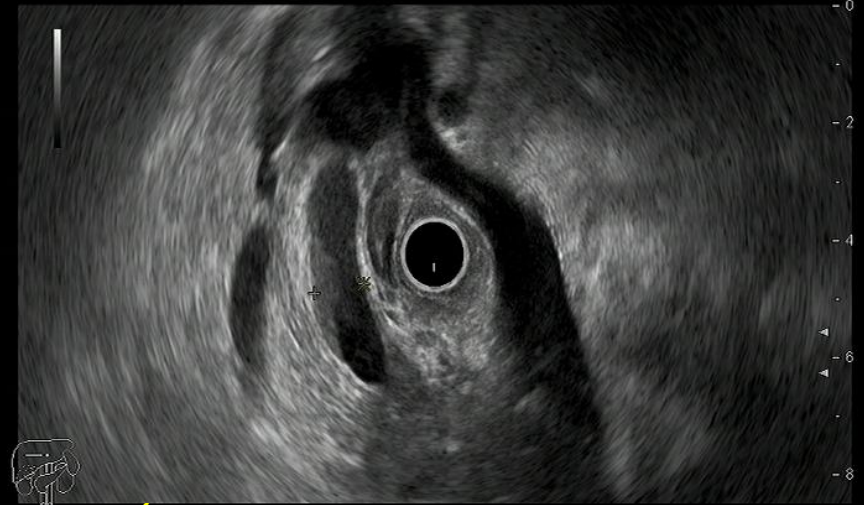ENGROSAMIENTO COLÉDOCO DISTAL



ADENOPATÍA

Calip + D1 34.4 mm × D2 15.9 mm
DISTAL EG-3670URK

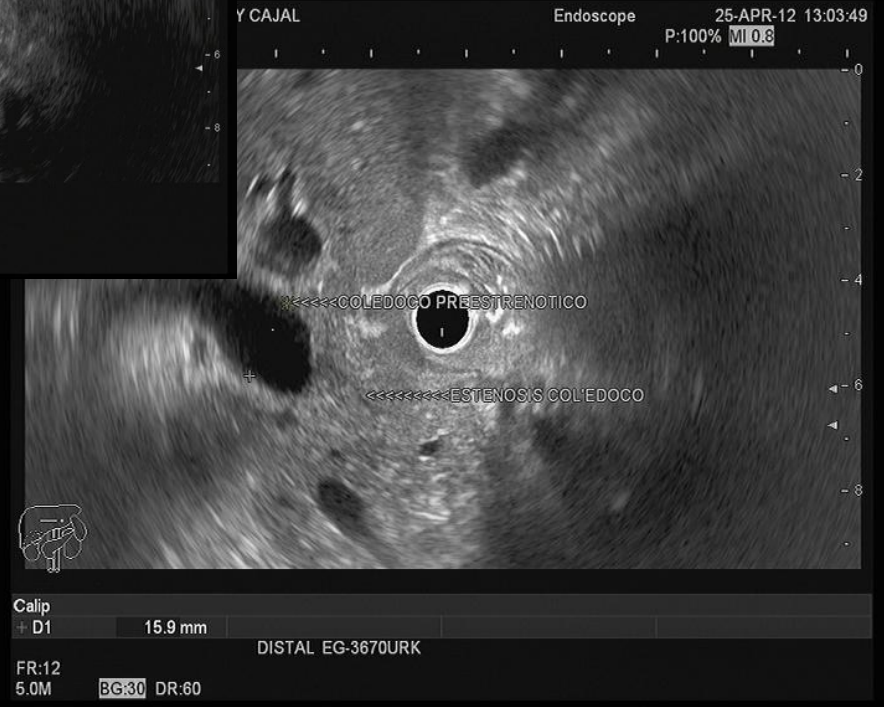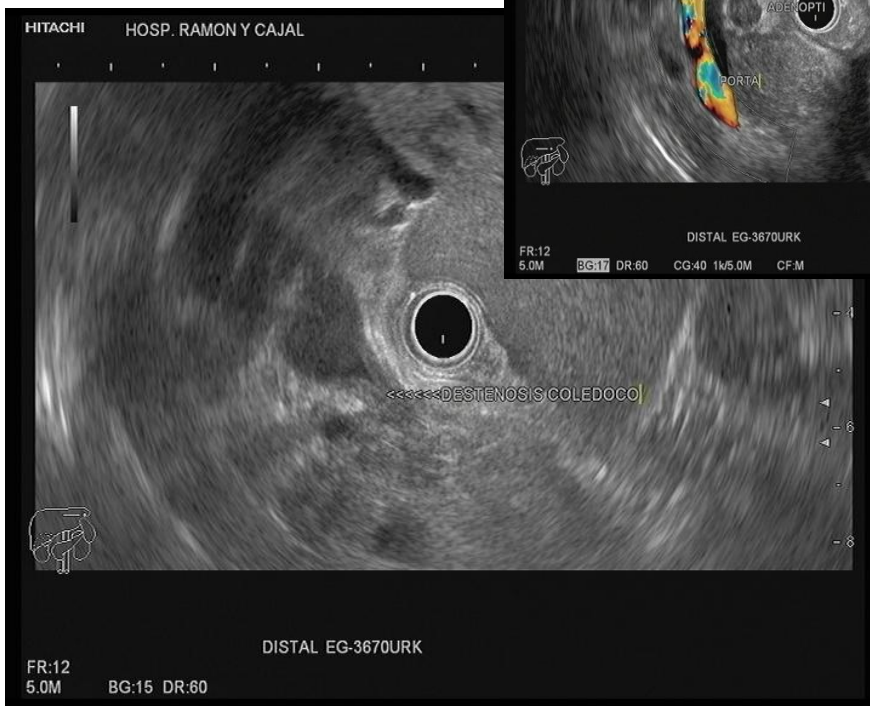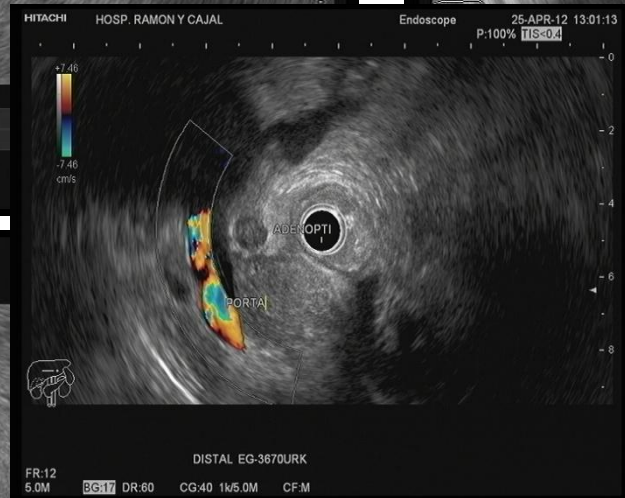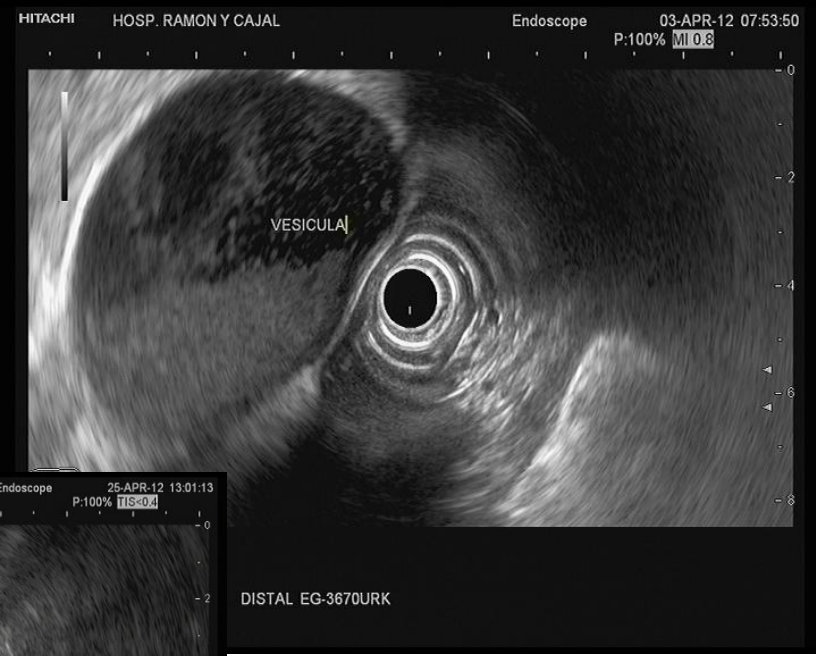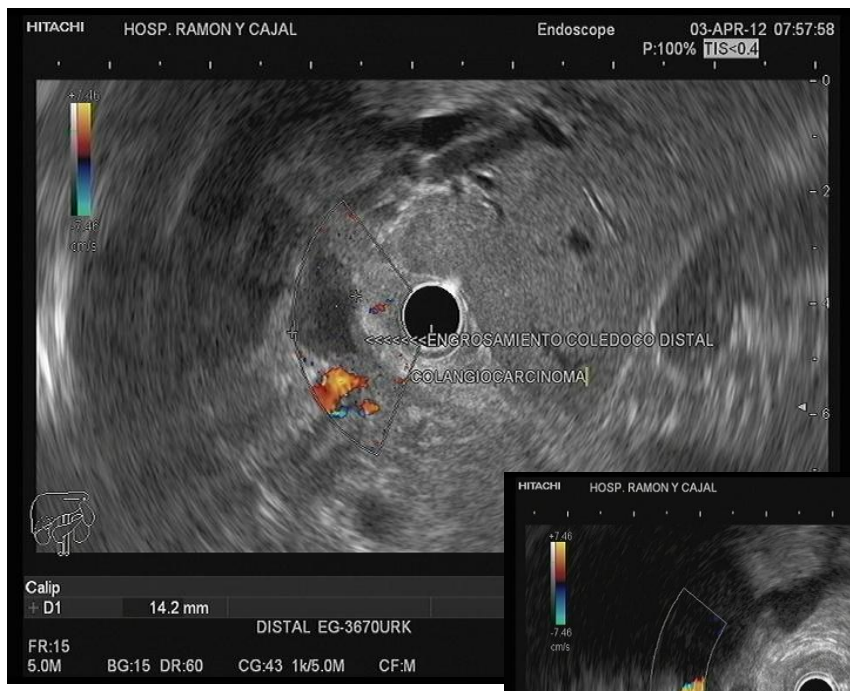
FR:12 5.0M BG:12 DR:60

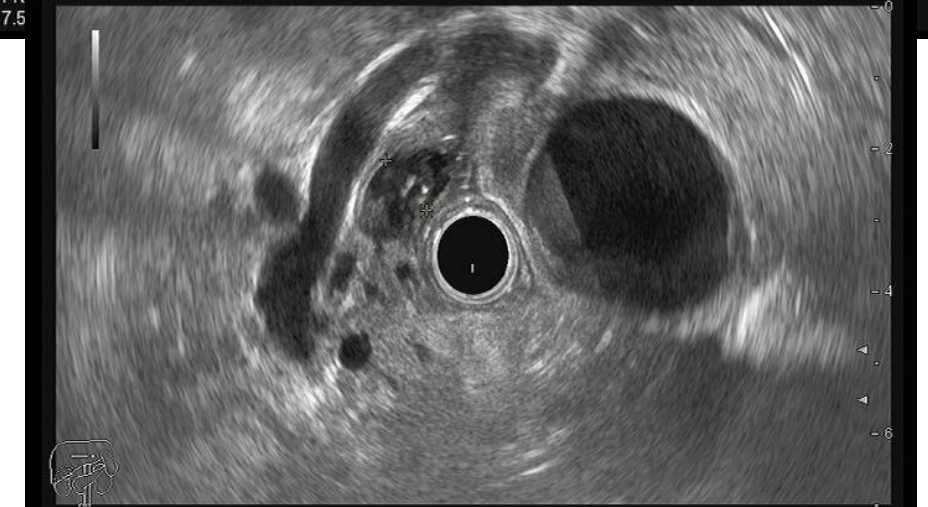
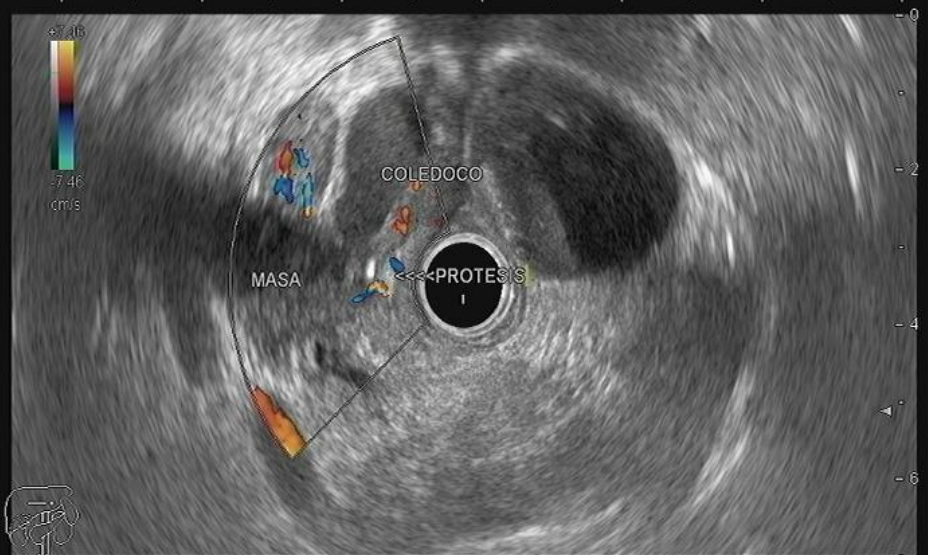
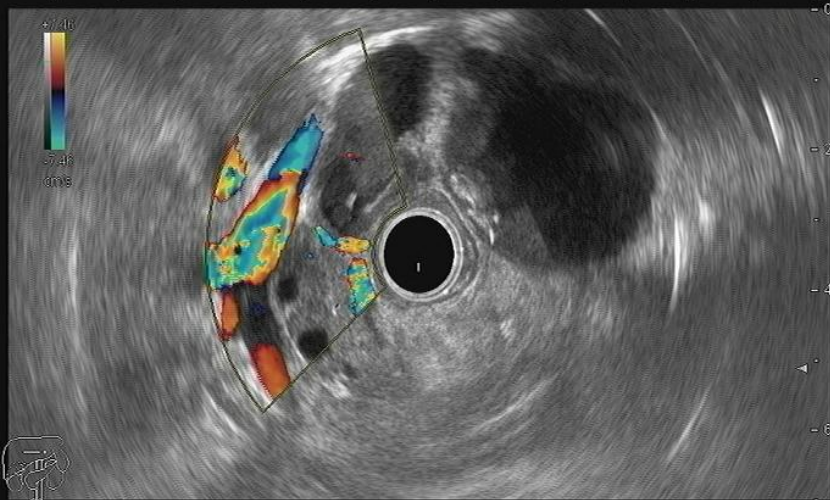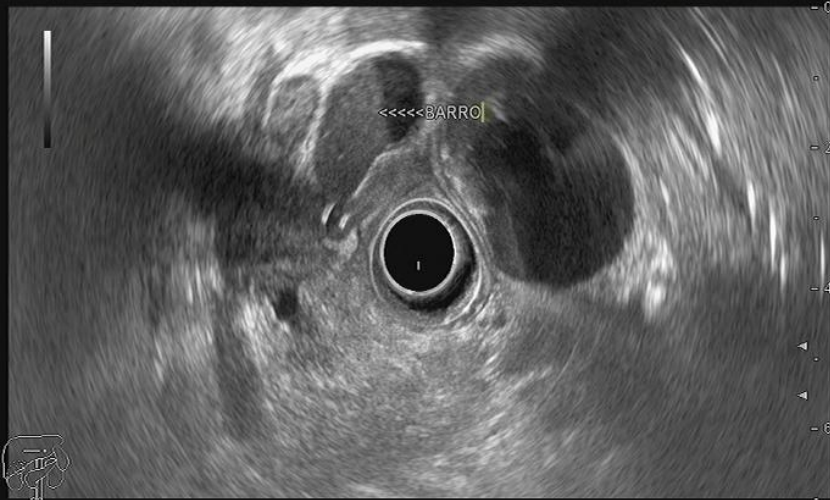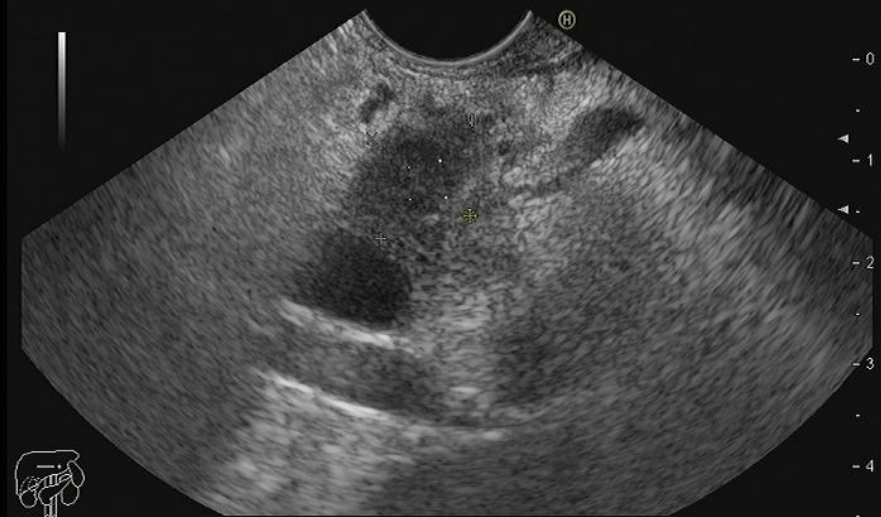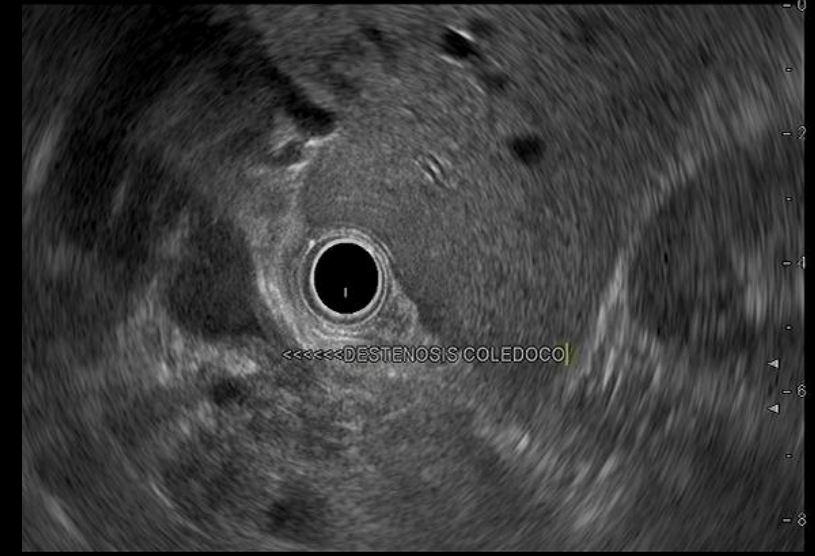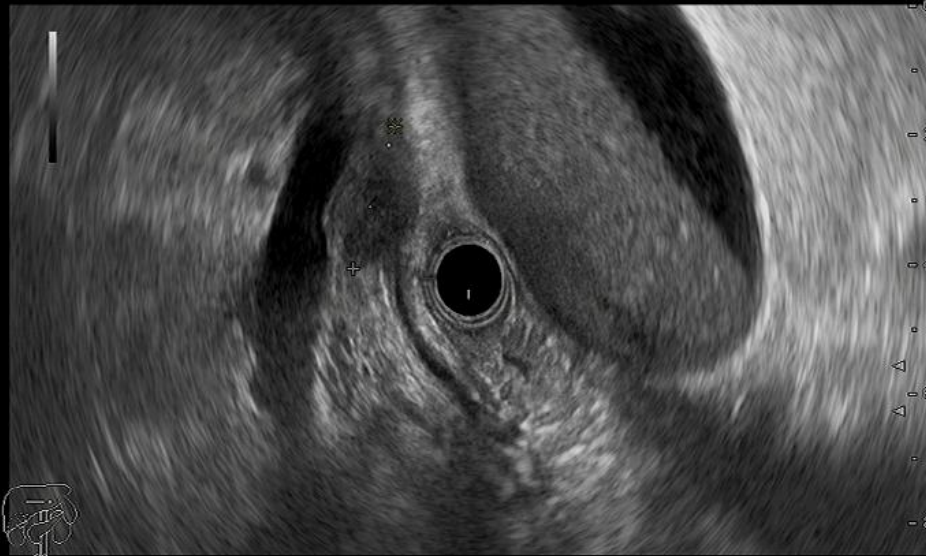COLÉDOCO DILATADO PROXIMAL

Calip + D1 9.5 mm
DISTAL EG-3670URK

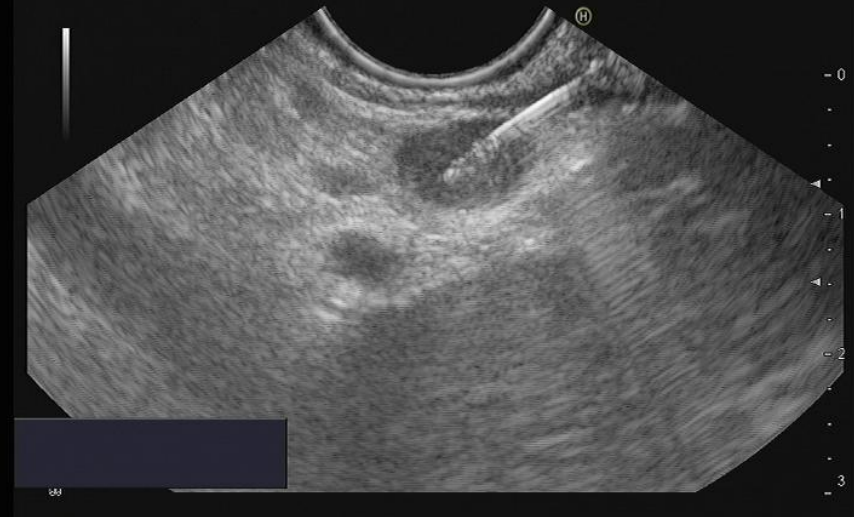FR:12 5.0M BG:12 DR:60





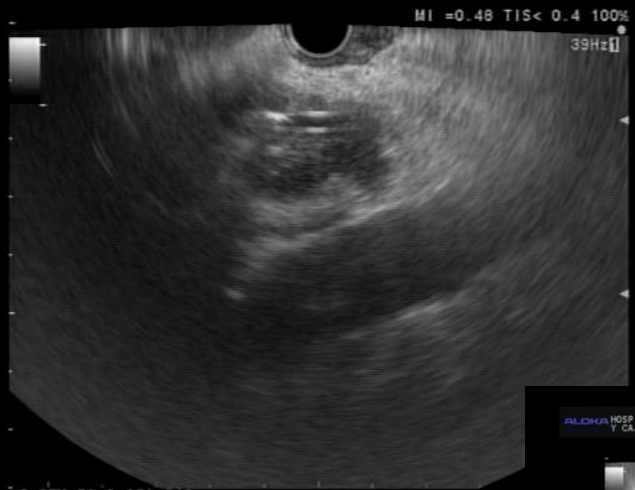

Calip
 + D1 15.3 mm × D2 13.1 mm
 EG-3870UTK
 FR:23 7.5M BG:17 DR:60



FR:23 7.5M BG:17 DR:60
 EG-3870UTK

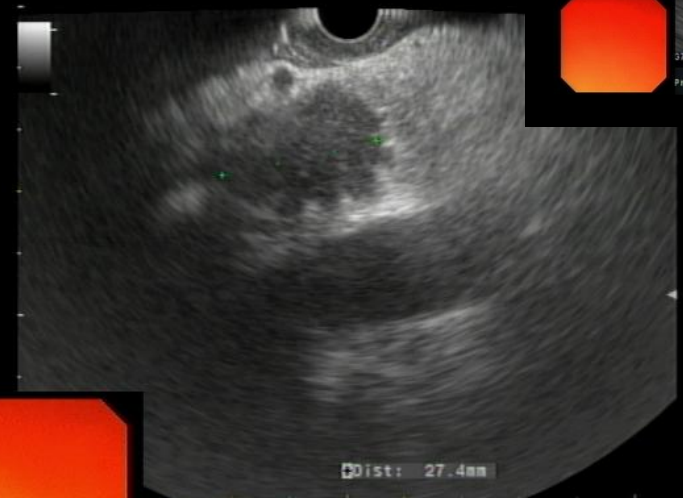ALOKA HOSPITAL RAMON :No ID : Y : 06-05-'15 12:49:10
Y CAJAL



6.67M R8.0 G69 C12

1:LINEAL OLY 180 Probe:OLY-RSC4

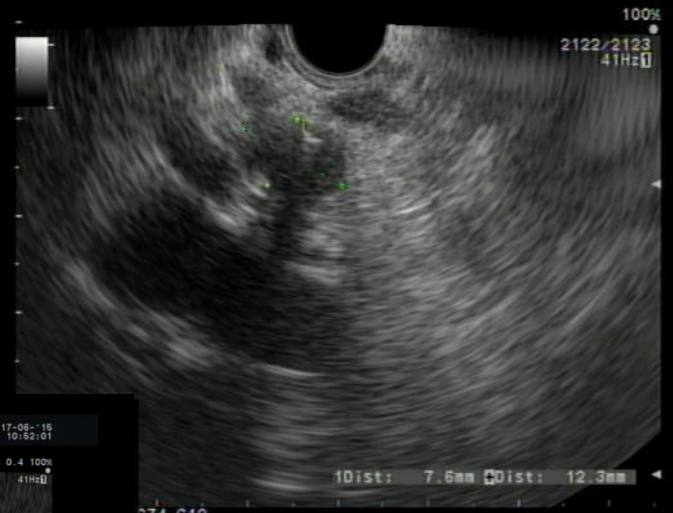ALOKA HOSPITAL RAMON :No ID : Y :
Y CAJAL



G69 C12

Ext

ALOKA HOSPITAL RAMON :No ID : Y : 17-06-'15 10:43:07
Y CAJAL

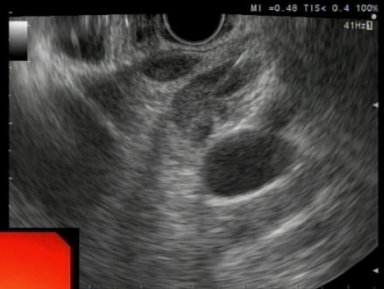

10Dist: 7.6mm 0Dist: 12.3mm

G74 C12

Ext

ALOKA HOSPITAL RAMON :No ID : Y : 17-06-'15 10:52:01
Y CAJAL

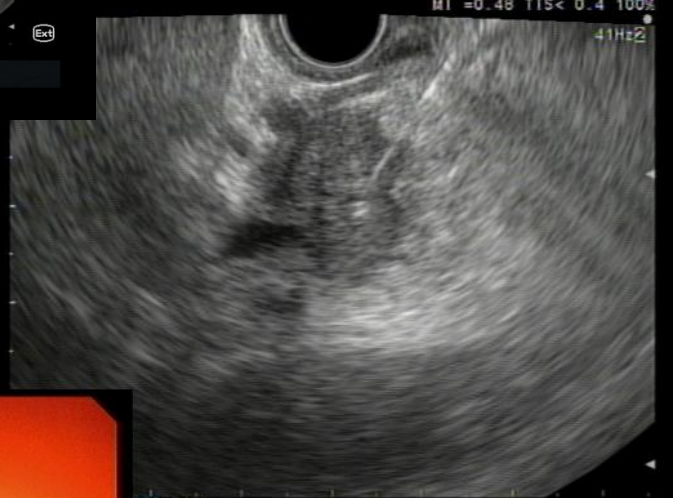

G74 C12

Probe:OLY-RSC4

Ext

HAMUN :NO ID : Y : 06-05-'15 12:58:42



G69 C12

Probe:OLY-RSC4

Ext